

Differential Expression of Claudin-1, Claudin-3, and Claudin-4 in Bladder Lesions

Tuba Dilay Kokenek-Unal^{1*}, Ipek Coban², Ayse Selcen Oguz-Erdogan³,
Hatice Seneldir⁴, Nesrin Gurcay⁵ and Murat Alper⁵

¹Department of Pathology, Kayseri Research and Training Hospital, Kayseri, Turkey.

²Department of Pathology, Gayrettepe Florence Nightingale Hospital, İstanbul, Turkey.

³Department of Pathology, Rize State Hospital, Rize, Turkey.

⁴Department of Pathology, Umraniye Research and Training Hospital, İstanbul, Turkey.

⁵Department of Pathology, Diskapi Yildirim Beyazit Research and Training Hospital, Ankara, Turkey.

Authors' contributions

This work was carried out in collaboration between all authors. Authors TDKU, IC and MA designed the study, wrote the protocol, and wrote the first draft of the manuscript. Authors NG and HS managed the literature searches and analyzed the study. Authors TDKU, IC and ASOE evaluated immunohistochemical staining. All authors read and approved the final manuscript.

Article Information

DOI: 10.9734/JCTI/2015/19336

Editor(s):

(1) Nicole Riddle, Department of Pathology, The University of Texas Health Science Center (UTHSCSA), USA.

Reviewers:

(1) Zhiqiang Qin, Department of Microbiology, Louisiana State University, USA.

(2) Maria Filomena Botelho, Department of Biophysics, University of Coimbra, Portugal.

Complete Peer review History: <http://sciencedomain.org/review-history/10573>

Original Research Article

Received 4th June 2015
Accepted 24th July 2015
Published 14th August 2015

ABSTRACT

Aims: Claudins are major transmembrane proteins of tight junctions. As the disruption of their function have important impact on tumorigenesis, invasion and metastasis. Claudins became a focus of interest for targeting therapies. Although their expression profiles have been studied in many organs, researches on Claudin expression in bladder are in limited number. The aim of this study is to present the differential expression of Claudin-1, Claudin-3 and Claudin-4 in invasive and noninvasive urothelial lesions.

Study of Design: Several groups of noninvasive and invasive urothelial lesions were stained immunohistochemically by Claudin-1, Claudin-3 and Claudin-4 and their expressions were evaluated.

Place and Duration of Study: Department of Pathology of Diskapi Research and Training Hospital, Ankara, between 2011-2013.

*Corresponding author: Email: tubadilay@gmail.com;

Methodology: 83 cases (31 invasive urothelial carcinomas (IUC) –further divided into: 15 muscle invasive UCs, 16 UCs with lamina propria invasion-, 17 noninvasive papillary urothelial carcinomas (NPUC), 13 papillary urothelial neoplasms of low malignant potential (PUNLMP), 7 carcinoma in situ (CIS) and 15 normal independent samples (CG). Sections from formalin-fixed paraffin embedded tissues were immunohistochemically stained with Claudin 1, Claudin 3 and Claudin 4.

Results: Claudin-1 expression is significantly lower in low grade noninvasive urothelial carcinomas compared to invasive carcinomas. Claudin-3 is highly expressed in normal urothelium and invasive lesions; but its expression is decreased significantly in all non-invasive lesions. Claudin-4 expression appeared to decrease in muscle invasive UC and CIS vs. others.

Conclusion: Although higher expression of Claudin-4 in low-grade and non-invasive lesions may be used as a diagnostic tool, decreased expression of Claudin-4 can indicate more invasive capacity of the tumour. In terms of Claudin-1 and -3, their decreased expression in non-invasive lesions when compared to control group and their trend to show more increased expression in IUC needs to be studied further in larger studies.

Keywords: Bladder cancer; claudin-1; claudin-3; claudin-4; urothelial carcinoma.

1. INTRODUCTION

Bladder cancer, accounting for 4.1% of all tumors [1], is one of the most common tumors worldwide. According to recent researches, the new cases of bladder cancer are expected to account for 6% of all cancers [2]. Males are affected more than females at a ratio of 3 to 4:1. Exposure to chemicals such as aromatic amines, dyes, smoking, drugs, infections are included in predisposing factors [3].

Approximately 90% of primary malignant tumors of bladder are urothelial carcinomas. Although 70-80% of patients are diagnosed at early invasive or noninvasive stages and have a good prognosis [3], urothelial carcinoma in these stages has a clinical importance because of high recurrence rates after transurethral resection [4]. On the other hand, high grade and invasive tumors have high mortality rates and their treatment and prognosis are very different from noninvasive tumors [4]. Mainly, histological morphology is crucial both in differential diagnosis of noninvasive papillary urothelial neoplasms and also in recognition of the presence and extent of invasion in malignant lesions. Therefore sampling errors and orientation problems may lead to difficulties in interpretation of specimen and correct diagnosis might be highly challenging. Tumor progression is primarily based on histological grade and tumor stage, but there are several prognostic features including morphologic, molecular and clinical characteristics [5] In addition to that, other new possible markers are being investigated to predict tumor progression [6].

Tight junctions, to which also claudins belong, act as a regulator barrier in paracellular ion and protein transport in epithelium [7]. They are dynamic elements which can change their structure and composition according to environmental factors [8]. Recent studies indicated that tight junctions have a critical role in tumor initiation, dedifferentiation, invasion, progression and metastasis. As an important transmembrane protein, claudins form the backbone of tight junctions. They have an essential role in paracellular permeability [9]. The claudin family has 24 members which share a wide range of similar sequences. Different claudin subtypes are expressed from most cell types. Because of their critical functions in cells, since their discovery, studies investigating their roles in tumorigenesis are expanding. Their expressions seem to change in a tissue specific manner [10].

In course of time, better understanding of underlying pathogenetic mechanisms of tumors leads to identification of certain surface molecules that can be used as a therapeutic target for novel drugs produced from genetically modified bacteria or bacterial toxins in some malignancies [11]. *Clostridium perfringens* enterotoxin is one of most used toxin for this purpose. Claudins take a major role in this promising new treatment strategy because they have identical receptor with *Clostridium perfringens* enterotoxin (CPE). The usage of these receptors is topic of most recent studies in cancer treatment [12,13].

Up to today, since claudins have these several specific features, their expressions in different

malignancies are investigated. Despite the fact that bladder cancer is one of the most common cancers, studies dealing with expressions of claudins in urothelial lesions and its relationship with stage and grade of disease in invasive cases are in limited number.

2. MATERIALS AND METHODS

With approval by the local ethics committee, a total of 83 transurethral resection and cystectomy materials, which were diagnosed in our institute, were analyzed. Our study comprises 31 invasive urothelial carcinomas (IUC) –further divided into: 15 muscle invasive UCs, 16 UCs with lamina propria invasion-, 17 noninvasive papillary urothelial carcinomas (NPUC), 13 papillary urothelial neoplasms of low malignant potential (PUNLMP), 7 carcinoma in situ (CIS) and 15 normal independent samples (CG). The mean age of the patients was 62.9 (20-89 years), and male/female ratio was 7.3/1. Hematoxylen & eosin stained sections were histopathologically evaluated according to the tumor classification of WHO (2004) [5].

2.1 Immunohistochemical Analysis

Sections from formalin-fixed paraffin embedded tissues were immunohistochemically stained with Claudin 1, Claudin 3 and Claudin 4. Staining procedures were carried out in BenchMark XT automatic immunostainer using multimer technology and diaminobenzidine as chromogen according to manufacturer's protocol. (Ventana Medical Systems). Immunohistochemically stained samples were evaluated by light microscope with $\times 4$, $\times 10$, $\times 40$ objectives. Only membranous staining was accepted as positive for Claudin-1 and Claudin-4, but for Claudin-3 both cytoplasmic and membranous staining was evaluated as positive. Parenchyma didn't show any staining. As positive controls, skin, small intestine and colon carcinoma were used respectively for Claudin-1, Claudin-3 and Claudin-4. For the analysis of immunoreactivity, semiquantitative methods were used. Staining intensity was evaluated as: 0 = absent; 1 = mild; 2 = moderate; 3 = high; and the percentage of positive staining cells was evaluated as 0 = 0-5%; 1 = 6-25%; 2 = 26-50%; 3 = 51-100%. The final score was calculated by multiplying the intensity and percentage of positive staining scores. According to final score it is evaluated as followings: 0 = negative; 1-2 = weak; 3-4 = moderate and 6-9 = strong. Staining results were evaluated statistically.

2.2 Statistical Analysis

Statistical analysis was performed by using SPSS for Windows Version 15.0 software package. Quantitative variables, mean \pm standard deviation, median and minimum-maximum values and categorical variables were summarized by number and percentage. Differences between the groups in terms of staining scores were assessed by the Kruskal-Wallis test. Pairwise comparisons were analyzed by Conover test. The relationship between advancing pathologic stage and staining scores was evaluated by Spearman's rank correlation coefficient. The differences between degree of nuclear grade and staining scores were analyzed by Mann Whitney U test. The correlation between staining scores and diagnosis of nuclear grade was evaluated in terms of correct classification rate, sensitivity and specificity values. p values <0.05 were considered significant.

3. RESULTS AND DISCUSSION

3.1 Claudin-1

In normal urothelial cells, Claudin-1 showed strong and diffuse membranous staining especially in basal cells (Fig. 1). All CIS cases were stained weakly (Fig. 2). In contrast, most of the cases of PUC with muscular invasion (80%) showed strong staining (Fig. 3). Final staining scores of Claudin-1 are as in Fig. 4.

In comparison to control group, we found a statistically significant difference in Claudin-1 expressions of all groups, except PUC cases with muscular invasion. Comparatively, there was a significant difference in staining of Claudin-1 in between NPUCs and PUNLMPs; NPUCs and PUCs with lamina propria invasion; PUCs with lamina propria invasion and PUCs with muscular invasion. The statistical results of Claudin-1 expressions in these groups were shown in Table 1.

3.2 Claudin 3

Claudin-3 showed both membranous and cytoplasmic staining in epithelial cells. Normal urothelial epithelium of the most cases was stained strongly (80%, 12/15). Although most of the CIS cases showed weak staining (58%), Claudin-3 staining was stronger in invasive papillary urothelial lesions than noninvasive lesions in our study (Fig. 5).

When we compared staining of Claudin-3 of study groups with each other, we found a statistically significant difference between controls and CISs; controls and NPUCs; CISs and PUCs with muscular invasion; PUNLMPs and PUCs with lamina propria invasion; PUCs with muscular invasion; NPUCs and invasive PUCs; PUCs with lamina propria invasion and PUCs with muscular invasion. Staining scores were given in Fig. 6.

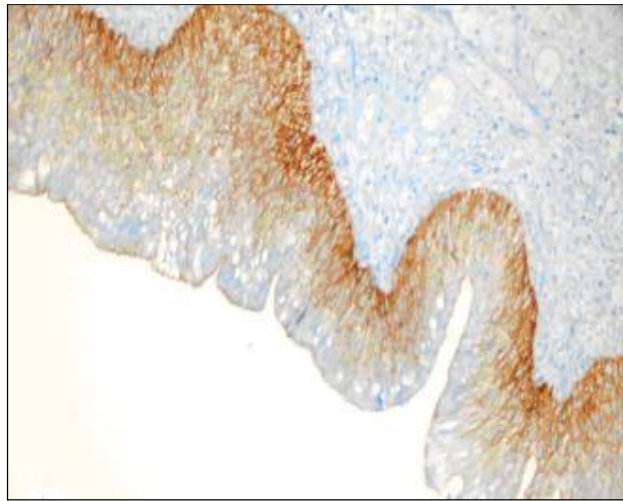


Fig. 1. Diffuse and strong Claudin-1 staining in normal bladder epithelium. (×20)

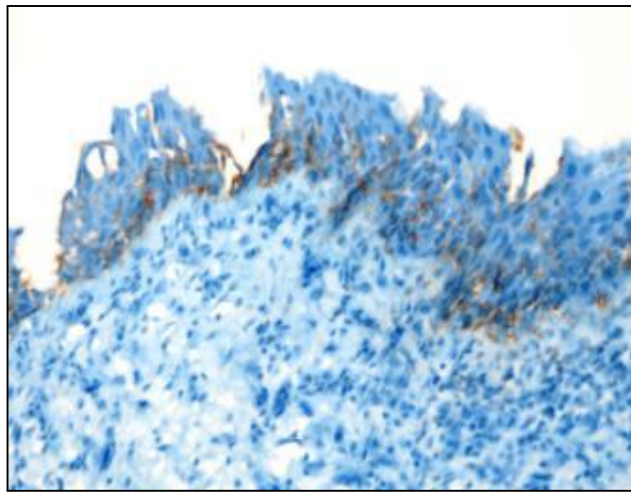


Fig. 2. Weak Claudin-1 staining in carcinoma in situ lesion. (×40)

Table 1. The sensitivity and specificity of Claudin 1 in histologically similar lesions

Compared groups	Sensitivity	Spesifty	Positive predictive value	p value
CISs and PUCs with muscular invasion	80%	100%	86,4%	0,001
PUNLMPs and NPUCs	5.9%	53.8%	26.7%	0.025
NPUCs and PUCs with lamina propria invasion	43.8%	94.1%	70%	0.017




Fig. 3. Strong and diffuse staining of Claudin-1 in papillary urothelial carcinoma with muscular invasion. (×20)

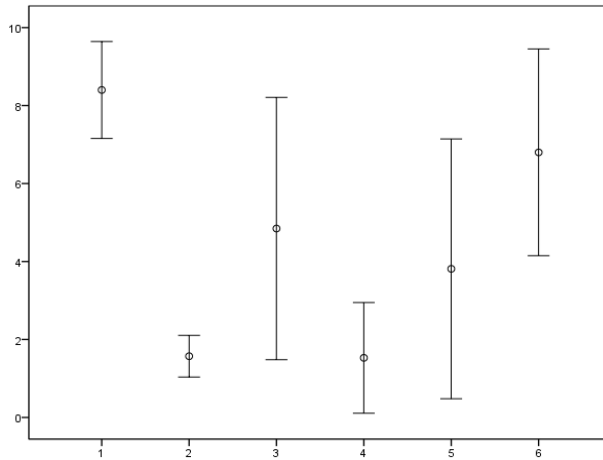


Fig. 4. Staining scores of Claudin-1. 1: CG; 2: CIS; 3: PUNLMP; 4: NPUC; 5: PUC, LP; PUC, MP

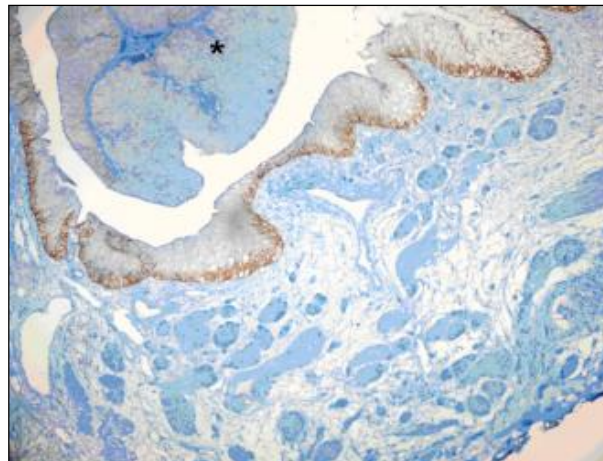


Fig. 5. Strong staining in normal epithelium and loss of expression (*) of claudin-3 in adjacent to noninvasive papillary urothelial carcinoma component. (×20)

3.3 Claudin 4

Normal urothelium expressed diffuse and strong membranous staining with Claudin-4. It is observed a 'dot-like' staining in tumoral cells in CIS cases (Fig. 7). We observed strong staining only in 3/7 cases of CIS group. In PUNLMPs, NPUCs and PUCs with lamina propria invasion, majority of cases showed strong staining, 77%, 82%, and 62.5% respectively (Fig. 8). In PUCs with muscular invasion, most of the cases (60%) showed loss of expression (Fig. 9). All staining scores of Claudin-4 were given in Fig. 10.

When we compared Claudin-4 expressions in different study groups, we found a statistically significant difference between controls and CISs; controls and PUCs with muscular invasion; PUNLMPs and PUCs with muscular invasion; and NPUCs and PUCs with muscular invasion. It is observed that Claudin-4 expression decreases with increasing histological grade and pathological stage. (Correlation coefficient $p < 0,001$). It is found that positive predictive value of Claudin-4 for high nuclear grade was statistically significant ($p < 0,001$).

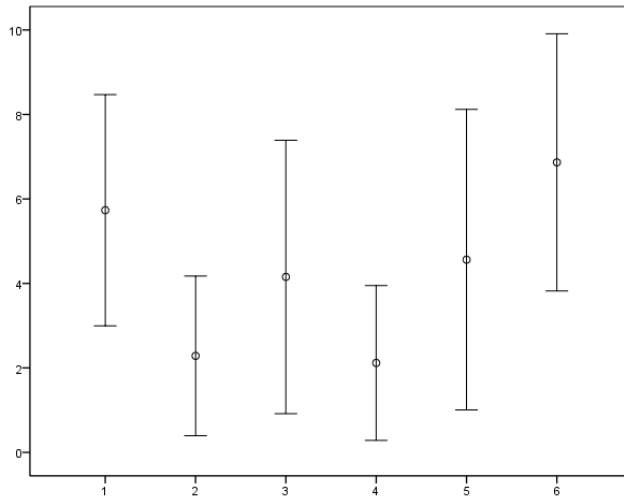


Fig. 6. Staining scores of Claudin-3. 1: CG; 2: CIS; 3: PUNLMP; 4: NPUC; 5: PUC, LP; PUC, MP

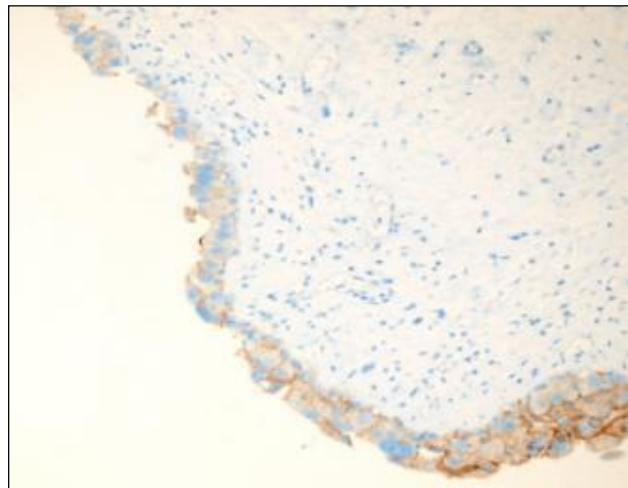


Fig. 7. 'Dot-like' staining with Claudin-4 in carcinoma in situ lesion. ($\times 40$)

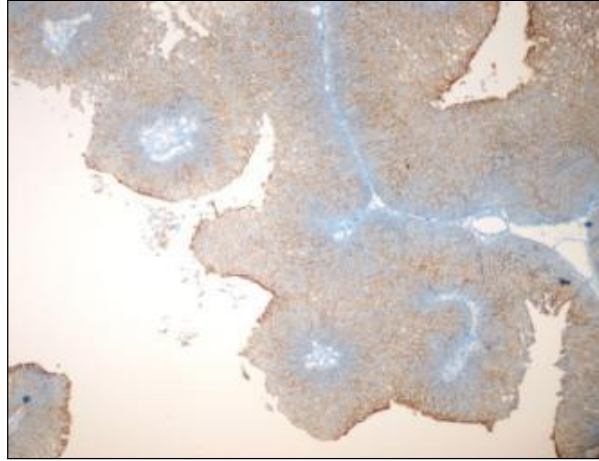


Fig. 8. Strong staining with Claudin-4 in noninvasive papillary urothelial carcinoma. (×20)

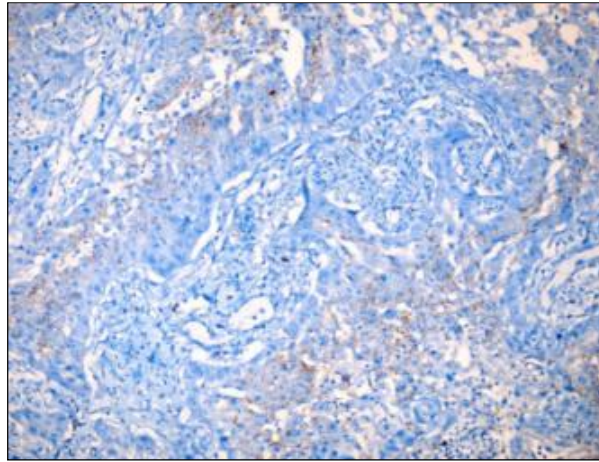


Fig. 9. Loss of expression of Claudin-4 in muscular invasive papillary urothelial carcinoma. (×40)

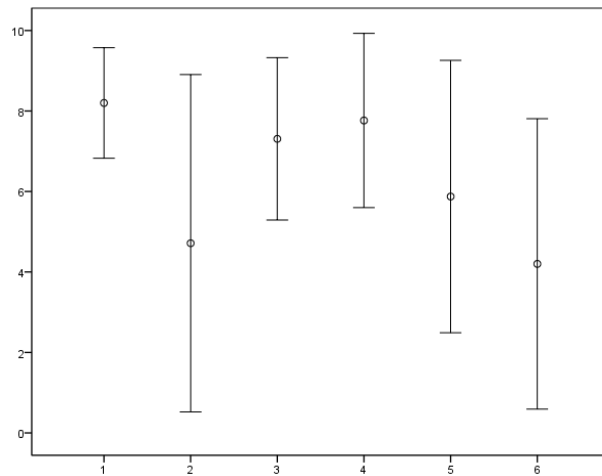


Fig. 10. Staining scores of Claudin-4. 1: CG; 2: CIS; 3: PUNLMP; 4: NPUC; 5: PUC, LP; PUC, MP

There weren't any significant association between Claudin-1,-3 and -4 expressions and sex and age (over or under 70 years).

3.4 Discussion

Claudins, which are important elements of cellular barrier, are relevant not only to benign diseases such as neonatal ichthyosis and sclerosing cholangitis syndrome [14] but also malignant diseases in terms of tumorigenesis, invasion and metastasis [9]. It is indicated that Claudin-1 is usually overexpressed in neoplastic tissue but in poorly differentiated tumors there is a loss of expression of Claudin-1 [15]. It is overexpressed in cervical dysplasia and neoplasia [16], advanced stage oral squamous cell carcinomas [17], papillary thyroid carcinoma with lymph node invasion [18], colorectal cancer [19]. In contrast, it undergoes loss of expression in prostatic cancer [20] and breast tumors [21]. Especially in breast tumors, claudin-1 is thought to have an important and more complicated role than formerly suggested [21]. There are only few studies regarding Claudin-1 expression in urothelial carcinoma. It was reported that Claudin-1 is found mainly basal and intermediate layers of urothelium and with Claudin-3 and -4 show positive correlations with advanced stage and have a significant impact on survival [22]. In a different study, it was stated that Claudin-1 has lower expression comparatively in low grade urothelial carcinomas than urothelial papilloma, inverted urothelial papilloma and PUNLMPs [23]. Similarly, in our study we found that Claudin-1 expression in NPUCs was lower than in PUNLMPs and the difference was statistically significant. As former studies said, Claudin-1 staining in basal and intermediate layers is helpful to orient specimen and tumor islands and to differentiate neoplasia from epithelial hyperplasia [22,23]. A similar study reported that Claudin-1 has loss of expression in high grade tumors in comparison to low grade tumors [24]. However, our study showed that Claudin-1 had significantly lower expression in low grade NPUCs compared to high grade and invasive PUCs. In addition to that difference between Claudin-1 expressions in PUNLMPs and NPUCs; and PUCs with lamina propria invasion and PUCs with muscular invasion was statistically significant. For that reason, we thought that Claudin-1 staining can be helpful in differentiation of these lesions. However, because of diverse results of Claudin-1 staining results in several studies, it should be investigated in larger series.

Claudin-3 and -4 including many phylogenetically similar sequences with each other are found mainly in intestine, liver, kidney, lung, colon, prostate, breast and testicular tissue [10,25]. These proteins are overexpressed in pancreatic ductal carcinoma, prostate, uterus, breast and ovarian cancers [26-29]; but their expressions diminish in hepatocellular and renal carcinomas [30,31]. There are a few studies concerning Claudin-3 and Claudin-4 immunoexpressions in bladder carcinomas. Claudin-3 is mainly found on apicolateral and basolateral surface of superficial urothelial cells; and Claudin-4 is found in not only plasma membrane of cells in superficial and intermediate layers but also in cells of basal layers [22,32,33]. Soini et al. [15] published a study concerning expressions of Claudins in different organ tumors. In this study they indicated that Claudin-3 staining was negative in 4 of total 8 urothelial carcinoma cases. Nakashi et al. [22] reported that overexpression of Claudin-3 and Claudin-4 was correlated to advanced stage in urothelial carcinomas of upper urinary tract and Claudin-3 was related to poor survival. In contrast to that, Wang et al. indicated that Claudin-3 staining in urothelial carcinoma of bladder was lower than normal tissue; and diminished expressions of Claudin-3 was correlated with clinical stage, pathological grade and recurrence [34]. We thought that this difference could be originated from different features of urothelium of upper urinary tract and bladder. Szekely et al. [23] didn't evaluate Claudin-3 staining because of weak or no marked staining in any of the groups. However, in our study, we found that Claudin-3 had such an expression in invasive and high grade urothelial carcinomas similar to the normal tissue; and loss of expression of Claudin-3 in noninvasive and low grade lesions was statistically significant. In the light of all these data, we can say that it is needed to be performed more detailed and comprehensive studies.

Claudin-4 is generally overexpressed in most carcinomas [15]. However when we look at limited studies which are concerning Claudin-4 expressions in urothelial carcinomas, we encounter different and discordant results. Southgate et al. reported that Claudin-4 increased distinctively in response to variable situation [32]. Boireau et al. [35] indicated that Claudin-4 was overexpressed superficial and low grade tumors; and its expression decreased in invasive and high grade tumors compared to the normal mucosa. In this study, it is said that

Claudin-4 staining was closely related to tumor stage and grade, but it didn't correlate to tumor recurrence and metastasis [35]. In contrast, Nakanishi et al. [22] reported that increased expression of Claudin-4, together with Claudin-3, was correlated to advanced stage. Szekely et al. [23] argued that increased Claudin-4 expression in low grade urothelial carcinomas was correlated to poor prognosis and short survival without recurrence and for that reason Claudin-4 can be used to estimate clinical prognosis of urothelial carcinomas. In addition to that, Törzsök et al. [24] reported that Claudin-4 expression was higher in high grade tumors than in low grade tumors. Szekely and Törzsök criticized Boierau et al., who reported quite opposite results to their study, for evaluating urothelial tumors without subclassification and using normal urothelium adjacent to the neoplastic epithelium as a control group [22,23,34]. They also reminded the study of Jones et al. concerning urothelial carcinogenesis which reported that nontumoral epithelium adjacent to tumor might have been already genetically changed [23,24]. In fact, we used an independent control group and also subclassified all lesions; and we found that Claudin-4 expression decreased in high grade lesions; carcinoma in situ and muscular invasive urothelial carcinomas like Boierau et al. [35]. In contrast to Claudin-4 overexpression in PUNLMPs and noninvasive papillary urothelial carcinomas, we found statistically significant loss of expression in invasive and high grade carcinomas. In addition to that, Claudin-4 was inversely correlated to histological grade and pathological stage in statistical analysis. We obtained marked and strong staining not only in independent nonneoplastic samples but also in nontumoral epithelium adjacent to high grade and invasive tumor samples in comparison to tumoral epithelium. Moreover, we compared nuclear grade and staining scores in our study and found that sensitivity and specificity of Claudin-4 was 50% and 12.8% respectively for high grade lesions. Although Claudin-4 staining was statistically meaningful to differentiate high grade lesions from low grade lesions, high negative predictive value of this marker could limit its reliability. As we mentioned before, there are a few study concerning claudin expressions in urothelial lesions of bladder; and different results are reported too. For that reason, we believe that this subject needs to be studied further in larger and more comprehensive studies.

Recent molecular studies indicated that two major subtypes of urothelial carcinoma of bladder (papillary/superficial and nonpapillary/invasive) are two different molecular entities. It was also said that muscle-invasive tumors develop thorough "epithelial-mesenchymal transition" process and for that reason they express some characteristic markers of this process [36]. In our study, we found that Claudin-4 expression was decreased markedly and specifically in carcinoma in situ and muscle-invasive tumors. And we believe that this result could be explained by loss of structural integrity of claudins during epithelial-mesenchymal transition causing in loss of expression.

4. CONCLUSION

In conclusion, claudins will acquire more attention in following years because of their correlation to clinical prognosis, recurrence and survival. In addition to that Claudin-3 and Claudin-4 are new therapeutic targets for CPE toxin which can be used in treatment of not only urothelial cancers but also all neoplastic processes. Moreover, we believe that especially Claudin-4 is helpful marker in patient follow up because loss of Claudin-4 expression points to the invasion capacity of tumor and gives us clue in clinical prognosis.

CONSENT

This study was approved by Diskapi YB Research and Training Hospital Ethics and Research Committee. (Approval ID: 66-32/07.06.2011).

ETHICAL APPROVAL

This study was approved by Diskapi YB Research and Training Hospital Ethics and Research Committee. (Approval ID: 66-32/07.06.2011).

This study was granted by Diskapi YB Research and Training Hospital Scientific Research Support Committee. Decision ID: 23-5/09.05.2011.

COMPETING INTERESTS

Authors have declared that no competing interests exist.

REFERENCES

1. Ferlay J, Soerjomataram I, Ervik M, Dikshit R, Eser S, Mathers C, Rebelo M, Parkin Dm, Forman D, Bray, F. Globocan 2012 V1.0, Cancer Incidence and Mortality Worldwide: Iarc Cancerbase no. 11 [Internet]. Lyon, France: International Agency for Research on Cancer; 2013. Available:<http://Globocan.Iarc.Fr> (Accessed on 26/06/2015)
2. Siegel R, Ma J, Zou Z, Jemal A. Cancer Statistics, 2014. CA Cancer J Clin. 2014; 64:9–29.
3. John N. Eble, Guito Sauter, Jonathan I. Epstein. World Health Organization Classification of Tumours-Pathology & Genetics, Tumours of the Urinary System and Male Genital Organs, IARC; 2004.
4. Solsona E. Best approach for low-risk superficial bladder cancer. Scientific World Journal. 2006;6:2638-2645.
5. Edge SB, Byrd DR, Compton CC, Fritz AG, Greene FL, Trotti A, eds. Urinary bladder in: AJCC Cancer Staging Manual. 7th ed. New York, NY: Springer; 2010.
6. Sitnikova L, Mendese G, Liu Q, Woda BA, Dresser K, Mohanty S, Rock KL, et al. IMP3 predicts aggressive superficial urothelial carcinoma of the bladder. Clin Cancer Res. 2008;14(6):1701-1706.
7. Krause G, Winkler L, Mueller SL, Haseloff RF, Piontek J, Blasig IE. Structure and function of claudins. Biochim Biophys Acta. 2008;1778(3):631-645.
8. González-Mariscal L, Garay E, Quirós M. Identification of claudins by western blot and immunofluorescence in different cell lines and tissues. Methods Mol Biol. 2011; 762:213-231.
9. Singh AB, Sharma A, Dhawan P. Claudin family of proteins and cancer: An overview. J Oncol. 2010;2010:541957.
10. Lal-Nag M, Morin PJ. The claudins. Genome Biol. 2009;10(8):235.
11. Michl P, Gress TM. Bacteria and bacterial toxins as therapeutic agents for solid tumors. Curr Cancer Drug Targets. 2004; 4(8):689-702.
12. Saeki R, Kondoh M, Uchida H, Yagi K. Potency of Claudin-targeting as antitumor Therapy. Mol Cell Pharmacol. 2010;2(2): 47-51.
13. Gao Z, McClane BA. Use of *Clostridium perfringens* enterotoxin and the enterotoxin receptor-binding domain (C-CPE) for cancer treatment: Opportunities and Challenges J Toxicol. 2012;2012:981626.
14. Grosse B, Cassio D, Yousef N, Bernardo C, Jacquemin E, Gonzales E. Claudin-1 involved in neonatal ichthyosis sclerosing cholangitis syndrome regulates hepatic paracellular permeability. Hepatology. 2012;55(4):1249-1259.
15. Soini Y. Expression of claudins 1,2,3,4,5 and 7 in various types of tumors. Histopathology. 2005;46:551-560.
16. Lee JW, Lee SJ, Seo J, Song SY, Ahn G, Park CS, et al. Increased expressions of claudin-1 and claudin-7 during the progression of cervical neoplasia. Gynecol Oncol. 2005;97(1):53-9.
17. Dos Reis PP, Bharadwaj RR, Machado J, Macmillan C, Pintilie M, Sukhai MA, et al. Claudin 1 overexpression increases invasion and is associated with aggressive histological features in oral squamous cell carcinoma. Cancer. 2008; 113(11):3169-3180.
18. Németh J, Németh Z, Tátrai P, Péter I, Somorácz A, Szász AM, et al. High expression of claudin-1 protein in papillary thyroid tumor and its regional lymph node metastasis. Pathol Oncol Res. 2010; 16(1):19-27.
19. Gröne J, Weber B, Staub E., Heinze M, Klamann I, Pilarsky C, et al. Differential expression of genes encoding tight junction proteins in colorectal cancer: Frequent dysregulation of claudin-1, -8 and -12. Int J Colorectal Dis. 2007;22(6): 651-659.
20. Krajewska M, Olson AH, Mercola D, Reed JC, Krajewski S. Claudin-1 immunohistochemistry for distinguishing malignant from benign epithelial lesions of prostate. Prostate. 2007;67(9):907-910.
21. Myal Y, Leygue E, Blanchard AA. Claudin 1 in Breast Tumorigenesis: Revelation of a Possible Novel “Claudin High” Subset of Breast Cancers. J Biomed Biotechnol. 2010;2010:956897.
22. Nakanishi K, Ogata S, Hiroi S, Tominaga S, Aida S, Kawai T. Expression of occludin and claudins 1, 3, 4, and 7 in urothelial carcinoma of the upper urinary tract. Am J Clin Pathol. 2008;130(1):43-49.
23. Székely E, Törzsök P, Riesz P, Korompay A, Fintha A, Székely T, et al. Expression of claudins and their prognostic significance in noninvasive urothelial neoplasms of the human urinary bladder. J

- Histochem Cytochem. 2011;59(10): 932-941.
24. Törzsök P, Riesz P, Kenessey I, Székely E, Somorácz A, Nyirády P, et al. Claudins and ki- 67 potential markers to differentiate low- and high-grade transitional cell carcinomas of the urinary bladder. *J Histochem Cytochem.* 2011; 59(11):1022-1030.
 25. Furuse M, Sasaki H, Tsukita S. Manner of interaction of heterogenous claudin species within and between tight junction strands. *J Cell Biol.* 1999;99:649-659.
 26. Bartholow TL, Chandran UR, Becich MJ, Parwani AV. Immunohistochemical profiles of claudin-3 in primary and metastatic prostatic adenocarcinoma. *Diagn Pathol.* 2011;6:12.
 27. Landers KA, Samaratunga H, Teng L, Buck M, Burger MJ, Scells B, et al. Identification of claudin-4 as a marker highly overexpressed in both primary and metastatic prostate cancer. *Br J Cancer.* 2008;99(3):491–501.
 28. Tsutsumi K, Sato N, Tanabe R, Mizumoto K, Morimatsu K, Kayashima T, et al. Claudin-4 expression predicts survival in pancreatic ductal adenocarcinoma. *Ann Surg Oncol.* 2012;19(Suppl 3):S491-9.
 29. Hewitt KJ, Agarwal R, Morin PJ. The claudin gene family: expression in normal and neoplastic tissues. *BMC Cancer.* 2006;6:186.
 30. Lechpammer M, Resnick MB, Sabo E, Yakirevich E, Greaves WO, Sciandra KT, et al. The diagnostic and prognostic utility of claudin expression in renal cell neoplasms. *Mod Pathol.* 2008;21(11): 1320-1329.
 31. Patonai A, Erdélyi-Belle B, Korompay A, Somorácz A, Straub BK, Schirmacher P, et al. Claudins and tricellulin in fibrolamellar hepatocellular carcinoma. *Virchows Arch.* 2011;458(6):679-88.
 32. Southgate J, Varley CL, Garthwaite MA, Hinley J, Marsh F, Stahlschmidt J, et al. Differentiation potential of urothelium from patients with benign bladder dysfunction. *BJU Int.* 2007;99(6):1506-1516.
 33. Acharya P, Beckel J, Ruiz WG, Wang E, Rojas R, Birder L, et al. Distribution of the tight junction proteins ZO-1, occludin, and claudin-4, -8, and -12 in bladder epithelium. *Am J Physiol Renal Physiol.* 2004;287(2):F305-318.
 34. Wang G, Wu XH. Expression of Claudin-3 in transitional cell carcinoma of the bladder and its significance. *Chongqing Medicine.* 2009-2017.
 35. Boireau S, Buchert M, Samuel MS, Pannequin J, Ryan JL, Choquet A, et al. DNA-methylation-dependent alterations of claudin-4 expression in human bladder carcinoma. *Carcinogenesis.* 2007;28(2): 246-258.
 36. McConkey DJ, Lee S, Choi W, Tran M, Majewski T, Lee S, et al. Molecular genetics of bladder cancer: Emerging mechanisms of tumor initiation and progression. *Urol Oncol.* 2010;28(4): 429-440.

© 2015 Kokenek-Unal et al.; This is an Open Access article distributed under the terms of the Creative Commons Attribution License (<http://creativecommons.org/licenses/by/4.0>), which permits unrestricted use, distribution, and reproduction in any medium, provided the original work is properly cited.

Peer-review history:
The peer review history for this paper can be accessed here:
<http://sciedomain.org/review-history/10573>