



# **Ultrasound Guided Erector Spinae Plane Block Versus Transverses Abdominis Plane Block for Post-Operative Analgesia in Pediatric Patients Undergoing Laparoscopic Inguinal Hernia Repair: A Randomized Controlled Trial**

**Nashwa Atef Badawy<sup>1\*</sup>, Mona Blough El Mourad<sup>1</sup>, Ahmed Said AL gebaly<sup>1</sup> and Yasser Mohamed Amr<sup>1</sup>**

<sup>1</sup>Anesthesiology, Surgical Intensive Care and Pain Medicine Department, Faculty of Medicine, Tanta University, Tanta, Egypt.

### **Authors' contributions**

*This work was carried out in collaboration among all authors. All authors read and approved the final manuscript.*

### **Article Information**

DOI: 10.9734/JAMMR/2021/V33I1130928

#### Editor(s):

(1) Dr. Zoran Todorovic, University of Belgrade and University Medical Center "Bezanijska Kosa", Serbia.

#### Reviewers:

(1) Aneta Piotrowska, Jan Kochanowski University, Poland.

(2) Arifa Akram, National Institute of Laboratory Medicine and Referral Centre (NILMRC), Bangladesh.

Complete Peer review History: <http://www.sdiarticle4.com/review-history/68276>

**Received 10 March 2021**

**Accepted 13 May 2021**

**Published 18 May 2021**

**Original Research Article**

## **ABSTRACT**

**Background:** Inguinal hernia repair is one of the most common surgical procedures in the pediatric age group and it is associated with significant post-operative discomfort. The aim of this study is to compare the safety, reliability, and efficacy of ultrasound-guided transverses abdominis plane (TAP) block versus erector spinae plane (ESP) block for postoperative pain control in pediatrics undergoing laparoscopic inguinal hernia repair.

**Methods:** This prospective randomized study was carried out on 90 pediatric patients of both sexes aged (2 -7) years with ASA physical status I/II scheduled for elective laparoscopic inguinal hernia repair. Patients were divided into 3 equal groups. Group C received general anesthesia alone. group T received bilateral ultrasound-guided TAP block after induction of general anesthesia with the injection of 0.4 ml/kg bupivacaine 0.25%. group E received bilateral ultrasound-guided

\*Corresponding author: E-mail: [dr.n.badawy@gmail.com](mailto:dr.n.badawy@gmail.com);

ESP block after induction of general anesthesia with the injection of 0.4 ml/kg bupivacaine 0.25%.  
**Results:** According to CHEOPS, we found no statistically significant difference between ESP and TAP groups but significant increase in the control group. also, There was a significant decrease in total rescue analgesia (intra-operative & postoperative ) in the T group and E as compared to group C. Also there was a significant delay in onset of first rescue analgesia post operatively between group T&E in comparison to group C. The mean value of heart rate between the 3 fascial plane showed no statistically significant difference between TAP and ESP groups intra-operatively but significant increase in heart rate in the control group in all stages of the operation as compared to T& E groups. Mean arterial blood pressure changes were insignificant between three groups in all stages of operation.  
**Conclusions:** TAP block and ESP block are effective and safe techniques for postoperative pain control in pediatric patients undergoing laparoscopic inguinal hernia repair with more hemodynamic stability, less intra and postoperative analgesia requirement.

**Keywords:** *Erector spinae plane block; transverses abdominis plane block; post-operative analgesia; pediatric; laparoscopic inguinal hernia repair.*

## 1. INTRODUCTION

Inguinal hernia repair is considered one of the most common surgical procedures performed in the pediatric age group and it is associated with significant post-operative discomfort [1].

Management of postoperative pain in pediatrics is of great concern to minimize complications and encourage early discharge from the hospital [2].

There are a lot of modalities for pain control in pediatrics including regional anesthesia, intravenous opioids, and intravenous or rectal non-opioid analgesics e.g. paracetamol [3].

Regional anesthesia is an important option in post-operative pain control as it provides an effective and safe analgesic [4].

Ultrasound assistance in nerve blocks has a great advantage as it provides a more safe and accurate injection, confirmation of the needle place, and real-time visualization of local anesthetic spread in the appropriate plane [5].

The transverses abdominis plane (TAP) block is a regional anesthetic technique introduced in 2001 by Rafi [6], it involves the injection of local anesthetic (LA) into the plane between the transverses abdominis and the internal oblique muscles [7] as there is extensive branching of nerves within this plane e.g the intercostal nerves, subcostal nerves and the first lumbar nerves that contribute in the innervation of the anterior abdominal wall [8].

It has wide application in laparoscopic surgery through the lower to mid-abdominal wall as It provides effective analgesia and can be used in various anterior abdominal wall procedures as

appendectomy, ventral hernia, inguinal hernia, and laparotomy [9].

The erector spinae plane (ESP) block is a novel technique described in 2016 by Forero et al. [10] in which LA is deposited in the fascial plane deep to the erector spinae muscle and superficial to the tip of the transverse process [11]. Its analgesic effect appears as a result of LA diffusion into the paravertebral space, affecting both the dorsal and ventral rami of the spinal nerves.

The aim of this study is to compare the safety, reliability, and efficacy of ultrasound-guided transverses abdominis plane (TAP) block versus ESP block for postoperative pain control in pediatrics undergoing laparoscopic inguinal hernia repair as regards the onset of first analgesic requirement as a primary outcome, as well as pain scores, total postoperative analgesic consumption and incidence of adverse effects as secondary outcomes.

## 2. PATIENTS AND METHODS

This prospective randomized study was carried out on 90 pediatric patients of both sexes aged (2 -7) years with ASA physical status I/II scheduled for elective unilateral laparoscopic inguinal hernia repair at Tanta University Hospital in the pediatric Department from August 2019 to January 2020. After approval from the institutional ethics committee, informed consent was taken from each patient's parents.

Exclusion criteria were: patient's parent's refusal, history of allergy to local anesthetics, patients with upper airway infection for 2 weeks ago or

less before surgery, history of developmental delay, mental retardation, or CNS disease, congenital spine anomaly, local infection at the site of the block, patients with bleeding and coagulation disorders, patients with renal, hepatic, or cardiac dysfunction.

The randomization was performed using sealed envelopes indicating the group of the assignment. A blinded nurse, who did not participate in the study or data collection, read the number contained in the envelope and made group assignments. The TAP block and ESP block were performed by me under the supervision of my staff, data was collected by another colleague, and drugs were prepared by a well-trained nurse.

Control group (group C): Consisted of 30 patients who received general anesthesia alone. TAP group (group T): Consisted of 30 patients who received bilateral ultrasound-guided TAP block after induction of general anesthesia with the injection of 0.4 ml/kg bupivacaine 0.25%. ESP group (group E): Consisted of 30 patients who received bilateral ultrasound-guided ESP block after induction of general anesthesia with the injection of 0.4 ml/kg bupivacaine 0.25%.

Preoperative assessment was done by: history taking, clinical examination, routine laboratory investigations (complete blood picture, bleeding time, clotting time, liver function tests, kidney function tests) and appropriate pre-operative fasting period.

All patients were monitored by standard monitoring including pulse oximetry, non-invasive blood pressure, and ECG. temperature probe and capnogram for end-tidal carbon dioxide monitoring were used after intubation.

Induction was done using 8% sevoflurane in 100% oxygen via a face mask. As soon as the child lost consciousness, a 22 G intravenous line was established and fentanyl (1 µg/kg) was given. Muscle relaxation was performed with 0.5 mg/kg atracurium to facilitate the insertion of the endotracheal tube of appropriate size. Anesthesia was maintained with 2-3% sevoflurane in 100% oxygen and atracurium 0.1 mg/kg as needed.

Appropriate glucose-containing solutions (pediament) were given according to body weight using the formula; for maintenance 4 ml/ kg for the first 10 kg, 2 ml /kg for the second 10 kg, and 1 ml/kg for the rest body weight. third space loss

(1 ml/kg) and deficit were calculated and replaced with lactated ringer.

After induction of general anesthesia, patients in the control group received general anesthesia alone. patients in the TAP group (T) received bilateral ultrasound-guided lateral TAP block with the injection of 0.4 ml/kg bupivacaine 0.25%, while patients in ESP Block group (E) received bilateral ultrasound-guided ESP block with injection of 0.4 ml/kg bupivacaine 0.25% (maximum dose 2 mg/kg, maximum volume 20 ml).

## 2.1 Technique of TAP Block

While the patient in the supine position and under complete aseptic technique and skin disinfection by 10% betadine solution, the linear ultrasound probe with probe cover and the sterile gel was placed on the abdominal wall at the level of the umbilicus. Following identification of the rectus abdominis muscle, the probe was moved laterally midway between the iliac crest and the costal margin until a view of the three muscle layers of the abdominal wall (external oblique m Internal oblique and transversus abdominis) with their related fascia obtained. A50 mm 22 gauge needle was inserted between the internal oblique and the transversus abdominis muscles by the in-plane approach. Injection of 0.2 ml/kg bupivacaine 0.25% was done after negative aspiration to avoid intravascular injection. The technique was repeated on the other side.

## 2.2 Technique of ESP Block (Group E)

The patient was turned prone and an ESP block was performed with sterile technique (as mentioned before). The probe was placed into a longitudinal, parasagittal orientation over the tip of the transverse processes of T7. A 22 gauge 50 mm short-beveled-needle was inserted in-plane, in a cranial-to-caudal direction until contacting the tip of the transverse process (T7) underneath the fascia of the erector spinae muscle. At this point, 0.2 ml /kg bupivacaine 0.25% was injected after negative aspiration, and the spread of local anesthetic (LA) was visualized separating the erector spinae muscle. The technique was repeated on the other side.

Surgery started ten minutes after performing the blocks. Increased HR or MAP more than 20% of the baseline values during the surgery was considered a sign of insufficient analgesia and 1 µg/kg IV fentanyl was given.

The same technique for inguinal hernia repair was done by the same technique by consultant pediatric surgeons.

no pain. Patients with modified CHEOPS score >6 received rescue analgesia in the form of 1 µg/kg of fentanyl.

The total amount of intraoperative fentanyl given as rescue analgesia was recorded. After completion of the surgical procedure, general anesthesia was discontinued and the endotracheal tube was removed after reversal of the effect of the muscle relaxant with 0.05 mg/kg neostigmine and 0.01 mg/kg atropine. Patients were transferred to the recovery room for continuous follow up of vital signs and assessment of pain. All patients received regular analgesia in the form of intravenous paracetamol 15mg/kg every 6 h.

The onset of the first postoperative analgesic requirement and the total amount of fentanyl administered as rescue analgesia were recorded.

Mean arterial blood pressure (MAP) and heart rate (HR) were recorded pre-operatively and after ET insertion as (T0), at skin incision (T1), 5, 10, 15, 20, 25, 30 minutes after skin incision (T2-T7), and immediately before extubation (T8).

### 2.3 Measurements

Postoperative analgesia was measured using a modified Children's Hospital of Eastern Ontario Pain Scale (CHEOPS) at the following intervals: on arrival to the recovery room (0h), then at 1, 2, 4, 8, 12, and 24 hours. Minimum score: 4 and maximum score: 13. Scores of 6 or less indicate

Adverse effects: was observed and treated as follows when happened. Hypotension (20% decrease in blood pressure compared to baseline) was treated with rapid IV fluid infusion and bolus ephedrine 0.1 mg/kg if needed. Bradycardia less than 80 bpm for toddlers and young children was treated with atropine 0.01 mg/ kg. Postoperative vomiting was treated by ondansetron 0.15 mg/kg.

**Table 1. Modified Children's Hospital of Eastern Ontario Pain Scale (CHEOPS): [12]**

Item	Behavior	score
cry	No cry	1
	Moaning . crying	2
	screaming	3
Facial	smiling	0
	composed	1
	Grimace	2
Child verbal	None	1
	Other complaint	2
	Pain complaint	3
Torso	Neutral	1
	Shifting	2
	Tense	2
	Shivering	2
	upright	2
	restrained	2
Touch	Not touching	1
	Reach	2
	Touch	2
	Grab	2
	Restrained	2
Legs	Neutral	1
	Squirming , kinking	2
	Drawn up / Tensed	2
	Standing	2
	Restrained	2

Side effects related to the nerve block techniques (infection, hematoma, and local anesthetic toxicity) were recorded and Resuscitation drugs for cardiac arrest and intralipid 20% solution for the treatment of systemic toxicity were ready.

### 2.4 Justification of Sample Size

Our primary outcome variable was the onset of the first postoperative analgesic requirement .based on the results of the previous study [13], a sample size of 27 patients was calculated to detect a difference of 5.2 hours in the onset of the first postoperative analgesic requirement of at 80% power of the study with a standard deviation of 6.8 at  $\alpha$  error 0.05. So we included 30 patients in each group for possible dropouts.

### 2.5 Statistical Analysis

Data were analyzed using computer statistical software system SPSS version 14.0 (SPSS Inc., Chicago, IL, USA). Kolmogorov- Smirnov tests were used to check the normality of data. Parametric variables were compared using one-way ANOVA and the chi-square test were used for categorical variables. CHEOPS scores were compared using the Kruskal-Wallis test. P value < 0.05 was considered significant.

## 3. RESULTS

The three groups were comparable regarding age, weight, sex, ASA physical status and duration of anesthesia Table 2.

Comparing the mean value of HR between the 3 groups showed a significant increase in HR in group C as compared to T& E groups at T1, T2, T3, T4, T5, T6, T7, T8. Comparing the mean value of HR between group T & group E showed non-significant changes in HR between the two groups at different times of measurements. Fig. 1.

Comparing the mean value of MAP showed no statistically significant changes among the three groups at different times of measurements Fig. (2).

Comparing of the values of CHEOPS postoperatively showed significant changes between the 3 groups at H1, 2, 4, 8, 12, and 24 hr. comparing of values of CHEOPS between group C and group T showed a significant decrease at H1, 2, 4, 8, 12, and 24 hrs in group T. Comparing of values of CHEOPS between group C and group E showed a significant decrease at H1, 2, 4 , 8, 12, and 24 hrs in group E . comparing of values of CHEOPS between group T and group E changes was statistically non-significant Fig. (3).

There was a significant decrease in total rescue analgesia (intraoperative) in group T and E as compared to group C. comparing between group E and group T showed non-significant changes. Table (3).

**Table 2. Demographic data of the studied patients**

		Group C n=30	Group T n=30	Group E n=30	P value
Age (years)	Median (Range)	4 (2 – 7)	5 (2 – 7)	4 (2 – 7)	0.560
Sex	Male	N	19	18	0.866
		%	63.33 %	60 %	
	Female	N	11	12	
		%	36.67 %	40 %	
ASA	I	N	21	20	0.949
		%	70%	66.67%	
	II	N	9	10	
		%	30%	33.33%	
Weight (kg)	Mean ± SD	16.43 ± 3.58	16.93 ± 3.67	17.03 ± 3.31	0.780
Duration of anesthesia (minute)	Mean± SD	62.33 ± 8.87	66 ± 9.5	63.16 ± 8.55	0.259

ASA: American society of anesthesiologists

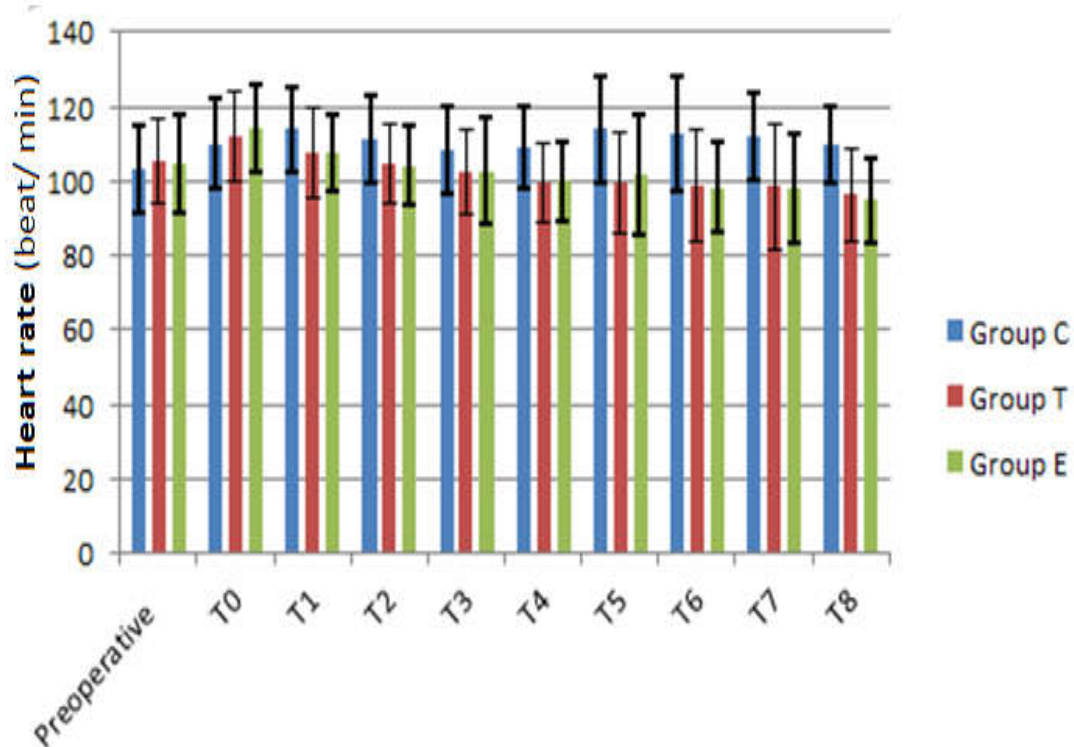


Fig. 1. Comparison of heart rate (beat/min) in the three studied groups

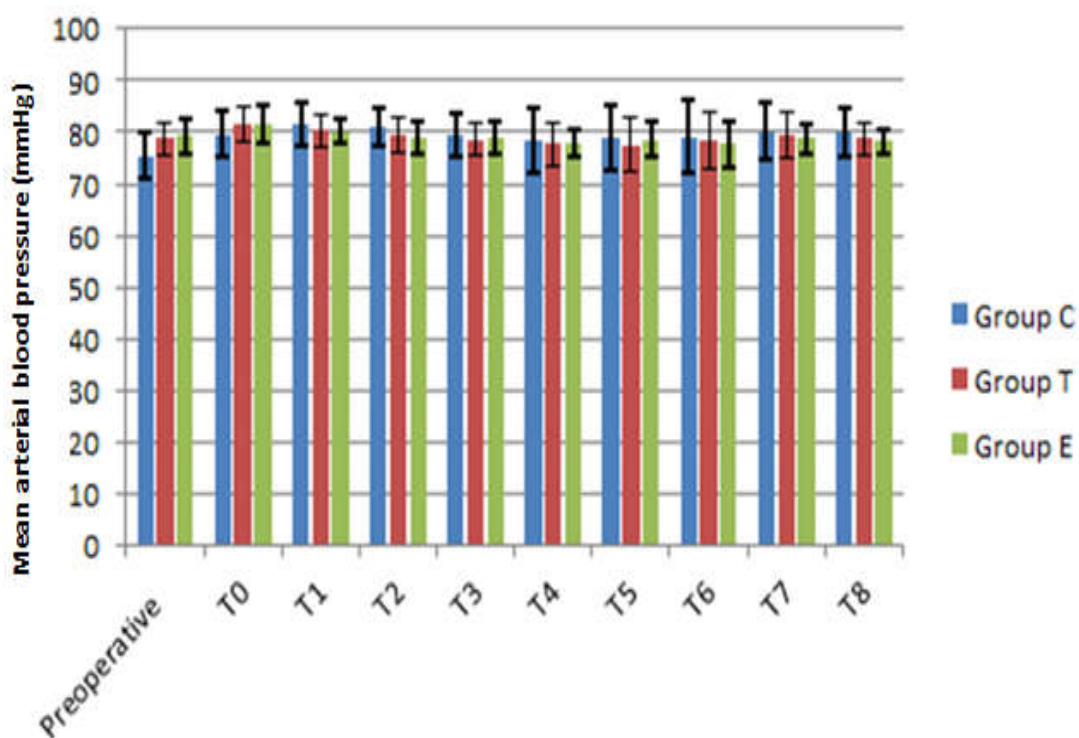


Fig. 2. Comparison of mean arterial blood pressure in the 3 studied groups.

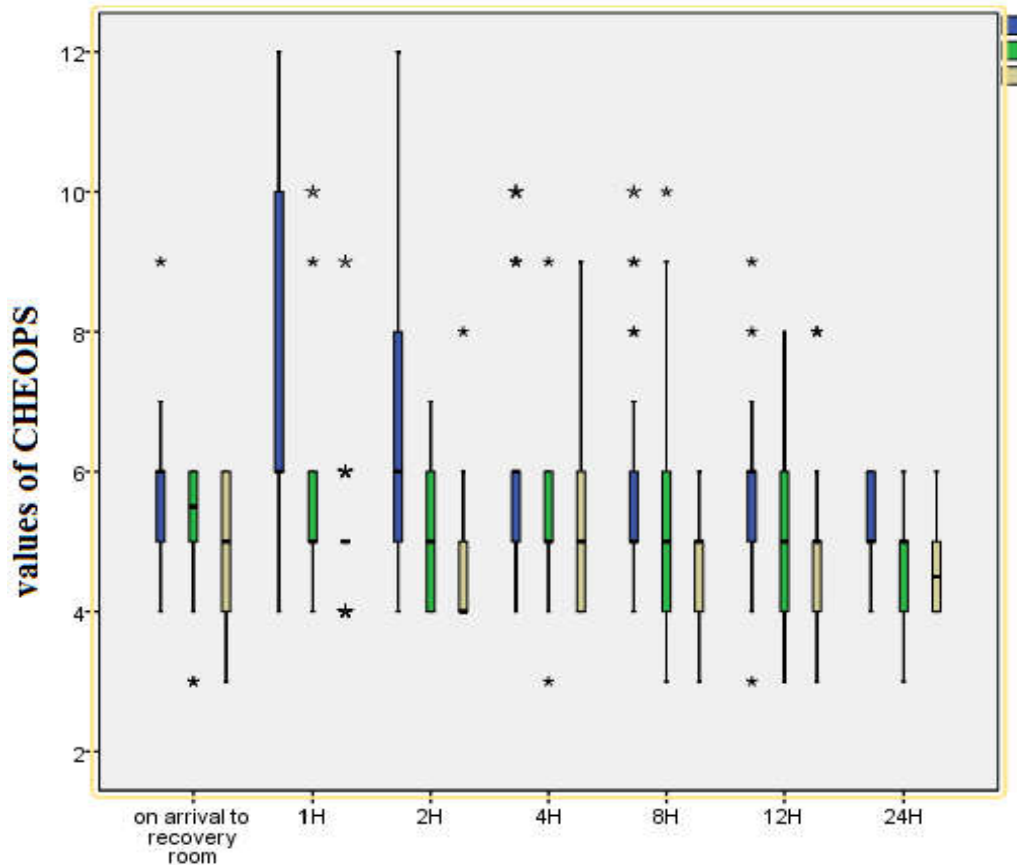


Fig. 3. Comparison of CHEOPS in the 3 studied groups

The mean value of the onset of first Rescue analgesia by hours (postoperative) was  $1.54 \pm 0.91$  hours in group C, in group T it was  $5.5 \pm 4.07$  hours, while in group E it was  $5.37 \pm 4.24$  hours. There was significant delay in the onset of first postoperative Rescue analgesia by hours in group T and E as compared to group C. The change in the onset of first postoperative rescue analgesia by hours was statistically non significant between group T&E. Table (3).

The median (range) of total rescue analgesia by mic (postoperative) was 22.5 (0-60)mic. in group C, in group T it was 0 (0-25) mic, while in group E it was 0 (0-20) mic. There was a significant decrease in total postoperative rescue analgesia in group T and E as compared to group C. There was no significant change in total postoperative rescue analgesia in group T and E. Table (3).

Complications were comparable among three groups Table 4.

#### 4. DISCUSSION

Regional anesthesia is increasingly used in pediatric patients to provide postoperative analgesia and intraoperative anesthesia, [14] and it has been proved to attenuate the perioperative stress response, allow early tracheal extubation after major abdominal or thoracic surgery, minimize the number of days spent in the intensive care unit and allow rapid recovery of gastrointestinal function [15].

In this work, when comparing CHEOPS between the three groups we found a significant increase in the control group as compared to the other two groups with no statistically significant difference between ESPB and TAP groups. In addition, There was a significant decrease in the total rescue analgesic requirements (intraoperative & postoperative) in group T and group E as compared to group C. Also, there was a significant delay in the onset of the first rescue analgesia postoperatively between group T&E in comparison to group C.

**Table 3. Total amount of intraoperative analgesia (fentanyl by mic)**

Patient NO	Group C n=30	Group T n=30	Group E n=30
Total amount of intraoperative analgesia (fentanyl by mic)			
Median	15	0	0
Range	0 – 40	0 - 20	0 – 20
Interquartile range	0 – 20	0 - 0	0 – 0
Number of patients needed analgesia	No 18 60%	6 20%	5 16.67%
P value (Kruskal Wallis test )	<0.001 *		
P value C-T	<0.001 *		
P value C –E	<0.001 *		
P value T-E	0.793		
Onset of first postoperative Rescue analgesia by hours			
Mean ± SD	1.54± 0.91	5.5 ±4.07	5.37 ±4.24
P value (ANOVA test)	<0.001 *		
P value C –T	<0.001 *		
P value C- E	<0.001 *		
P value T – E	0.953		
Total postoperative rescue analgesia by mic:			
Median	22.5	0	0
Range	0 - 60	0 – 25	0 – 20
Interquartile range	0 - 40	0 – 15	0 – 12.75
P value (Kruskal Wallis test )	<0.001 *		
P value (kruskal Wallis test)	<0.001 *		
P value C – T	<0.001 *		
P value C –E	<0.001 *		

\* Denotes statistically significant difference at *p. value* < 0.05. *P value* presented the comparison between the 3 groups. C-T presented the comparison between group C and group T. C-E presented the comparison between group C and group E. T-E presented the comparison between group T and group E.

**Table 4. Complications in the 3 groups**

	Group C n=30		Group T n=30		Group E n=30		P value
	No	%	No	%	No	%	
Vomiting	3	10%	3	10%	2	6.67%	0.872
Bradycardia	0	0%	2	6.67%	0	0%	0.129
Hypotension	2	6.67%	2	6.67%	1	3.33%	0.809
Local anaesthetic toxicity	0	0%	0	0%	0	0%	1
Injection site hematoma	0	0%	0	0%	0	0%	1
Injection site infection	0	0%	0	0%	0	0%	1

\* Denotes statistically significant difference at *p. value* < 0.05

Many studies had concluded the efficacy of TAP block in pediatrics for postoperative analgesia.

According to Karnik et al. [16] Ultrasound-guided TAP block was superior to local port site infiltration during pediatric laparoscopic surgeries. The postoperative pain scores and the need for rescue analgesia were significantly lower in the TAP group.

Efficacy of TAP block is also supported by Al-Sadek et al. [17] who studied Ultrasound-guided TAP block in pediatric patients undergoing laparoscopic undescended testis. TAP block group had significantly lower intraoperative fentanyl dose, significantly longer time to first postoperative request of analgesia, lower analgesic dose during the first postoperative 24 h, and lower pain scores along the whole 24



postoperative hours. Parents' satisfaction was significantly higher in the TAP block group.

Moreover, Sahin, et al. [13] compared Ultrasound-guided TAP block with wound infiltration in children undergoing unilateral open inguinal hernia repair. 57 children between 2 and 8 years of age undergoing unilateral inguinal hernia repair were randomized to TAP block or to wound infiltration. It was found that Ultrasound-guided TAP block with high volume ( $0.5 \text{ ml kg}^{-1}$ ) 0.25% levobupivacaine provides prolonged postoperative analgesia and reduced analgesic use without any clinical side-effects after unilateral hernia repair in children.

Meanwhile, Seyedhejazi, et al. [18] studied the efficacy of TAP block in Pain Control by Block in Children after appendectomy 40 children aged from 4 to 16 years, candidates for the appendectomy, were divided randomly into intervention and control groups. They concluded that the TAP block reduces the intensity and frequency of post appendectomy pain in children; however, there was no statistically significant difference between the two groups. The first time to request pain medication in the control group was earlier than the intervention group; however, this difference was not also statistically significant, the difference in age, and type of surgery in these studies could explain these conflicting results.

While Arora, et al. [19] studied the efficacy of TAP block in laparoscopic inguinal hernia repair. Seventy-one patients aged 18 to 65 years, undergoing unilateral/bilateral laparoscopic hernia repair were randomized to port site infiltration and TAP block groups. The result was that TAP block reduced postoperative pain up to 24 hours after laparoscopic hernia repair.

On the other hand, Sandeman, et al. [20] studied Ultrasound-guided TAP block for laparoscopic appendectomy in children. 93 children aged 7–16 were randomized to receive ultrasound-guided TAP blocks before surgery or not (control). All subjects had port sites infiltrated with ropivacaine and were prescribed i.v. patient-controlled analgesia (PCA) with morphine and oral paracetamol for postoperative pain. They found that there was no significant difference in PCA morphine use, time intervals to the first use of PCA or other analgesics, or amounts of other analgesics. TAP offered no clinically important benefit over local anesthetic port-site infiltration to pediatric patients undergoing laparoscopic

appendectomy. They thought that this might be because more patients in the TAP group had a complicated or perforated appendix and pus or intraoperative free fluid.

The reported complications of the TAP block were recorded by Long, et al. [21] who studied the safety of TAP block in children in multicenter safety analysis of 1994 cases. This was an observational study using the pediatric regional anesthesia network database. A complication from the TAP block was defined by the presence of at least one of the following intraoperative and/or postoperative factors: puncture of the peritoneum or organs, vascular puncture, cardiovascular, pulmonary, and/or neurological symptoms/signs, hematoma, and infection. Only 2 complications were reported: a vascular aspiration of blood before local anesthetic injection and a peritoneal puncture and a specific incidence of complications (vascular aspiration or peritoneal puncture). Neither of these complications resulted in additional interventions or sequelae. The upper incidence of overall complications associated with the TAP block in children was 0.3%. More important, complications were very minor and did not require any additional interventions.

According to our study, both blocks are safe and effective but the presence of a bony landmark in ESP block may make it a little bit safer, although the use of ultrasound limits the visceral injury complications and pneumoperitoneum that had been reported with TAP block.

ESP block efficacy and safety in both adults and pediatrics had been evaluated in many studies.

Can Aksu et al. [22] compared ESP Block vs Quadratus Lumborum Block in pediatrics undergoing lower abdominal surgery. Sixty patients were randomized into two groups. Only five patients from the ESP group and six from the QLQ group were reported to require additional analgesia at home. Oral acetaminophen was enough for the rest of the cases.

Also, the benefit of the ESP block was supported by, Mostafa et al. [23] who evaluated Ultrasonography-guided ESP block for postoperative analgesia in pediatric patients undergoing splenectomy. Sixty patients aged 3-10 years enrolled in the study and were randomly assigned into two groups: the Control group received general anesthesia with bilateral sham ESP block using  $0.3 \text{ mL/kg}$  normal saline

on each side. The ESP block group received bilateral ultrasound-guided ESP block using 0.3 mL/kg bupivacaine 0.25% (on each side). It was found that Ultrasound-guided ESP block resulted in lower post-operative CHEOPS score in pediatric patients undergoing open midline splenectomy with the reduction of intraoperative fentanyl and postoperative analgesic consumptions.

As well, Elkoundi, et al. [24] reported the efficacy of ESP block as they used the block with a case of a pediatric patient undergoing hip surgery. No systemic analgesics were needed apart from the scheduled acetaminophen administered 30 min before the end of the surgery. The result was that the ESP block led to a reduction in the FLACC scale score to 1 without further need for opioid analgesics.

The safety and efficacy of ESP block were also reported by Aksu, et al. [25] who studied the Indications and Levels of ESP Block in Pediatric Patients. One hundred and forty-one pediatric patients who received ESPB were included in this retrospective observational study. The result was agreed with our results that ESPB is found to be a safe and effective method for achieving opioid-free postoperative analgesia in many different surgical procedures in pediatric patients.

To our knowledge there were no previous studies comparing TAP block with ESP block in pediatric patients, however, many studies were carried out in the adult population.

Our results were supported by Tulgar, et al. [26] who compared Ultrasound-Guided ESP block and oblique subcostal TAP block in laparoscopic cholecystectomy. 60 patients aged 18–65 years were randomized into three equal groups (ESPB, Oblique Subcostal TAP, and control group). They concluded that Bilateral ultrasound-guided ESPB and OSTAP performed at the end of Laparoscopic Cholecystectomy lead to decreased first 24 h analgesia requirement and improve the quality of multimodal analgesia when compared to a control group.

On the other side Malawat, et al. [27] Compared TAP block and ESP block for postoperative analgesia in the cesarian section. Sixty patients scheduled for elective cesarean section under spinal anesthesia were randomly divided into ESP block or TAP block groups. The result was that the ESP block provided prolonged analgesia compared to the TAP block, and the mean time

to first rescue analgesia was significantly delayed in the ESP group than the TAP group. The requirement for total analgesic was also significantly less in the ESP group compared to the TAP group. They concluded that ESP block provided prolonged analgesia with a significant decrease in analgesic requirement compared to TAP block and can be used as a standard technique for post-cesarean analgesia.

Also, Kamel, et al. [28] compared Bilateral Ultrasound-Guided ESP Block Versus TAP block on postoperative analgesia after total abdominal Hysterectomy. 48 women were randomly allocated into 2 equal groups: erector spinae (ES) and transverses abdominis (TA) group. It was found that the bilateral ultrasound-guided ESP block provides more potent and longer postoperative analgesia with less morphine consumption than the TAP block after open total abdominal hysterectomy.

This is conflicting with our results and this may be due to difference in the population between the studies or the variety in pain intensity between the different procedures as the visceral pain in laparoscopic inguinal hernia is lower than other operation that targets internal organs, also pain intensity due to abdominal wall incisions in laparoscopic procedures is mild to moderate pain in comparison with severe pain of open operations. So, ESP block in our study has no superior effect over TAP block as the major component of pain originating from trochar site incisions in addition to the surgical repair.

In our study, Comparing the mean value of HR between the 3 groups showed no statistically significant difference between TAP and ESP groups intra-operatively but a significant increase in HR in the control group in all stages of operation as compared to T& E groups.

Comparing MAP between the 3 groups showed no statistically significant difference between the 3 groups intra-operatively. This was supported by Elkoundi, et al. [24] who found that Changes in blood pressure and HR didn't exceed 10% of the baseline (recorded at anesthetic induction) with ESP block. Also, Al-Sadek et al. [17] supported our results as they found that the MAP and HR both become statistically significantly lower in the TAP block group compared to the control group 15 min after induction and intra-operatively. However, the differences between the two groups were always clinically insignificant. However, all changes were within the clinically

accepted range. Parents' satisfaction was significantly higher in the TAP block group.

There were some limitations in our study, the first limitation was the lack of assessment of dermatomal block as the blocks were performed after the induction of general anesthesia. Another limitation was the inability to determine block failure or lack of efficiency under general anesthesia which may not have been recorded or may have been overlooked. we tried to overcome this limitation by close monitoring for intraoperative HR and blood pressure and recording onset of first intraoperative rescue analgesia and measurement of the total amount of intraoperative fentanyl needed.

## 5. CONCLUSIONS

TAP block and ESP block are effective and safe techniques for postoperative pain control in pediatric patients undergoing laparoscopic inguinal hernia repair with more hemodynamic stability, less intra and postoperative analgesia requirement.

## CONSENT AND ETHICAL APPROVAL

This prospective randomized study was carried out on 90 pediatric patients of both sexes aged (2 -7) years with ASA physical status I/II scheduled for elective unilateral laparoscopic inguinal hernia repair at Tanta University Hospital in the pediatric Department from August 2019 to January 2020. After approval from the institutional ethics committee, informed consent was taken from each patient's parents.

## COMPETING INTERESTS

Authors have declared that no competing interests exist.

## REFERENCES

1. Dhakaita S, Jain P, Chaudhary MK, Sharma R, Tiwari M. Congenital inguinal hernia repair in a medical college. *International Journal of Surgery and Surgical Sciences*. 2016;4:9-11.
2. Ahmad N, Greenaway S. Anaesthesia for inguinal hernia repair in the newborn or ex-premature infant. *british journal of anaesthesia education*. 2018;18:211-7.
3. Walker SM. Pain after surgery in children: Clinical recommendations. *Current opinion in anaesthesiology*. 2015;28:570.
4. Bosenberg A. Benefits of regional anesthesia in children. *Pediatric Anesthesia*. 2012;22:10-8.
5. Rosenberg PH. Future of regional anaesthesia. *Acta anaesthesiologica scandinavica*. 2005;49:913-8.
6. Rafi A. Abdominal field block: A new approach via the lumbar triangle. *Anaesthesia*. 2001;56:1024-6.
7. Tran T, Ivanusic J, Hebbard P, Barrington M. Determination of spread of injectate after ultrasound-guided transversus abdominis plane block: a cadaveric study. *British journal of anaesthesia*. 2009;102:123-7.
8. Suresh S, Chan VW. Ultrasound guided transversus abdominis plane block in infants, children and adolescents: a simple procedural guidance for their performance. *Pediatric Anesthesia*. 2009;19:296-9.
9. Johns N, O'neill S, Ventham N, Barron F, Brady R, Daniel T. Clinical effectiveness of transversus abdominis plane (TAP) block in abdominal surgery: A systematic review and meta-analysis. *Colorectal Disease*. 2012;14:e635-e42.
10. Tulgar S, Selvi O, Senturk O, Serifsoy TE, Thomas DT. Ultrasound-guided erector spinae plane block: indications, complications, and effects on acute and chronic pain based on a single-center experience. *Cureus*. 2019;11.
11. Muñoz F, Cubillos J, Bonilla AJ, Chin KJ. Erector spinae plane block for postoperative analgesia in pediatric oncological thoracic surgery. *Canadian Journal of Anesthesia/Journal canadien d'anesthésie*. 2017;64:880-2.
12. Min TJ, Kim WY, Jeong WJ, Choi JH, Lee YS, Kim JH, et al. Effect of ketamine on intravenous patient-controlled analgesia using hydromorphone and ketorolac after the Nuss surgery in pediatric patients. *Korean journal of anesthesiology*. 2012;62:142.
13. Sahin L, Sahin M, Gul R, Saricicek V, Isikay N. Ultrasound-guided transversus abdominis plane block in children: A randomised comparison with wound infiltration. *European Journal of Anaesthesiology*. 2013;30:409-14.
14. Polaner DM, Taenzer AH, Walker BJ, Bosenberg A, Krane EJ, Suresh S, et al. Pediatric regional anesthesia network (PRAN): A multi-institutional study of the use and incidence of complications of

- pediatric regional anesthesia. *Anesthesia and Analgesia*. 2012;115:1353-64.
15. Willschke H, Marhofer P, Machata AM, Lönnqvist PA. Current trends in paediatric regional anaesthesia. *Anaesthesia*. 2010; 65:97-104.
  16. Karnik PP, Dave NM, Shah HB, Kulkarni K. Comparison of ultrasound-guided transversus abdominis plane (TAP) block versus local infiltration during paediatric laparoscopic surgeries. *Indian Journal of Anaesthesia*. 2019;63:356.
  17. Al-Sadek WM, Rizk SN, Selim MA. Ultrasound guided transversus abdominis plane block in pediatric patients undergoing laparoscopic surgery. *Egyptian Journal of Anaesthesia*. 2014;30:273-8.
  18. Seyedhejazi M, Motarabbesoun S, Eslampoor Y, Taghizadieh N, Hazhir N. appendectomy pain control by transversus abdominis plane (TAP) Block in Children. *Anesthesiology and pain medicine*. 2019;9.
  19. Arora S, Chhabra A, Subramaniam R, Arora MK, Misra MC, Bansal VK. Transversus abdominis plane block for laparoscopic inguinal hernia repair: A randomized trial. *Journal of clinical anesthesia*. 2016;33:357-64.
  20. Sandeman D, Bennett M, Dilley AV, Perczuk A, Lim S, Kelly KJ. Ultrasound-guided transversus abdominis plane blocks for laparoscopic appendectomy in children: A prospective randomized trial. *British journal of anaesthesia*. 2011;106:882-6.
  21. Long JB, Birmingham PK, De Oliveira Jr GS, Schaldenbrand KM, Suresh S. Transversus abdominis plane block in children: A multicenter safety analysis of 1994 cases from the PRAN (Pediatric Regional Anesthesia Network) database. *Anesthesia&Analgesia*. 2014;119:395-9.
  22. Aksu C, Şen MC, Akay MA, Baydemir C, Gürkan Y. Erector spinae plane block vs quadratus lumborum block for pediatric lower abdominal surgery: A double blinded, prospective, and randomized trial. *Journal of Clinical Anesthesia*. 2019;57: 24-8.
  23. Mostafa SF, Abdelghany MS, Abdelraheem TM, Abu Elyazed MM. Ultrasound-guided erector spinae plane block for postoperative analgesia in pediatric patients undergoing splenectomy: A prospective randomized controlled trial. *Pediatric Anesthesia*. 2019;29:1201-7.
  24. Elkoundi A, Bentalha A, El Kettani SE-C, Mosadik A, El Koraichi A. Erector spinae plane block for pediatric hip surgery-a case report. *Korean journal of anesthesiology*. 2019;72:68.
  25. Aksu C, Gurkan Y. Defining the indications and levels of erector spinae plane block in pediatric patients: A retrospective study of our current experience. *cureus*. 2019; 11.
  26. Tulgar S, Kapakli MS, Kose HC, Senturk O, Selvi O, Serifsoy TE, et al. Evaluation of ultrasound-guided erector spinae plane block and oblique subcostal transversus abdominis plane block in laparoscopic cholecystectomy: randomized, controlled, prospective study. *Anesthesia, Essays&Researches*. 2019;13:50.
  27. Malawat A, Verma K, Jethava D, Jethava DD. Erector spinae plane block and transversus abdominis plane block for postoperative analgesia in cesarean section: A prospective randomized comparative study. *Journal of Anaesthesiology, Clinical Pharmacology*. 2020;36:201.
  28. Kamel AAF, Amin OAI, Ibrahim MAM. Bilateral ultrasound-guided erector spinae plane block versus transversus abdominis plane block on postoperative analgesia after total abdominal hysterectomy. *Pain Physician*. 2020;23:375-82.

© 2021 Badawy et al.; This is an Open Access article distributed under the terms of the Creative Commons Attribution License (<http://creativecommons.org/licenses/by/4.0>), which permits unrestricted use, distribution, and reproduction in any medium, provided the original work is properly cited.

*Peer-review history:*

The peer review history for this paper can be accessed here:  
<http://www.sdiarticle4.com/review-history/68276>