



A Three-part Broken Interlocking Femoral Nail: Novel Technique of Removal and Review of Literature

**A. Raviraj¹, K. Abhishek Sugumar¹, Vidyasagar Maalepati¹, H. A. Shivareddy¹
and Ashish Anand^{2*}**

¹*Apollo Hospitals, Bannerghatta Road, Bangalore - 560076, India.*

²*University of Mississippi Medical Center, Jackson, MS, USA. Professor-William Carey School of
Osteopathic Medicine, Hattiesburg, MS, USA.*

Authors' contributions

This work was carried out in collaboration among all authors. All authors read and approved the final manuscript.

Article Information

DOI: 10.9734/JAMMR/2021/v33i1230940

Editor(s):

(1) Dr. Rameshwari Thakur, Muzaffarnagar Medical College, India.

Reviewers:

(1) Dragoljub Zivanovic, University of Nis, Serbia.

(2) Ramy Ahmed Diab, Ain Shams University, Egypt.

Complete Peer review History: <http://www.sdiarticle4.com/review-history/68745>

Case Study

Received 17 March 2021

Accepted 22 May 2021

Published 26 May 2021

ABSTRACT

A segmentally broken (three part) interlocking femoral nail with broken interlocking screw can be challenging to remove. We describe a novel technique for extraction of an unusual two level broken cannulated anterograde femoral nail to treat the delayed union with exchange nailing. This is the first reported case of a three-part broken intramedullary interlocking nail with broken distal locking screws, where the broken hardware was removed without opening the fracture site or the knee. This technique is simple and does not require specialized equipment. The surgical technique and review of literature is presented.

Keywords: Femur; fracture; broken nail; removal.

1. INTRODUCTION

Removal of broken intramedullary nail in orthopaedic surgery is usually encountered in revision fracture surgery for nonunion, mal union, infection and peri-implant failure. If the hardware has broken this can make revision surgery even more demanding. Numerous techniques have been described to facilitate implant removal. A broken femoral nail is not an uncommon presentation of a delayed union or a nonunion [1].

The previously described techniques in the literature are for the removal of intramedullary nails such as Kuntcher nail. We came across only one report of a segmentally broken interlocking femur nail with distal interlocking screw broken. But the authors describe removal through the nonunion site and using an allograft to achieve union [2].

Our case is unique in the fact that we did not open the fracture site or knee for removal of broken implants. We used a higher diameter and a longer nail for fixing the fracture and achieving the union. We did not use any bone graft in our case.

2. CASE REPORT

A twenty-year-old lady presented to us 10 months post surgery with pain and difficulty bearing weight on her right leg. She had undergone a closed interlocking femur nailing for compound fracture of the femur, sustained due to motor vehicle accident.

The radiograph showed a segmentally broken (three part) interlocking femur nail with broken distal interlocking screw. Fig. 1. An implant removal and exchange nailing were planned. However, as the nail was in three parts the following technique was followed.

2.1 The Surgical Technique

Patient was placed supine on a fracture table and intraoperative image intensifier was used. An incision was placed proximal to the greater trochanter through old scar, the proximal end of the nail was exposed, and the extraction jig was used. The proximal broken piece was removed. The nail was found to be of 9 mm diameter.

The distal interlocking screw was removed. The proximal of the distal screws was found broken

and the nail was also found broken at that site. The proximal half of the screw was removed with a screwdriver and a Steinman pin was used to drive the remaining half of the screw medially.

The proximal portion of the medullary canal was reamed over a guide wire up to 12mm. A nonball tipped guide was introduced from the proximal femur and guided into the middle segment of the nail. Through the proximal of the distal locking screw holes, a guide wire with a curved tip and a ball just half an inch proximal to the tip was introduced such that the curved tip was driven into the distal portion of the middle segment of the nail. The ball of the guide wire engaged the distal portion of the middle segment of the nail Fig. 2. A T-handle was attached to this to mallet the nail gently. It was found that the nail segment was moving proximally over the guide wires as gentle tapping was done. Thus, the middle segment was delivered out through the proximal femur at the greater trochanter area.

Now a non ball tipped wire was curved at the tip and was introduced from the greater trochanter area towards the broken distal most piece. Care was taken so that the wire went outside the nail fragment and the hook engaged the nail from distal end. Gentle tapping was done to withdraw the nail piece proximally into the medullary canal. Fig. 3. As the broken nail piece was being withdrawn proximally, it assumed a tilt with the distal end of the piece coming towards the rent in the cortex corresponding to the proximal of the distal two locking bolts. This particular lateral cortex rent was enlarged slightly obliquely in the proximo-distal direction, and the tip of the nail was removed. This broken piece Fig. 4. was picked up from the lateral side using a ninety-degree bent artery forceps. No separate medial incision was required.

Thus the all three broken nail pieces were removed without opening the fracture site and simple instruments were used.

Now a standard ball tipped guide wire was passed and a reaming was performed. A standard 11 mm interlocking nailing was performed with two proximal and two distal screws. The nail chosen was longer than the previous nail and it was placed in such a way that both the distal locking screws were placed beyond the lateral cortical window done for removal of the broken nail tip. The post-operative check radiograph showed adequate fixation of the femur. Fig. 5.

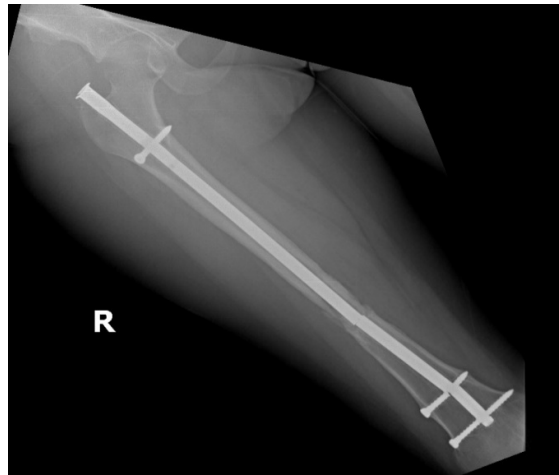


Fig. 1. The plain radiograph showing the three-part broken femoral nail with delayed union of fracture

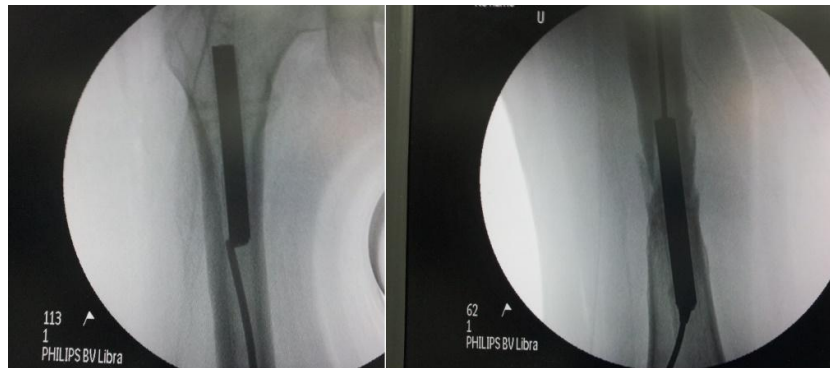


Fig. 2. The image intensifier picture showing the proximal fragment of the three-part broken femoral nail removed using the extraction jig. The middle portion of the broken nail with a guide wire passed inside from proximal end and the ball tipped guide wire in the distal portion

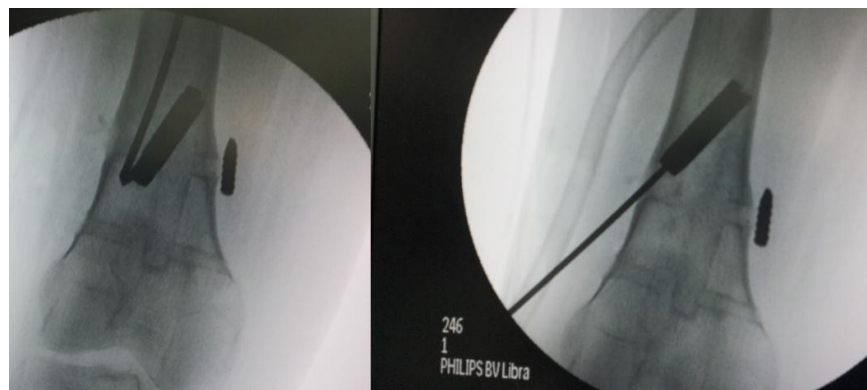


Fig. 3. The image intensifier views showing the guide wire with bent tip used to engage the broken tip of the nail, to engage and extract the nail tip to the level of proximal locking bolt. The image showing the guide wire passed from the tip of the nail and the cortical hole was widened over the guide wire at an area corresponding to the proximal locking bolt

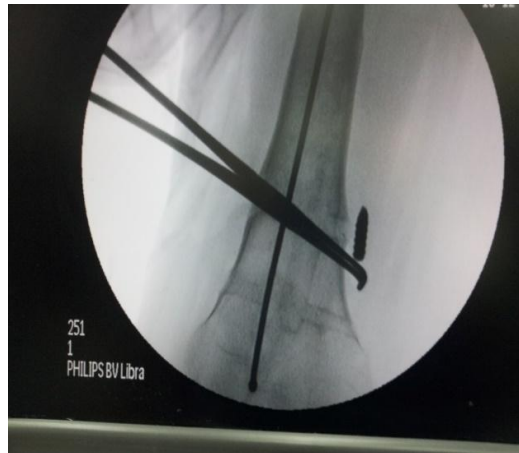


Fig. 4. C ARM image showing a bent artery forceps from lateral side to remove the medial broken tip of the screw

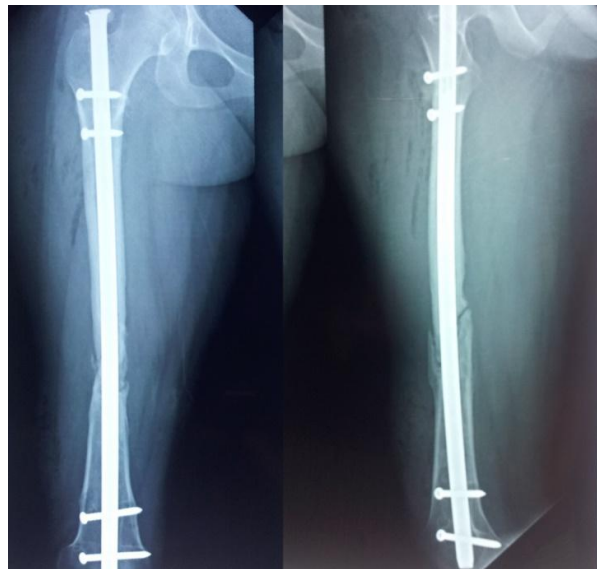


Fig. 5. Final check radiograph showing a longer nail placed such that both the distal locking bolts are beyond the cortical window

3. DISCUSSION

Numerous techniques to aid the removal of intramedullary devices have been described [3,4,5].

Middleton et al have described a technique of removal of the short distal part of the fractured nail with multiple guide wire technique, however this technique could not be used in our case as the nail was of 9 mm diameter and it was not possible to insert more than one guide wire into the nail.

Singiseti K have described use of Steinman pin for removal of the broken screw [6]. We used the same technique for removal of one of the broken distal screws. Acharya et al. [1] have described a fish hook technique for the removal of broken intramedullary femoral nail.

Blake et al. [7] have described technique of stacking the ball tipped and another guide wire in removal of the broken nail. Zhao et al. [8] have described the use of a flexible reamer to remove the distal portion of the broken femoral nail.

The cause of delayed union in our case may be because of the compound nature of the injury and using a small diameter nail.

Removal of the segmentally broken (three pieces) nail without opening the fracture site or knee have not been reported in the literature. In our novel technique we were able to remove three pieces of the broken nail without opening the fracture site or the knee.

Our technique uses only the simple instruments that are readily available for the nailing femur operative procedure. This technique does not involve any specialized instruments.

The usage of longer nail in our case makes it possible to bypass the cortical window made for removal of the nail tip. The higher diameter of the nail, stable fixation and reamed products was sufficient in our case to achieve union.

4. CONCLUSION

Ours is a rare case where interlocking nail was broken at three places. By building on the technique for removal of two part nails, we devised our own novel technique, which has not been described before.

CONSENT

As per international standard or university standard, patients' written consent has been collected and preserved by the author(s).

ETHICAL APPROVAL

As per international standard or university standard written ethical approval has been collected and preserved by the author(s).

COMPETING INTERESTS

Authors have declared that no competing interests exist.

REFERENCES

1. Acharya M, Alani A, Almedghio S. The Fish Hook Technique of extracting broken intramedullary nails. *Acta Orthop Belg.* 2008;74(5):686-8.
2. Juan PM, Juan RM, Carlos RE. Removal of a broken intramedullary femoral nail with an unusual pattern of breakage: A case report *Strategies Trauma Limb Reconstruction.* 2009;4(3):151-5.
3. Ciampolini J, Eyres KS. An aid to femoral nail removal. *Injury.* 2003;34(3):229-31.
4. Marwan M, Ibrahim M. Simple method for retrieval of distal segment of the broken locking intramedullary nail. *Injury.* 1999;30(5):333-5.
5. Middleton RG, McNab IS, Hashemi-Nejad A, Noordeen MH. Multiple guide wire technique for removal of the short distal fragment of a fractured intramedullary nail. *Injury.* 1995;26(8):531-2.
6. Singisetti K, Ashcroft GP. Novel use of Steinman pin in removal of broken interlocking screws. *Cases J.* 2008;1(1):317.
7. Blake SM. A technique for the removal of the distal part of a broken intramedullary nail. *Ann R Coll Surg Engl.* 2009;91(2):169-70.
8. Zhao C, Slater GJR. A technique for extraction of the distal segment of a broken femoral nail using a flexible reamer. *Injury.* 2017;48(8):1858-60.

© 2021 Raviraj et al.; This is an Open Access article distributed under the terms of the Creative Commons Attribution License (<http://creativecommons.org/licenses/by/4.0>), which permits unrestricted use, distribution, and reproduction in any medium, provided the original work is properly cited.

Peer-review history:
The peer review history for this paper can be accessed here:
<http://www.sdiarticle4.com/review-history/68745>