



Managing Retinoblastoma at a Tertiary Eye Hospital in Kaduna, Nigeria - A Five Year Retrospective Cohort Review

Aminatu Abdulrahman ^a, Amina Hassan ^a, Musa Danjuma ^{b*} and Mahmoud Alhassan ^c

^a Department of Paediatric Ophthalmology, National Eye Center Kaduna, Nigeria.

^b Department of Community Ophthalmology, Research and Data Management Unit, National Eye Center Kaduna, Nigeria.

^c Department of Vitreoretinal, National Eye Center Kaduna, Nigeria.

Authors' contributions

This work was carried out in collaboration among all authors. All authors read and approved the final manuscript.

Article Information

DOI: 10.9734/JAMMR/2022/v34i234867

Open Peer Review History:

This journal follows the Advanced Open Peer Review policy. Identity of the Reviewers, Editor(s) and additional Reviewers, peer review comments, different versions of the manuscript, comments of the editors, etc are available here: <https://www.sdiarticle5.com/review-history/93784>

Original Research Article

Received 18 September 2022

Accepted 21 November 2022

Published 25 November 2022

ABSTRACT

Purpose: To review the outcome of retinoblastoma management at a tertiary eye hospital in Nigeria over a five - year period since chemotherapy became available at our institution.

Methods: A retrospective review of hospital records of patients managed for retinoblastoma between January 2014 and December 2018 was done. Information on age, gender, clinical findings, treatment, duration of follow up and survival as at June 2021. The International Retinoblastoma Classification and Staging Systems were used.

Results: 120 eyes of 94 patients with RB were reviewed. Mean age at presentation was 24.1 ± 11.4 months (range 25 days - 9 years). There were 55 (58.5%) males, 68 (72.3%) had unilateral disease while 17 (18.1%) presented within the first year of life. Leucocoria and proptosis were the most common presenting signs in 53.2% and 40.4% respectively. International Retinoblastoma Stages III and IV disease were seen in 40.4% and 5.3% of patients respectively. Thirty-four patients (36.2%) received a combination of systemic chemotherapy and enucleation while 27 (28.7%) did not receive any treatment. Overall patient survival was 20% while 41% were lost to follow up as at June 2021.

Conclusion: the major challenges encountered in RB management are advanced disease at presentation, difficulties in out-of-pocket financing of treatment, poor follow up and survival. There is an urgent need for a national public screening and treatment programme for this life-threatening condition.

Keywords: Retinoblastoma; childhood; Nigeria.

1. INTRODUCTION

Retinoblastoma (RB) is a life-threatening tumour of the retina seen in young children. It is the most frequently encountered primary intraocular cancer [1], and accounts for 3-5% of all childhood cancers [2,3]. Of the estimated 9,000 new cases occurring worldwide every year, 9-in-10 occur in middle- and low- income countries [4,5]. In Nigeria, a conservative estimate of 339 new cases occur annually [6] constituting a third of all head and neck tumours in children [7].

Managing RB (and other malignancies) in developing countries is challenging due to a complex interplay of multiple factors such as lack of awareness, poor access to health care, delayed diagnosis, inadequate treatment facilities, financial constraints, socio-cultural factors etc [5,6,8,9] These culminate in late presentation with advanced disease, resulting in survival rates of between 23% to 70% [10–12] compared to >90% in more advanced nations [13,14].

Since RB was first described in 1657, it has become a yardstick for many advances in the field of oncology [15]. Various treatment options have evolved over time: enucleation (1900s), external beam radiation (1920s), photocoagulation (1950s), cryotherapy (1970s), chemo-reduction (1990s), and chemo-reduction/consolidation (2000s) [16]. Over the course of a century the prognosis has changed from almost 100% mortality to almost 100% survival in developed countries; with preservation of globe, vision and quality of life. This has become possible due to the expansion of knowledge, treatment options, creation of dedicated treatment centres and linkages between all the tiers of healthcare provision [15]. Conversely, the paucity of all these contribute to the morbidity and mortality seen in developing countries [17].

National Eye Centre Kaduna in North-West Nigeria is the largest government-owned tertiary eye hospital in Nigeria which receives referrals

from all over the country. Previously, RB services were limited to excisional biopsies (via enucleation or exenteration) for histological confirmation of the disease; before referring patients to multi-disciplinary teaching hospitals for further treatment. Many children died shortly afterwards or were lost to follow up. In 2103, we commenced administration of primary chemotherapy in addition to enucleation with orbital implants, and cosmetic rehabilitation. In 2016 we set up a dedicated RB clinic and team comprising a visiting oncologist, paediatric ophthalmologists, oculoplasty surgeons, ophthalmic nurses, counsellor and an ocularist. Patients requiring external beam radiotherapy, bone marrow biopsies or palliation for disseminated disease are referred to other multi-disciplinary centres with the requisite resources. The aim of this study was to review the outcome of the patients managed for retinoblastoma at NECK over a five – year period since chemotherapy became available at the institution.

2. METHODS

This was a retrospective case series of children aged 0 to 16 years who were managed for RB at National Eye Centre Kaduna, Nigeria from January 2014 to December 2018. A manual search of registers was conducted in the outpatient clinics, ward and theatre for all patients diagnosed and managed for RB. Hospital files were retrieved and the following information extracted: age, gender, presenting signs and stage of disease, laterality, treatment (systemic chemotherapy, surgery, radiotherapy), histopathology results, and duration of follow up as at June 2021. Care givers were contacted by telephone to ascertain if child was alive and well.

All patients had history, complete physical examination, B-mode ocular ultrasound scan and full blood count in the outpatient clinic before dilated ophthalmic examination of both eyes under general anaesthesia. This entailed anterior segment examination with an operating microscope, and binocular indirect ophthalmoscopy of the posterior segment with

scleral indentation using a 20-dioptre condensing lens. Magnetic resonance imaging (MRI) of the orbits and brain was done by those patients who could afford it while a few referred cases came with a computerized tomographic (CT) scan. Subjects were classified using the International Intraocular Retinoblastoma Classification (IIRC), and the International Retinoblastoma Staging System (IRSS) for intra- and extra-ocular disease respectively [18]. Treatment for each patient was commenced according to our institutional protocol.

Patients with Group A, B, C and D tumours received 6 cycles of systemic standard dose chemotherapy (SDC) comprised of carboplatin, etoposide and vincristine, with enucleation of groups C and D eyes after the third cycle. Those with Group E and Stage III disease received high dose chemotherapy (HDC) of 6 and 12 cycles respectively, with enucleation after the fourth cycle. Based on histopathologic report of enucleation specimens, the number of cycles for Group E was increased to 12 for those with tumour at surgical margin (TSM) plus referral for radiotherapy. TSM was the only high-risk characteristic reported by the general pathologist who examined the specimens. Stage III disease were referred for radiotherapy after 12 cycles of HDC; while Stage IV patients were referred to a multi-disciplinary centre for palliation ab initio. The application of this protocol depended on patients' ability to finance the different aspects of treatment.

Data analysis: was done using Statistical Package for Social Sciences (SPSS) version 20 (IBM Corp: Armonk, NY, USA). Summary statistics, percentages and proportions were generated.

3. RESULTS

This review included 120 eyes of 94 patients. Mean age at presentation was 24.1 ± 11.4 months (range 25 days - 9 years). There were 55 males and 39 females (sex ratio of 1.4:1). Sixty-eight patients (72.3%) had unilateral disease while 17 (18.1%) presented within the first year of life (Table 1). Leucocoria was the most common presenting sign in 53.2% followed by proptosis in 40.4% (Table 2). Stages III and IV disease (extraocular) were seen in 40.4% and 5.3% of patients respectively while the rest presented with intraocular disease (Table 2). Thirty-four patients received a combination of systemic chemotherapy and enucleation while 27

(28.7%) did not receive any treatment. Twenty-five (26.6%) completed at least 6 cycles of chemotherapy, 36 eyes of 35 patients were enucleated while 70 eyes were too advanced for surgical intervention. Overall, 39% died, 41% were lost to follow up and 20% were alive as at June 2021.

4. DISCUSSION

In this retrospective case series the mean age at presentation was 24 months, which is similar to reports from Nigeria and other developing countries where majority present in the third year of life [19–22]. This is older than age of presentation in developed countries and could be attributed to economic disparities between different regions of the world. These translate to differential access to healthcare, education and economic opportunities that are important determinants of health [17].

We recorded a male preponderance even though RB has no particular sex predilection. Many authors have documented greater numbers of boys than girls and this may be a reflection of inequities in accessing health services within and between countries. In Lagos, Nigeria¹⁹ and Pakistan [21] there were more girls than boys in their series though the authors did not discuss possible reasons for this.

Around three quarters of our patients presented with unilateral disease while 28% with bilateral disease which is in keeping with reports from different parts of the world [8]. Because we have limited facilities for genetic testing, we hypothesize that most of our patients have sporadic disease because the high mortality rate in developing countries is not in favour of transmission of the genetic mutation to offspring. In our setting many parents seek both orthodox and unorthodox treatments (including waiting to see if the child grows out of the problem). It is usually a worsening of the leukocoria or progression to proptosis that brings them to the tertiary hospital where a definitive diagnosis of RB is made. More than half of our study subjects presented with leukocoria and intraocular stage of disease while 40% presented with orbital disease. This is similar to findings in Lagos [19] but contrary to reports from Kano (Nigeria) [9], Sudan [11], Zambia [12] where extraocular disease was the main presentation. Some of the reasons could be: (i) NECK receives referrals from all over Nigeria particularly the Northern states which have a large population (ii) Being a

government –owned tertiary eye hospital our services are relatively cheap, and we provided waivers for consultation, accommodation, anaesthesia and surgery fees for this life-threatening condition. It is possible that this generated awareness and encouraged earlier presentation.

Outcome of treatment was varied: 39% died, 41% lost to follow up and 20% were alive as at June 2021. Those confirmed dead had advanced disease at presentation and received only palliative treatment with blood transfusion and systemic antibiotics because they could not withstand chemotherapy; as well as those who could not complete the recommended chemotherapy cycles or radiotherapy for advanced orbital disease. Those lost to follow up (41%) comprised those who did not receive any treatment (28.7%) or could not complete the desired number of chemotherapy cycles. Despite the multiple waivers, many poor patients could

not afford the cost of chemotherapy drugs, repeated haemograms, brain imaging as well as the indirect costs associated with each hospital visit (transportation, feeding, lost wages for accompanying adults, etc). We can only hypothesize that some died either of the disease or some other cause; while others may have been cured and did not see the need to return. It is also possible that they decided to seek treatment elsewhere. These challenges of poor follow up and financing treatment have been reported from other researchers – 39% from Lagos and parts of Nigeria and many developing countries and is a reflection of health system weaknesses. The 19 patients (20%) who were alive and still coming for follow up are those who had enucleation and at least 6 cycles of chemotherapy. This is much lower than 89.6% reported from a private tertiary eye hospital in India [22] which had all the required facilities under one roof.

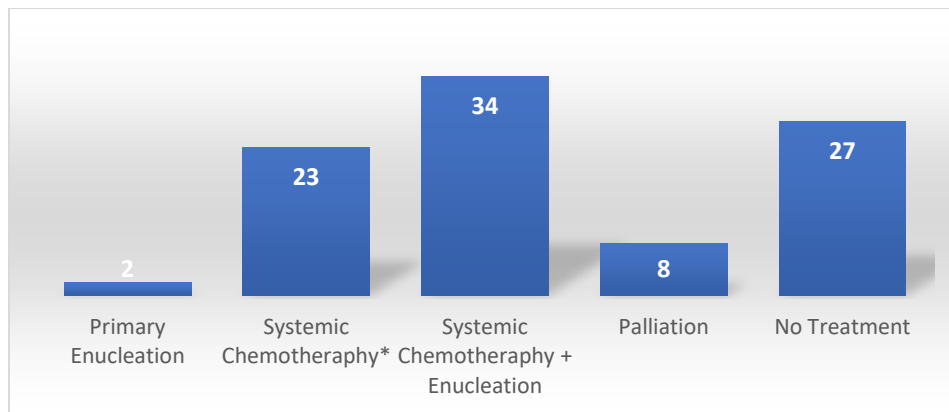


Fig. 1. Modalities of treatment administered
*Combination of vincristine, etoposide and carboplatin

Table 1. Distribution of age, sex and laterality of disease (n=94)

Age (months)	Sex		Laterality	
	Male	Female	Unilateral	Bilateral
0-12	10	7	11	6
13-24	16	11	19	8
25-36	18	7	18	7
37-48	6	5	9	2
49-60	3	2	4	1
>60	2	7	7	2

Table 2. Signs & stage of disease at presentation

Presenting sign	Frequency (%)	Stage of disease	Frequency (%)
Leucocoria	50 (53.2%)	Intraocular	51 (54.3%)
Proptosis	38 (40.4%)	Stage III	38 (40.4%)
Squint/Other	6 (6.4%)	Stage IV	5 (5.3%)

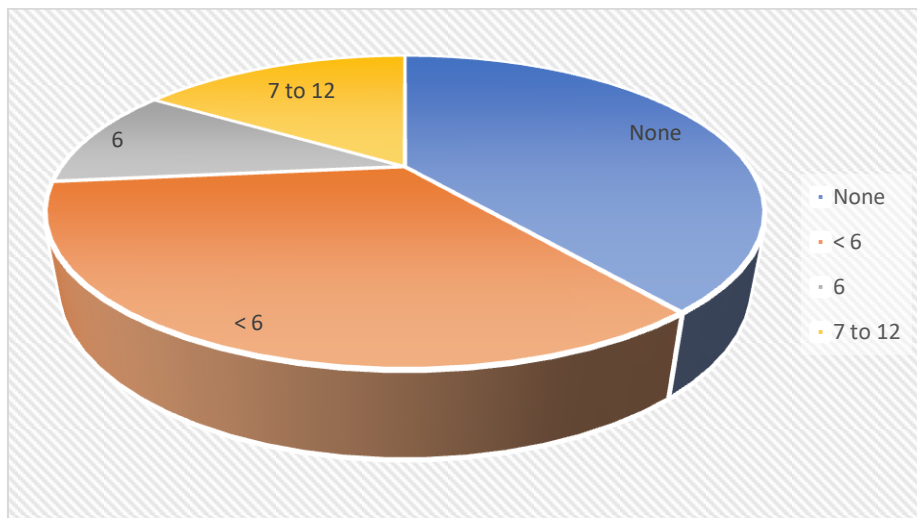


Fig. 2. Proportion of subjects who received systemic chemotherapy

Enucleation: 33/36 enucleated eyes (92%) had tumour at the optic nerve surgical margin (TSM) implying that there was residual tumour in the orbit which required radiotherapy for effective control. None of our patients received radiotherapy due to non-functionality of the machines at the few centres that had them; as well as the prohibitive cost. Also, because TSM was the only high-risk characteristic (HRC) reported by the general pathologist it is possible that choroidal invasion, anterior segment involvement was missed resulting in relapse or recurrent disease. Radiotherapy and quality histopathologic reporting are crucial for postoperative counselling and management; lack of which necessitated extending the chemotherapy to 12 cycles for 16% of our patients. The lack of ophthalmic pathologist has been reported from Sudan [8] but this does not seem to be the case in India and Pakistan.

Though three quarters of our subjects presented with unilateral disease which is potentially curable by enucleation, only 2.1% consented to primary enucleation compared to 75.7% in SW China [23] and 60.4% in India [22]. We offered systemic chemotherapy as first line treatment for three reasons: (i) To get the parents to commit to treatment because obtaining parental consent for primary enucleation is difficult and may lead to abscondment; and re-presentation with orbital or distant metastasis later on. Many parents were more receptive to chemotherapy and subsequent enucleation when the eye had shrunk (ii) to achieve chemoreduction in those with orbital disease before attempting enucleation (iii) to take

care of micro-metastases at the time of presentation.

A limitation of this study is that being a retrospective hospital-based study it cannot be extrapolated to the general population. Some information was incomplete such as ascertainment of survival/death for those who were LTFU due to lack of functioning telephone number. Follow up period was short especially for those enrolled in the last 2 years of the study which might reveal important information. Lack of imaging and radiotherapy facilities under one roof, poor financing mechanism for treatment encouraged loss to follow up. A strength is that we mobilized the resources available to us under one roof to establish a team, provide subsidized services, and establish a baseline which will serve as a baseline for future studies and reduce fragmentation of care.

Implications of findings for patients is that we are seeing them too late to save their lives. About half presented with extraocular disease which is a late stage that requires more resources to treat with poorer prognosis. Intraocular unilateral RB is potentially curable by primary enucleation which may be more appropriate for resource-constrained settings. The availability of an ophthalmologist to provide good cosmetic rehabilitation can improve acceptance of enucleation and the quality of life for both child and parents/caregivers. Follow up is a crucial aspect of management and parents/caregivers need to collaborate with providers in providing feedback in order to aid documentation and research for better management. For providers: RB is a

priority for us in NEC due to the increasing awareness among the general population. Our subsidies have helped many patients but are still not enough to save many. We need to invest in finding children in infancy and getting them into the care system. COVID-19 has expanded opportunities for utilizing technology for collaboration within and outside Nigeria eg virtual tumour board meetings. We need to explore the option of twinning between institutions (nationally and internationally), and conduct quality research. Also, the availability of a searchable database of paediatric eye care service providers and a toll-free number for linking children with providers are opportunities for finding patients early and instituting treatment.

For policy makers, there should be greater commitment of resources to mitigate catastrophic health spending for parents of these children. NEC is willing and able to be a Centre of Excellence in RB management if we can get support from government for health education, screening programs, financing care, training/retraining/retaining of healthcare workers. There is need for development of national guidelines for management of RB.

5. CONCLUSION

The major challenges of RB management at our institution are advanced disease at presentation, difficulties in out-of-pocket financing of treatment, poor follow up, poor survival and resistance to primary enucleation. However, we have succeeded in creating a multi-disciplinary team that provides many services under one roof which we aim to improve upon. There is an urgent need for a public screening and treatment programme for this life-threatening condition.

CONSENT

It's not applicable.

ETHICAL APPROVAL

Ethical approval was obtained from the Research Ethics Committee of National Eye Centre Kaduna.

COMPETING INTERESTS

Authors have declared that no competing interests exist.

REFERENCES

1. Kivelä T. The epidemiological challenge of the most frequent eye cancer: Retinoblastoma, an issue of birth and death. *Br J Ophthalmol.* 2009;93(9):1129-1131. DOI:10.1136/bjo.2008.150292
2. Yun J, Li Y, Xu CT, Pan BR. Epidemiology and Rb1 gene of retinoblastoma. *Int J Ophthalmol.* 2011;4(1):103-109. DOI:10.3980/j.issn.2222-3959.2011.01.24
3. Dimaras H, Kimani K, Dimba EAO, et al. Retinoblastoma. In: *The Lancet.* Lancet Publishing Group. 2012;379:1436-1446. DOI:10.1016/S0140-6736(11)61137-9
4. Dimaras H, Corson TW, Cobrinik D, et al. Retinoblastoma. *Nat Rev Dis Prim.* 2015;1. DOI:10.1038/nrdp.2015.21
5. Jain M, Rojanaporn D, Chawla B, Sundar G, Gopal L, Khetan V. Retinoblastoma in Asia. *Eye.* 2019;33(1):87-96. DOI:10.1038/s41433-018-0244-7
6. Ademola-Popoola DS, Opocher ERM. Contemporary management of retinoblastoma in the context of a low-resource country. *Niger Postgr Med J.* 2019;26:69-79.
7. Ochicha O, Gwarzo AK, Gwarzo D. Pediatric malignancies in Kano, Northern Nigeria. *World J Pediatr.* 2012;8(3):235-239. DOI:10.1007/s12519-012-0363-3
8. Fabian ID, Abdallah E, Abdullahi SU, et al. Global Retinoblastoma Presentation and Analysis by National Income Level. *JAMA Oncol;* 2020. DOI:10.1001/jamaoncol.2019.6716
9. Abdu L, Malami S. Clinicopathological pattern and management of retinoblastoma in Kano, Nigeria. *Ann Afr Med.* 2011;10(3):214-219. DOI:10.4103/1596-3519.84705
10. Canturk S, Qaddoumi I, Khetan V, Ma Z, Furmanchuk A, Antoneli CBG, Sultan I, Kebudi R, Sharma T, Rodriguez-Galindo C, Abramson DH. Survival of retinoblastoma in less-developed countries impact of socioeconomic and health-related indicators. *British Journal of Ophthalmology.* 2010;94(11):1432-1436. DOI:10.1136/bjo.2009.168062
11. Ali AAE, Elsheikh SMA, Elhaj A, et al. Clinical presentation and outcome of retinoblastoma among children treated at the National Cancer Institute (NCI) in Gezira, Sudan: A single institution

- experience. *Ophthalmic Genet.* 2011; 32(2):122-125.
DOI:10.3109/13816810.2010.546822
12. Nyaywa M, Chintu C. Modes of presentation, management and outcome of retinoblastoma treatment at University Teaching Hospital. *Med J Zambia.* 2016; 43(4):216-223.
DOI:10.4314/mjz.v43i4
13. Nummi K, Kivelä TT. Retinoblastoma in Finland, 1964-2014: incidence and survival. *Br J Ophthalmol*; 2020.
DOI:10.1136/bjophthalmol-2019-315744
14. Ueda T, Koga Y, Yoshikawa H, et al. Survival and ocular preservation in a long-term cohort of Japanese patients with retinoblastoma. *BMC Pediatr.* 2020;20(1).
DOI:10.1186/s12887-020-1923-7
15. Fabian ID, Onadim Z, Karaa E, et al. The management of retinoblastoma. *Oncogene.* 2018;37(12):1551-1560.
DOI:10.1038/s41388-017-0050-x
16. Grossniklaus HE, Retinoblastoma. Fifty years of progress the LXXI Edward Jackson memorial lecture. *Am J Ophthalmol.* 2014;158(5):875-891.e1.
DOI:10.1016/j.ajo.2014.07.025
17. Dimaras H, Dimba EAO, Gallie BL, Dimaras H, Dimba EAO, Gallie BL. Challenging the global retinoblastoma survival disparity through a collaborative research effort; 2010.
DOI:10.1136/bjo.2009.174136
18. Fabian ID, Reddy A, Sagoo MS. Classification and staging of retinoblastoma. *Community Eye Health.* 2018;31(101):11-13.
19. Musa KO, Aribaba OT, Oluleye TS. Challenges of retinoblastoma management in a Nigerian tertiary eye care facility; 2017.
DOI:10.4103/jcls.jcls
20. Dial C, Doh K, Thiam I, Roth PAN, Moreira C, Woto-Gaye G. Retinoblastoma in children: A case series from Senegal. *Oxford Med Case Reports.* 2019; 2019(10):1DUMMN.
DOI:10.1093/omcr/omz084
21. Zia N, Hamid A, Iftikhar S, Qadri MH, Jangda A, Khan MR. Retinoblastoma presentation and survival: A four-year analysis from a tertiary care hospital. *Pakistan J Med Sci.* 2020;36 (January):S61-S66.
DOI:10.12669/pjms.36.ICON-Suppl.1720
22. Shah PK, Narendran V, Kalpana N. Outcomes of Intra- and Extraocular Retinoblastomas from a single institute in South India. *Ophthalmic Genet.* 2015; 36(3):248-250.
DOI:10.3109/13816810.2013.867450
23. Gao J, Zeng J, Guo B, et al. Clinical presentation and treatment outcome of retinoblastoma in children of South Western China. *Med (United States).* 2016;95(42).
DOI:10.1097/MD.0000000000005204

© 2022 Abdulrahman et al.; This is an Open Access article distributed under the terms of the Creative Commons Attribution License (<http://creativecommons.org/licenses/by/4.0>), which permits unrestricted use, distribution, and reproduction in any medium, provided the original work is properly cited.

Peer-review history:

The peer review history for this paper can be accessed here:
<https://www.sdiarticle5.com/review-history/93784>