

An Unusual Association of Hyper-IgE Syndrome with Celiac Disease: A Case Report

Ghita Hachim ^{a*}, Jihane El Mahi ^a, Abdelilah Radi ^a, Abdelhakim Ourrai ^a, Rachid Abilkassem ^a, Amal Hassani ^a and Aomar Agadr ^a

^a Department of Pediatrics, Mohammed V Military Instruction Hospital, Rabat, Morocco.

Authors' contributions

This work was carried out in collaboration among all authors. All authors read and approved the final manuscript.

Article Information

DOI: 10.9734/JAMPS/2022/v24i9575

Open Peer Review History:

This journal follows the Advanced Open Peer Review policy. Identity of the Reviewers, Editor(s) and additional Reviewers, peer review comments, different versions of the manuscript, comments of the editors, etc are available here: <https://www.sdiarticle5.com/review-history/92683>

Received 15 August 2022

Accepted 19 October 2022

Published 25 October 2022

Case Report

ABSTRACT

Hyper-IgE syndrome (HIES) is a primary immunodeficiency disorder characterized by eczema, cold abscesses, pneumonia, eosinophilia, and a very high serum IgE concentration. An association with celiac disease is rare. Immunodeficiency and autoimmunity are two manifestations of immune system dysfunction that can be associated with common pathophysiological links. We present the case of a 3-year-old child with psychomotor retardation and a history of recurrent infections who had generalized eczema, failure to thrive, and abdominal distension with hepatosplenomegaly. The patient improved after receiving a monthly intravenous immunoglobulin infusion and a gluten-free diet.

Keywords: HyperIgE syndrome; celiac disease; immune deficiency; infection.

1. INTRODUCTION

The hyperIgE syndrome, or Job's syndrome, was first described in 1966 by Davis [1]. It is characterized by the association of severe and recurrent infections of the skin (cold abscesses) and the sinopulmonary tract

(primarily staphylococcal), as well as chronic eczematous dermatitis. This clinical triad is associated with biological signs such as hyperimmunoglobulinemia E (>2000 IU/mL) with normal serum levels of other immunoglobulins and moderate eosinophilia [2,3].

*Corresponding author: E-mail: ghita717@gmail.com;

In this study, we present a rare case of a child with hyperIgE syndrome and celiac disease.

2. CASE OBSERVATION

A 3-year-old female patient, of non-consanguineous parents, with a history of neonatal eczema that appeared at 7 days of age and repeated infections (post-vaccination thigh abscess and sub-lingual abscess at the age of 2 months; 2 episodes of pneumopathy requiring intravenous antibiotic therapy occurring at the ages of 5 months and 7 months, respectively) with chronic glairy diarrhea). Admitted for respiratory distress and in whom clinical examination reveals a child with a dysmorphic face (forehead prominence, hypertelorism, increased interalar distance), a failure to thrive at a weight of 10 kg (-2DS) and a height of 80 cm (-3DS). She was malnourished with spindly limbs, polypneic at 50 cycles/min with bilateral sibilant rales on auscultation, pale, febrile at 38°C, with generalized eczema, and hepatosplenomegaly. (Figs. 1-2).

A chest X-ray was normal (Fig. 3).

A complete blood count (CBC) revealed a hypereosinophilia of 1900 elements/mm³, bicytopenia with hypochromic microcytic anemia (hemoglobin 6.1 g/dl, MCV 66.2 μ³, MCHC 31.2 g/dl), and thrombocytopenia of 80,000 elements/mm³.

CRP was 23.2 mg/L, with ferritin at 8 mg/L. The IgA and IgE levels were 4.4 U/ml and 7407 U/ml, respectively. The bone marrow aspiration was normal.

Viral serologies were performed showing cytomegalovirus (CMV) infection with positive IgM and IgG antibodies and PCR. Anti-transglutaminase IgA antibodies were positive at 38 U/mL. An esophagogastroduodenoscopy was performed with a jejunal biopsy revealing stage IIIa villous atrophy.

Abdominal ultrasound revealed homogeneous hepatomegaly of 11 cm and splenomegaly of 9.5 cm. The echocardiography was normal.

A blood transfusion was administered, as well as ganciclovir IV, a gluten-free diet, salbutamol nebulization, and cotrimoxazole prophylaxis.

The evolution was marked by the appearance of a pre-septal orbital cellulitis of the left eye with sinusitis (Fig.4).

The child was given amoxicillin and clavulanic acid IV for 10 days and responded well to treatment.

This child's clinical condition improved significantly after receiving a monthly intravenous infusion of immunoglobulin.

3. DISCUSSION

HyperIgE syndrome is a rare primary immunodeficiency disorder with an incidence of around 1/1,000,000 annually. Although it was first observed in females, the syndrome affects males and females equally, regardless of ethnicity. Familial character has been rarely described [2,3]. The first symptoms appear during the first weeks of life, but they can appear later in adolescence or adulthood [4,5]. This syndrome has specific clinical features.

Morphologically, the manifestations are mainly facial with facial asymmetry, hemihypertrophy, increased interalar distance, and a prominent forehead [6-8], as reported in our case. They develop early in childhood.

HIES is distinguished from many other primary immunodeficiencies by the presence of extra-immunological features, including osteopenia, hyperextensibility, scoliosis, degenerative joint disease, and vascular anomalies such as stenosis and aneurysm formation.

Dermatologically, this syndrome typically manifests in the newborn with a rash during the first few weeks of life. This pustular rash on the face and scalp could be caused by neonatal acne or eosinophilic dermatitis [9,10].

Recurrent staphylococcal skin boils and bacterial pneumonia are most common in childhood.

Pneumatocoles and bronchiectasis are common complications of aberrant healing of pneumonia, and they are major causes of morbidity and mortality.

The bacterial species involved are *Staphylococcus aureus* in 60% of cases, *Hemophilus influenzae* in 10% of cases, and, rarely, *Streptococcus pneumoniae*, *Cryptococcus neoformans*, *Aspergillus fumigatus*, and chronic candidal infections, mainly related to *Candida albicans*, both in the skin and in the oropharynx, are also frequently reported in this syndrome [11,12].

Biologically, there is hyperimmunoglobulinemia E (>2000 IU/mL) associated with normal serum levels of other immunoglobulins and moderate eosinophilia.

The majority of cases are sporadic; however, two types of HIES have been reported: the autosomal dominant form (AD-HIES) and the autosomal recessive form (AR-HIES).

Autosomal dominant hyper-IgE syndrome (AD-HIES) is characterized by eczema, recurrent skin and lung infections, elevated serum IgE, and various connective tissue, skeletal, and vascular abnormalities, and is caused by mutation of the signal transducer and activator of transcription 3 (STAT3) gene [13,14].

A distinct syndrome known as autosomal recessive HIES (AR-HIES) due to mutations in

DOCK8 manifests as severe eczema, recurrent bacterial skin infections with particular susceptibility to viral infections by herpes simplex, herpes zoster, and Molluscum contagiosum associated with autoimmunity and allergic manifestations [14].

In contrast to STAT3-deficient HIES, AR-HIES lacks connective tissue and skeletal manifestations, but has increased neurological abnormalities [15].

In our patient's case, we can say that it is a recessive type due to the absence of a similar case in the family, the presence of allergic manifestations such as eczema, and the association with an autoimmune disease such as celiac disease. However, due to a lack of funds, the genetic study could not be carried out [16,17].

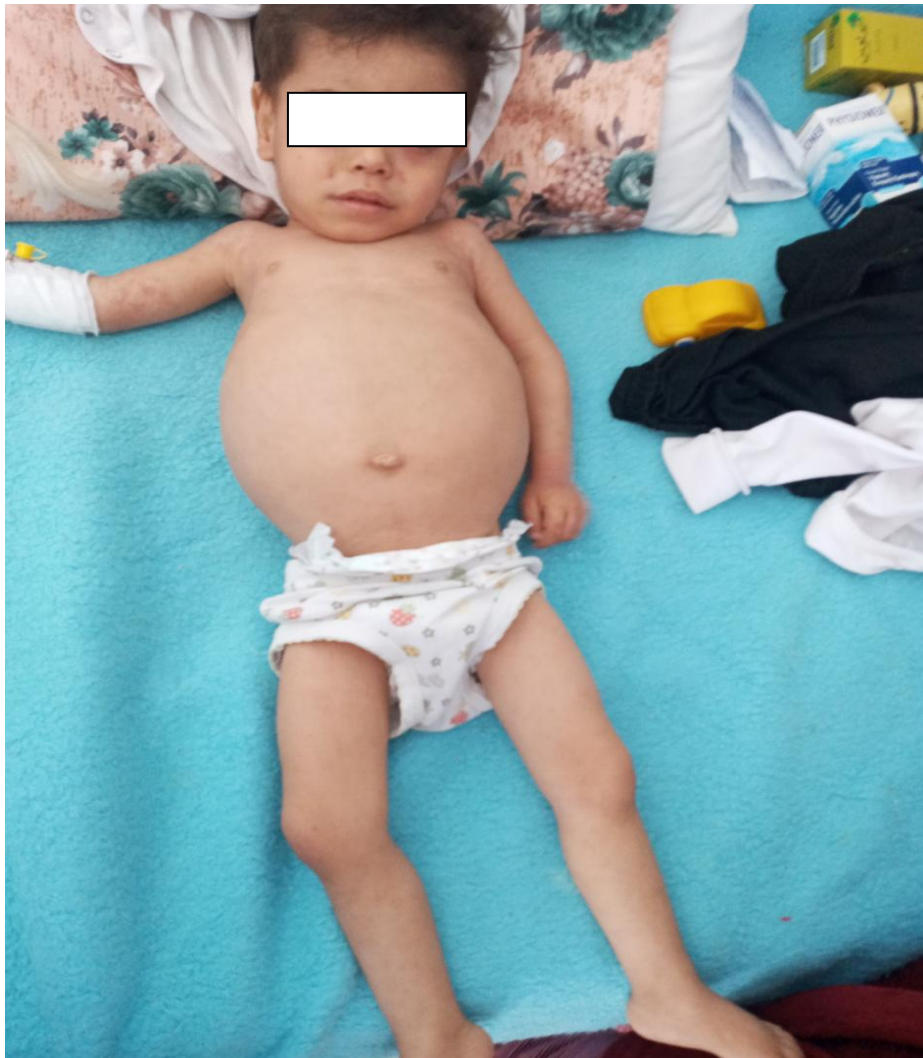

Fig. 1. Image of the child with hyperIgE syndrome

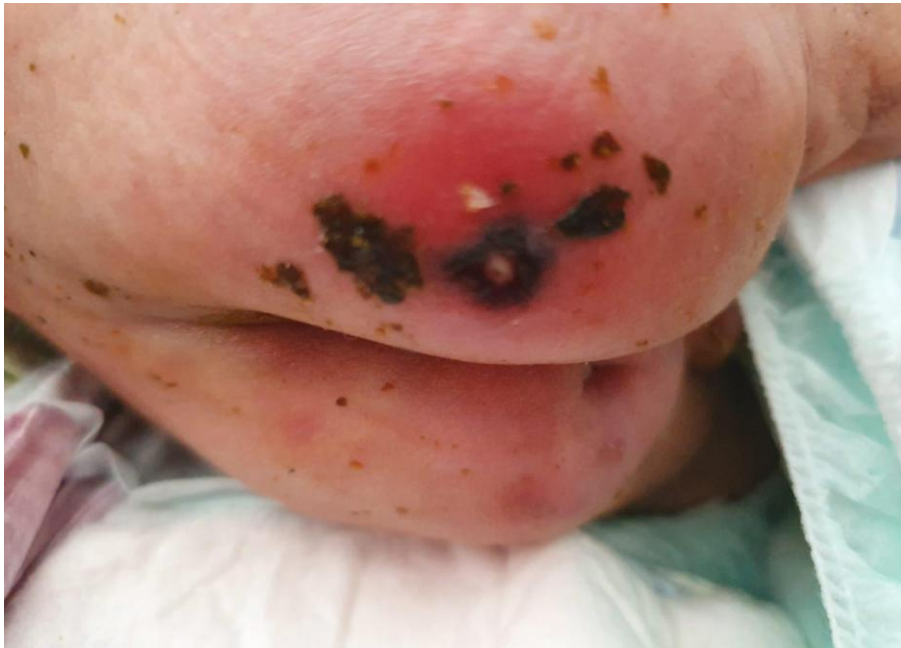

Fig. 2. Image of a gluteal abscess

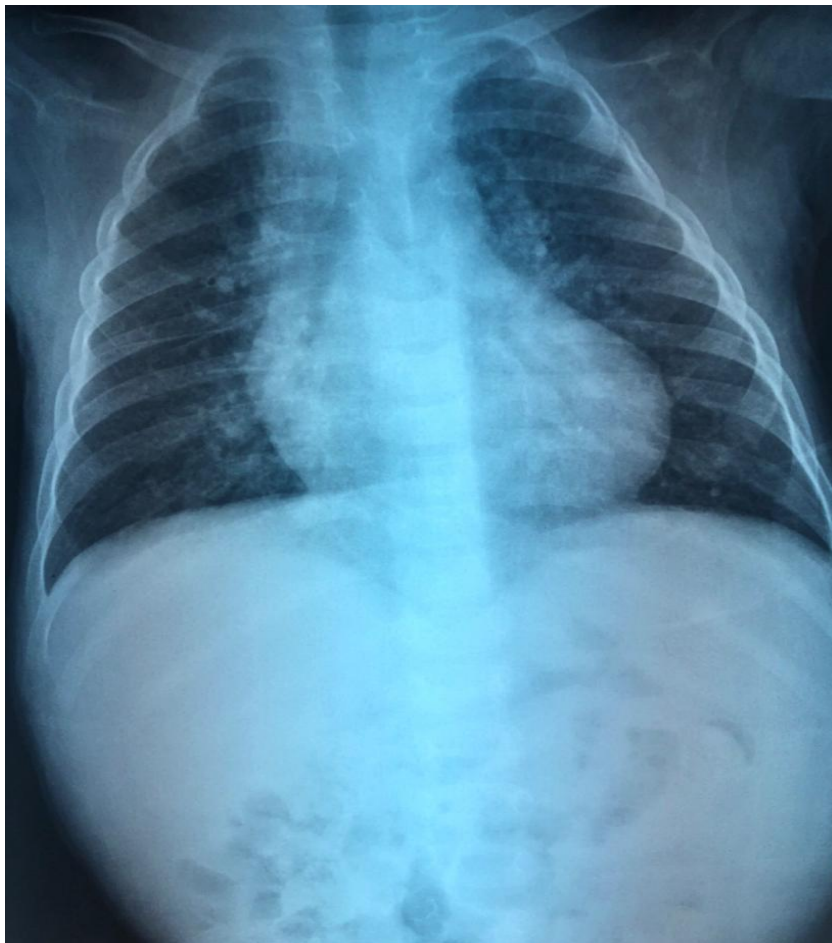

Fig. 3. Chest X-ray of the child

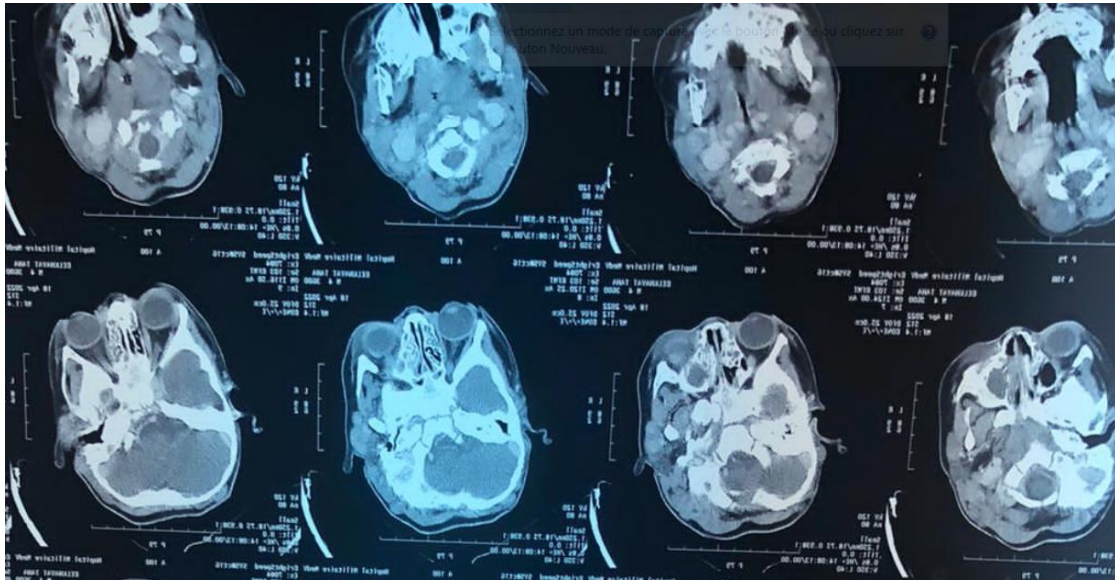


Fig. 4. Cerebral-orbital CT scan with contrast injection showing pre-septal orbital cellulitis with sinusitis

Celiac disease is a chronic enteropathy with villous atrophy secondary to an inappropriate immune response of the intestinal mucosa to gliadin from wheat, barley, and rye in genetically predisposed individuals (HLA DQ2 and/or DQ8 haplotypes). It may be associated with other autoimmune diseases, including type 1 diabetes and autoimmune thyroiditis [18,19].

The presence of IgA-type anti-transglutaminase antibodies at less than 10 times normal in conjunction with stage IIIa villous atrophy retained our patient's celiac disease diagnosis. However, celiac disease was linked to an immune deficit called "job buckley syndrome" rather than an autoimmune disease in this case [20-22].

4. CONCLUSION

The described case demonstrates the distinct clinical features of hyperimmunoglobulinemia E syndrome, which are early diagnostic features of this syndrome. His association is still uncommon.

CONSENT

As per international standard, parental written consent has been collected and preserved by the author(s).

ETHICAL APPROVAL

As per international standard or university standard written ethical approval has been collected and preserved by the author(s).

COMPETING INTERESTS

Authors have declared that no competing interests exist.

REFERENCES

1. Davis SD, Schaller J, Wedgwood RJ. Job's syndrome: Recurrent, "cold", staphylococcal abscesses. *Lancet* 1966; 1(7445):1013-5.
2. Van Scoy RE, Hill HR, Ritts RE, Quie PG. Familial neutrophil chemotaxis defect, recurrent bacterial infections, mucocutaneous candidiasis, and hyperimmunoglobulinemia E. *Ann Intern Med.* 1975;82(6):766-71.
3. Blum R, Geller G, Fish LA. Recurrent severe staphylococcal infections, eczematoid rash, extreme elevations of IgE, eosinophilia, and divergent chemotactic responses in two generations. *J Pediatr.* 1977;90(4):607-9.
4. L'Huillier JP, Thoreux PH, Delaval P, Desrues B, Le Gall E, Kerneec J, et al. The hyperimmunoglobulinaemia E and recurrent infections syndrome in an adult. *Thorax.* 1990;45(9):707-8.
5. Chamlin SL, McCalmont TH, Cunningham BB, Esterly NB, Lai CH, Mallory SB, et al. Cutaneous manifestations of Hyper-IgE syndrome in infants and children. *J Pediatr.* 2002;141(4):572-5.
6. DeWitt CA, Bishop AB, Buecher LS, Stone SP. Hyperimmunoglobulin E syndrome:

- Two cases and a review of literature. *J Am Acad Dermatol.* 2006;54(5):855-65.
7. Buckley RH. The Hyper-IgE syndrome. *Clin Rev Allergy Immunol.* 2001;20(1):139-54.
 8. Borges WG, Hensley T, Carey JC, Petrak BA, Hill HR. The face of job. *J Pediatr.* 1998;133(2):303-5.
 9. Chamlin SL, McCalmont TH, Cunningham BB, Esterly NB, Lai CH, Mallory SB, Mancini AJ, Tamburro J, Frieden IJ. Cutaneous manifestations of Hyper-IgE syndrome in infants and children. *J Pediatr.* 2002;141:572-575.
 10. Eberling CL, Davis J, Puck JM, Holland SM. Dermatitis and the newborn rash of Hyper-IgE syndrome. *Arch Dermatol.* 2004;140:1119-1125.
 11. Sepet E, Ozdemir D, Aksakalli N, Külekçig G. Hyper-IgE syndrome: A case report. *J Clin Pediatr Dent.* 2001;25(4):333-6.
 12. Kamasaki Y, Hidaka K, Nishiguchi M, Fujiwara T. Dental manifestations of a pediatric patient with hyperimmunoglobulin E syndrome: A case report. *J Dent Child (Chic).* 2012;79(2):100-4.
 13. Minegishi Y. Hyper-IgE syndrome. *Allergology International.* 2021;70(4):407-414.
 14. Hafsi W, Yarrarapu SNS. Job Syndrome. In: *StatPearls [Internet]. Treasure Island (FL): StatPearls Publishing; 2022. PMID: 30247822.*
 15. Engelhardt, Karin R, et al. "Large deletions and point mutations involving the dedicator of cytokinesis 8 (DOCK8) in the autosomal-recessive form of Hyper-IgE syndrome." *Journal of Allergy and Clinical Immunology.* (2009);124(6):1289-1302.
 16. Freeman AF, Holland SM. Clinical manifestations, etiology, and pathogenesis of the Hyper-IgE syndromes. *Pediatric Research.* 2009;65(7):32-37.
 17. Liza M, Gaurav D, Prasenjeet M, Swapna J, Binodini B. Autosomal-recessive Hyper-IgE syndrome. *Indian J Dermatol.* 2018; 63(1):79-81.
 18. Caproni M, Bonciolini V, D'Errico A, Antiga E, Fabbri P. Celiac disease and dermatologic manifestations: Many skin clue to unfold gluten-sensitive enteropathy. *Gastroenterology Research and Practice;* 2012.
 19. Pastore L, Carroccio A, Compilato D, Panzarella V, Serpico R, Muzio LL. Oral manifestations of celiac disease. *Journal of Clinical Gastroenterology.* 2008;42(3):224-32.
 20. He YY, Liu B, Xiao XP. [Hyper-IgE syndromes]. *Lin Chung Er Bi Yan Hou Tou Jing Wai Ke Za Zhi.* 2017;31(11):892-896.
 21. Glissen Brown JR, Singh P. Coeliac disease. *Paediatr Int Child Health.* 2019; 39(1):23-31.
 22. Al-Toma A, Volta U, Auricchio R, Castillejo G, Sanders DS, Cellier C, Mulder CJ, Lundin KEA. European Society for the study of Coeliac Disease (ESsCD) guideline for coeliac disease and other gluten-related disorders. *United European Gastroenterol J.* 2019;7(5):583-613.

© 2022 Hachim et al.; This is an Open Access article distributed under the terms of the Creative Commons Attribution License (<http://creativecommons.org/licenses/by/4.0>), which permits unrestricted use, distribution, and reproduction in any medium, provided the original work is properly cited.

Peer-review history:

The peer review history for this paper can be accessed here:

<https://www.sdiarticle5.com/review-history/92683>