

Congenital Heart Malformations in Iraq, a Review

Luma Ibrahim Khalel Al-Allaf ^{a*} and Rawa Younis Mahmmod ^{b#}

^a Department of Anatomy, College of Medicine, University of Mosul, Mosul, Iraq.

^b Department of Pediatrics, College of Medicine, University of Mosul, Mosul, Iraq.

Authors' contributions

This work was carried out in collaboration between both authors. Both authors read and approved the final manuscript.

Article Information

DOI: 10.9734/JAMPS/2022/v24i530303

Open Peer Review History:

This journal follows the Advanced Open Peer Review policy. Identity of the Reviewers, Editor(s) and additional Reviewers, peer review comments, different versions of the manuscript, comments of the editors, etc are available here: <https://www.sdiarticle5.com/review-history/88672>

Review Article

Received 15 June 2022

Accepted 02 July 2022

Published 07 July 2022

ABSTRACT

Background: Heart malformations are among the commonest indications for admission to hospital and may causes mortality of children. There is a need to highlight this important medical issue as there is no review article on this subject in Iraq.

Aim: This study aims to focus on this diseases in allover Iraq by reviewing the articles that have been published previously among different Iraqi academic scientific journal (IASJ) and concerned with the congenital heart diseases in various Iraqi governorates.

Materials and Methods: Reviewing of the publications were conducted in accordance of that already described. Identification of available articles were done via applying search on IASJ (from 1997 to 2022). The keywords of 'congenital heart disease was used in the search. Comprehensive full text articles in English were enrolled, while those published locally in periodic journals were excluded as there they were difficult to access them. Data extraction from selected publications was done in an independent manner via specialized design including the title of the study, the date of publication, area of research, topic of research, number of cases enrolled, and major results.

Results: Most cases are diagnosed at infancy. Male predominance was recognized in Ventricular septal defect (VSD), Tetralogy of Fallot (TOF), stenosis of Aorta, transposition of the great arteries (D), and aorta's coarctation, Female supremacy was recognized in atrio ventricular canal defect, Patent ductus arteriosus-PDA, atrial septal defects-ASD, and stenosis of pulmonary artery. The acyanotic type was more frequent than those accompanied with cyanosis as reported by many studies. A study from Basra Province has registered the highest incidence of CHD throughout

*Assistant Professor;

#Lecturer (Retired);

*Corresponding author: E-mail: lik@uomosul.edu.iq, lumaallaf1971@yahoo.com;

analysis of data of patients with CHD which constitutes 57(40%) out of 1414 examined children. The reviewing of data from several articles in IASJ revealed a concern with correlation of CHD with other congenital disorders. Few researches were conducted on the treatment of CHD. Several works in Iraq tried to discuss the issue from other points of views as the nutritional status and feeding problems, the impact on the growth, and even the oral and dental health.

Conclusions: According to the results of all reviewed Iraqi studies, there is a need for establishing a high standard centers with providing equipments for pediatric surgical operations .A well prepared staff is required for such type of operations. In addition, a well cooperation between the pediatricians and cardiac surgeons to achieve accurate diagnosis, managements, and follow up is needed.

Keywords: Congenital heart malformations; Iraq; review.

1. INTRODUCTION

Heart malformations are those anomalies of cardiac structure or great vessels that developed prior to birth. They are among the commonest indications for hospital's admission. In fact, a third of these cases were symptomatic during infancy, with various degrees of severity. It happens with wide range from 0.8%- 1.2% of live births [1,2].

Moreover, congenital heart diseases may causes mortality of children, however, there is an interventional and a surgical progress, a paying attention to that disorder by applying a wide investigations and an urgent treatment is indicated [3].

On the other hand, heart malformations among adult patients are crucial raising issue. Their accurate diagnostic methods and treatment are considered as a challenge in cardiology in the last four decades which make an increase in their numbers [4].

The diagnosing of CHD are two dimensional and Doppler echocardiographic examination (gold standard technique), in addition to an elective cardiograph, chest roentgenography [5,6]. Pulse oximetry was found to be specific & sensitive tool to detect cyanotic defects [3].

In general, there are several types of congenital heart malformations including that due to the septal defects as atrial septal defect (ASD), ventricular septal defect (VSD) (Fig. 1). In addition to complete atrio-ventricular canal defect (Fig. 2), tetralogy of fallot (TOF) [7] (Fig. 2), and valve defects, other defects like patent ductus arteriosus (PDA), truncus arteriosus, single ventricle defects, and transposition of the great arteries. All these malformations can be classified into cyanotic and acyanotic types [8].

The CHD may be critically manifested in newborns with cyanosis, poor pedal pulses, congestive heart failure, by failure in his/her pulse oximetry screen before discharge.

The incidence of heart malformations is the same all over the world, but the impact of these disorders occurs mostly in developing countries that have raised fertility rates with low incomes [9].

The lowering of the rates of fertility is one of protocols for improving this problem to prevent the increasing of births with CHD. On the other hand, the economic burden of treatment the CHD is high so it must be freed up by prevention of other diseases as malnutrition and infectious diseases besides the establishment of regional health agencies. About nine per 1000 live birth have CHD [10]. These cases are remain alive with emerging chronic complications that need good understanding which nictitate the presence of primary health care agencies for these cases to examine them physically before the surgical and interventional cardiac catheterization and even patients that recommended potentially to re intervening strategies. On the other hand, prevention of the endocarditis, respiratory complications, support their immunity status, with careful observation of their growth and behavior are crucial.

In fact, in our country-Iraq, there is a need to highlight this important medical issue as there is no review article on this subject. Therefore, the aim of this study is to focus on this diseases in allover Iraq by reviewing the articles that have been published previously among different Iraqi academic scientific journal and concerned with the congenital heart diseases in various Iraqi governorates.

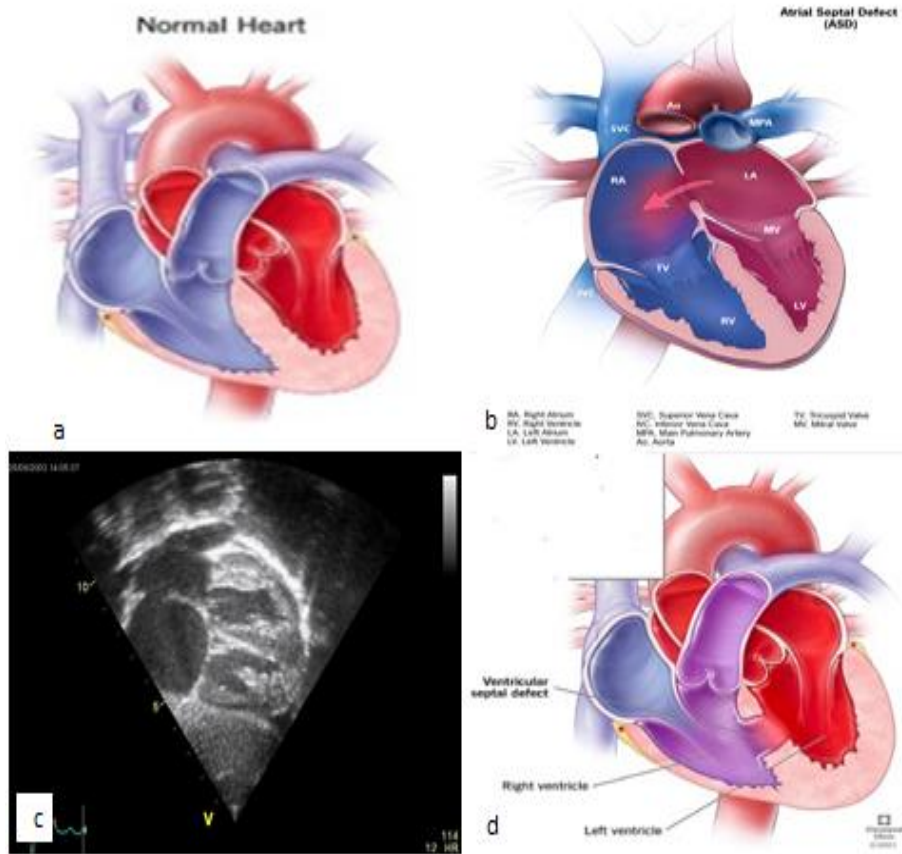


Fig. 1. a. Picture of normal heart; b. Atrial septal defect.(<http://www.statpearls.com>); c. Atrial septal defect by an ultrasound; d. Ventricular septal defect (<https://my.clevelandclinic.org/health/diseases/17615-ventricular-septal-defects-vsd>)

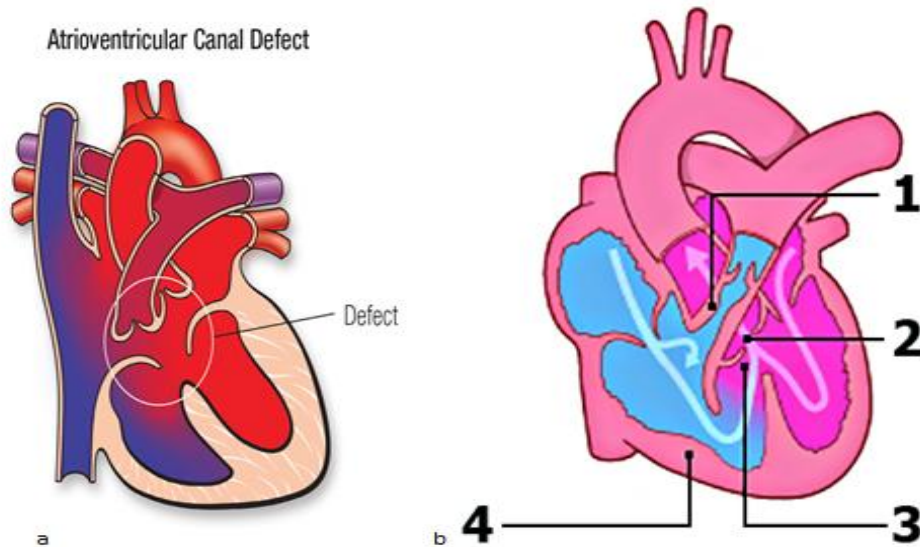


Fig. 2. a. Atrioventricular canal defect, <https://www.heart.org/en/health-topics/congenital-heart-defects/about-congenital-heart-defects/complete-atrioventricular-canal-defect-cavc>; b. Tetralogy of Fallot [7]

2. MATERIALS AND METHODS

Reviewing of the publications were conducted in accordance with that already described [11]. Retrospective identification of available articles (which have been published) were done via applying search on Iraqi Academic Scientific Journals (from 1997 to 2022). The keywords of 'congenital heart disease' was used in the search. A review of all characterized articles was performed in an eligible manner by both authors. Comprehensive full text articles in English were enrolled, while those published locally in periodic journal were excluded as there they were difficult to access them. Data extraction from selected publications were done (independently) via specialized design including the title of the study, the date of publication, area of research, topic of research, number of cases enrolled, and major results.

3. RESULTS AND DISCUSSION

Cardiac malformations represent the most frequent category of congenital anomalies. In spite of the recent progress in surgery and interventional strategies, these disorders still comprises as an essential contributor for morbidity and fatality [1,5,12].

The current work analyzed the data of about 48 articles that was published in various Iraqi academic scientific journals. These articles have discussed the different issues of cardiac malformations in Iraq since 1997 till 2022.

In fact, most of these publications have focused on the clinical pattern of these disorders including age at diagnosis, sex distribution, percentages of subtypes, and the frequency of the clinical presentation of these cases [13,14].

It has been reported that most cases are diagnosed at infancy with difference in male to female predominance among subtypes of anomalies [13]. In a study of Al –Hamash there was a male predominance in VSD, TOF, aortic stenosis, D-transposition of the great arteries(D), and coarctation of the aorta. While, female predominance observed in atrio ventricular canal defect, ASD, PDA, and stenosis of pulmonary arteries [2]. A male predominance was shown in most of articles in Iraq [13,15].

On the other hand, the VSD was the commonest category of these anomalies followed by tetralogy of Fallot(which is considered the

commonest cyanotic subtypes) [5,15]. The majority of cases were presented with respiratory tract infections, heart failure and cyanosis in cyanotic group of patients [2], while the asymptomatic murmur is frequently encountered in the newborn of a study in Al-Diwaniyah city [5]. The acyanotic type was more frequent than those accompanied with cyanosis as reported by many studies [2,5]. Chronic cardiac overload may lead to hypertrophy and heart failure [16], while the congenital heart block was extremely rare [17].

Regarding the prevalence of these anomalies, a study was done at Al-Fallojah including examination and screening of newborn and children during a period of 5 years (2007-2011) using clinical examination, 2 dimensional echocardiography and color Doppler and sometimes cardiac catheterization. The overall prevalence of 19.7/1000. Most of these cases were referred to echocardiography prior to age of one year and it has been noticed that there is an increasing in the prevalence with time as they reported that CHD are found in about 29.2 per 1000 live births in 2011 in comparison with 9.2 per 1000 live births in 2008 [12]. ASD was the commonest lesion in that work, followed by VSD.

In fact, some articles studied the prevalence of congenital malformations in the specific society as there is no previous reports concerning with the overall prevalence in Iraq.

Another study from Basra Province has registered the highest incidence of CHD throughout analysis of data of patients with CHD which constitutes 57 (40%) out of 1414 examined children retrospectively via echocardiography in Major centers during 24 months [14]. They reported that 42.8% of these children were ages less than one year, while 35.2% of cases were aged between 1-4 years. This high incidence may be due to decades of Wars that affect people in Basra Province. VSD was the most common type and present in 247 patients (43.3%), the majority of them were suffered from membranous subtype followed muscular, and then supra cristal subtype. The second commonest congenital heart disease diagnosed by echocardiography was tetralogy of Fallot [18].

The third study on the prevalence was from Mosul. The author reported that the prevalence was (6.1/1000 patients). The commonest type was ASD (42%), followed by VSD which was detected in 30% of cases and followed by PDA

.An association was found between family history, consanguinity and occurrence of CHD beside the correlation to the maternal risk factors such as mothers disease, drug intake, obesity, smoking during pregnancy [12].

The detection of CHD at early time is crucial to manage the patients properly beside the accurate clinical examination with high standard echocardiography. All these factors represented the considered a gold items in diagnosing of CHD. Two dimensions echocardiography is essentially used in these cases. The effective management of these cases needs establishing of specialized cardiac centers in our country to overcome the delay which may has an adverse effect on the diseases' out- come [5], however, a Pulse oximetry was used in some researches and it is considered a sensitive and specific way especially for the cyanotic type [3].

On the other hand, several works in Iraq tried to discuss the issue from other points of views as the nutritional status and feeding problems, the impact on the growth, and even the oral and dental health.

Wishel reported that cases of with CHD are suffered from difficult feeding, low birth weight, chronic diarrhea. In addition, half of cases taking medication for heart disease that leads to repeated vomiting, difficulty taking liquids and refusal of feeding or eating, while patients with CHD may presented with wasting, stunted growth or malnutrition [18] especially in cases of pulmonary hypertension ,and cyanosis.

In fact, as the CHD was a major contributor to the children' growth, there is a need to manage these cases and correction of these anomalies by surgery or cardiac catheterization [19,20].

A study of Al-Rahim revealed that the most common type that can affect the growth is VSD (even in the moderate type), as there is an increasing in the total body size or separately which lead to failure to thrive in these cases and that must be considered seriously [20]. In general ,the growth is influenced in all cyanotic CHD and a cyanotic CHD. In our country, there is a delay in the surgery, so there is a crucial need for the providing of highly developed centers and medical counseling [20,21,22].

Moreover, the reviewing of data from several articles in Iraqi academic journals revealed a concern with correlation of CHD with other

congenital disorders. Salih reported high frequency of VSD, and even other types of CHD among cases with Down syndrome [23,24], while another work of Zain et al., showed that CHD was found in 28% of patients of esophageal atresia beside distal tracheoesophageal fistula. These findings supported the concept that prenatal surveillance and counseling of cases with different anomalies is crucial to predict CHD [6,25,26].

On the other hand, children with CHD are "at risk" from malnourishment and dental diseases , the focus must primarily be on the awareness of infective endocarditis, and oral hygiene instructions and they are needed to develop the preventive protocols [27]. The high frequency of the high enamel defects was noticed in children with VSD compared to that in control [28].

Among all researches in Iraq there is only one study that focuses on the CHD at adulthood. Authors reported that Acyanotic types are more common than the cyanotic one, with female predominance. Usually the percutaneous intervention was successfully used as the first line approach, however, the surgical choice remains the gold standard method [4].

An essential of a need for more researches on the treatment of CHD as the reports on this topic is scanty. A study of Ammar and Ataar was analyzed the trans atrial attitude for total correction of TOF of 24 child. They concluded that this approach is a feasible technique for total repair of TOF in adequate pulmonary annulus size with sufficient performance of late postoperative echocardiography [29].

The most frequent cause of congenital cyanotic heart disease is TOF-Tetralogy of Fallot .It constitutes 7.5% of all CHD in Iraq. It is the most common congenital lesion that is likely to result in survival to adulthood and experienced in adulthood post- repair [29]. Catheterization and angiography still considered (in most centers) as essential preoperative diagnostic step [30].

On the other hand, Mahbuba and Sharba concentrated on the Fontan's experience in Iraq [31] in a study on cases suffering from complex congenital heart defect with common pathology that is the single ventricle. The Fontan surgery is now among the most frequent procedures conducted to manage complex congenital cardiac defects not amenable to biventricular repair. Authors concluded that there was lacking

of therapeutic agents and equipmental support for the intensive care unit and theater of pediatric surgeons (cardiac) beside a deficient protocols for the training of these operations. They concluded also that the deficient diagnosis and paucity of equipments with un education of the family of patients lead to the slowness of their admission and follow up failure.

A study of Al-Suwayfee showed that Aortic root dilatation (ARD) must be taken in a serious manner in cases with TOF and in any condition that the surgical correction must be done beyond infantile period, increasing patient age and severe right ventricular outflow tract (RVOT) obstruction with pulmonary hypoplasia were positively related with the increasing risk of the occurrence of ARD [32].

Aorto pulmonary window is an uncommon congenital cardiac defect. Usually it is non-restrictive and the conventional treatment is surgery at an early age to overcome the developing of pulmonary vascular obstructive diseases. It is restrictive only in 10% of the cases and trans catheter closure was mentioned in case reports. They are commonly limited to these cases using Amplatzer duct occluder device [33] Fig. 3.

Congenital heart disease is a global health problem affecting children at infancy and young age and with many risk factors revealed significantly many effects on its development as consanguinity, maternal risk factors during pregnancy, and positive family history. The proper regular antenatal care and counseling with supplementary treatment especially throughout the most vulnerable period of embryogenesis is vital to prevent occurrence of such malformation [12].

A study of Aziz et al. reported that the raised level of atrial naturetic hormone (ANP) and BNP were frequent in plasma of cases with CHD and it is positively correlated with the function of their ventricles, however, the plasma level of BNP appears to be more efficient than ANP and considered as non-invasive cardiac markers to facilitate the diagnosis of different pattern of CHD [34].

Finally, CHD may leads to several complications .A study of Cardiac arrhythmias in ischemic heart disease via Holter monitoring showed a

considerable number of these patients had CHD especially the cyanotic type [33]. Moreover, several cases of patients who diagnosed with brain abscess had CHD [35,36,37].

According to our results of all reviewed Iraqi studies, there is a need for establishing a high standard centers with providing equipments for pediatric surgical operations. A well prepared staff is required for such type of operations. In addition, a well cooperation between the pediatricians and cardiac surgeons to achieve accurate diagnosis, managements, and follow up is needed. As early as possible, chest radiograph and roentgenogram of the chest by an expert radiologist is indicated when there is any sign of post- natal respiratory distress [38,39,40,41,42].

Moreover, there is a real need for the presence of complementary centers concerning with feeding, oral health, awareness inside a specialized cardiac disease hospitals in each government in Iraq to achieve satisfactory results to face these disorders [36].

In fact, regarding the last 5 years, there is a diminishing in articles on the congenital malformations of heart especially with emergence of COVID-19 [43,44,45,46]. In 2018, only three studies were found. One discuss the role of Pulse oximetry in detection of these malformations [43]. The second article recommend the solving of these congenital malformations as it affected the growth [44]. In addition, A study concluded that the incidence of congenital malformations of heart in Mosul in 2018 was 72.5% among Down's cases [45].

In 2019, Al-Zuhairi and Muhsen reported the predominance of VSD and showed that acyanotic type presented with respiratory infections [46,47] Fig. 4.

On the other hand, Al-Dalla et al., reported that acyanotic type was the most frequent type at Ramadi City [48].

In 2020, a study suggested a correlation between the prematurity and congenital malformations of heart in Mosul city [49].

Recently, a high frequency was found between the complete atrioventricular canal defect and pulmonary hypertension in Down cases [50,51].

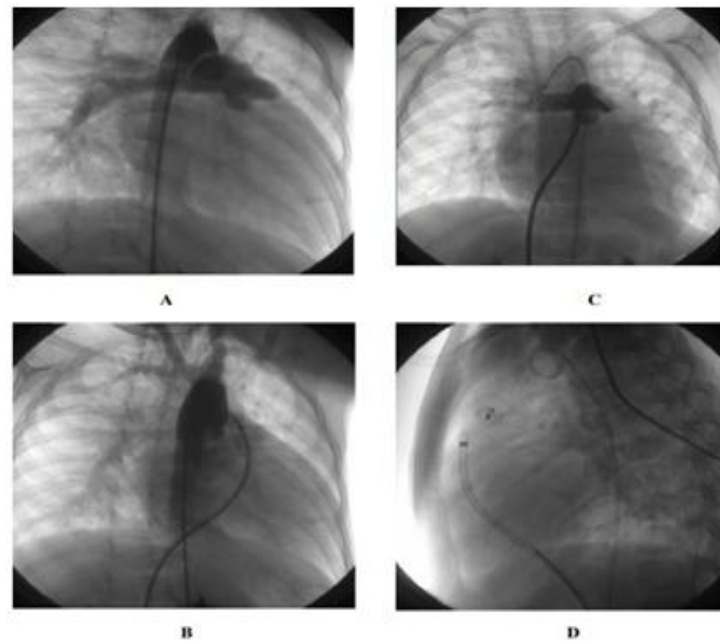


Fig. 3. The Aortic –pulmonary window in right anterior oblique projection (A). Complete closing of Aortic –pulmonary window by Amplatzer duct occluder device in right anterior oblique projection (B). Amplatzer duct occluder, Pulmonary artery ,and ascending aorta in anterioposterior projection (C). The success after using Amplatzer duct occluder device in left lateral projection (D) [33]

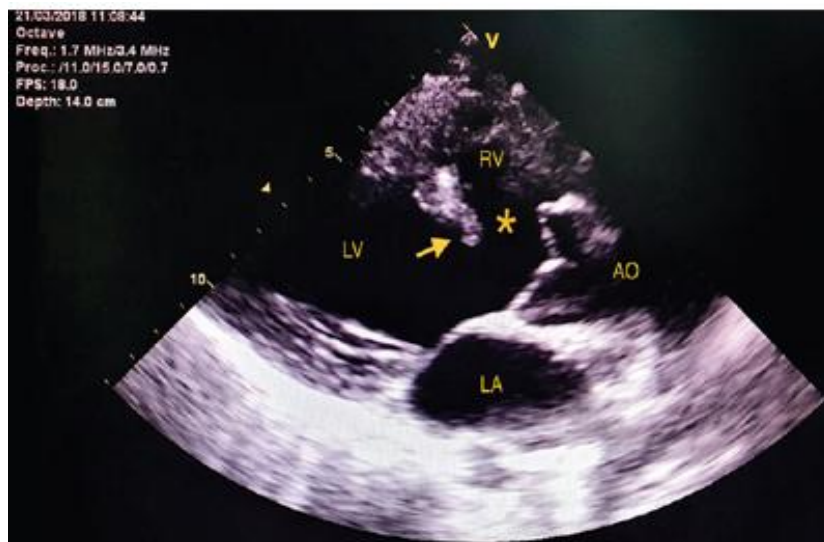


Fig. 4. Ventricular septal defect [46]

4. CONCLUSION

There is a concern with the heart malformations and their impact on general health and community in Iraq, however, there is still a need for more researches in future as this type of congenital disease comprises a continuous and raising problem on the medical, economic, and

social facets. The findings of the different studies make a database for further studies that will highlight the etiology and ethnic disparity of CHD in this country and help to provide an improvement in health policies to improve of diagnostic and therapeutic facilities. The raised prevalence in Iraq require advance research & registration system to apply in Iraqi medical

offices. The catastrophic successive wars imposed on Iraq undoubtedly have played some role in this problem, however, the overall pattern of CHD is similar to the finding in other countries.

RESEARCH HIGHLIGHT

Reviewing of the publications were conducted in accordance with that already described. Identification of available articles were done via applying search on Iraqi Academic Scientific Journals (IASJ) (from 1997 to 2022).

The keywords of 'congenital heart disease' was used in the search. Comprehensive full text articles in English were enrolled, while those published locally in periodic journals were excluded as there they were difficult to access them.

Most cases are diagnosed at infancy ,there was a male predominance in Ventricular septal defect (VSD), Tetralogy of Fallot (TOF), aortic stenosis, transposition of the great arteries (D), and aorta's coarctation, while, female predominance was observed in atrio ventricular canal defect, patent ductus arteriosus-PDA, atrial septal defects-ASD, and stenosis of pulmonary artery. The acyanotic type was more frequent than those accompanied with cyanosis as reported by many studies.

CONSENT

It is not applicable.

ETHICAL APPROVAL

It is not applicable.

ACKNOWLEDGEMENTS

Authors would like to thank to Dr. Amjad Hazim, Department of biochemistry, College of Medicine, University of Mosul for his help.

COMPETING INTERESTS

Authors have declared that no competing interests exist.

REFERENCES

1. Wren C. The epidemiology of cardiovascular malformations. In: Moller JH, Hoffman JIE, Benson DW, van Hare GF, Wren C, editors. Pediatric Cardiovascular Medicine. Oxford, England: Wiley-Blackwell. 2012;268–275.
2. Al-Hamash SM. Pattern of Congenital Heart Disease a Hospital-Based Study. Al-Kindy College Medical Journal. 2006;3(1): 44-48.
3. Mahmood NSh, Abbas AM, Ibrahim M. Role of Pulse Oximetry in Detection of Congenital Heart Disease in Children. The Medical Journal of Tikrit University. 2018; 24(1):51-60.
4. Alkhalidi JN, Al-Farhan H. Adult Congenital Heart Diseases: Clinical Pattern, Management and Immediate Outcome in Ibn-Al-Bitar Center for Cardiac Surgery, Baghdad 2013 .Thi-Qar Medical Journal. 2016;12(2):91-104.
5. Hussain AM, Hussain AJ, Hmood QK .Pattern of congenital heart disease in newborn in Al-Diwaniyah maternity and children teaching hospital. Al-Qadisiyah Medical Journal. 2013;9(15):202-211.
6. Al-Mefraji S. Is any Relation between Cytogenetic types of Down's Syndrome and Congenital Heart Disease. Iraqi Journal of Community Medicine. 2012; 25(4):304-307.
7. Englert JAR, 3rd, Gupta T, Joury AU, et al. Tetralogy of Fallot: Case-Based Update for the Treatment of Adult Congenital Patients. Curr Probl Cardiol. 2019;44(2):46–81. DOI: 10.1016/j.cpcardiol.2018.03.002
8. Hoffman Julien IE. The global burden of congenital heart disease. Cardiovasc J Afr. 2013 Jun;24(4):141–145. DOI: 10.5830/CVJA-2013-028 PMID: PMC3721933, PMID: 24217047.
9. Khasawneh W, Hakim F, Abu Ras O, Hejazi Y, Abu-Aqoulah A. Incidence and Patterns of Congenital Heart Disease Among Jordanian Infants, a Cohort Study From a University Tertiary Center. Front. Pediatr. 2020;8:219. DOI: 10.3389/fped.2020.00219
10. Puri K, Allen HD, Qureshi AM. Congenital Heart Disease. Pediatr Rev. 2017 Oct;38(10):471-486. DOI: 10.1542/pir.2017-0032
11. Botto LD. Epidemiology and Prevention of Congenital Heart Defects. In: Allen HD, Shaddy RE, Penny DJ, Feltes TF, Cetta F, eds. Moss & Adams' Heart Disease in Infants, Children, and Adolescents, Including the Fetus and Young Adult, 9th ed., Lippincott Williams and Wilkins. 2016; 1:55–86.

12. Al-Hyali EGS. Prevalence and Risk Factors for Congenital Heart Anomalies among Hospital Attendees in Mosul City Iraqi Journal of medical specialities. 2015; 14(2):229-236.
13. Tafash Dagash MT, shallal I, Saleh SK. Prevalence of Congenital Heart Disease in Fallujah General Hospital, western of Iraq (2007-2011). Al- Anbar Medical Journal. 2015;12(1):83-95.
14. Khadim J, Issa S. Spectrum of congenital heart diseases in Basra: an echocardiography study. The Medical Journal of Basrah University. 2009; 27(1):15-18.
15. Al-Dalla Ali FJ, Hammood MD, Al-Dulaimy KM, Bassim Salman BM. Pattern of Congenital Heart Disease among Children Referred for Echocardiography in Ramadi City, West of Iraq. Al- Anbar Medical Journal. 2019;15(2):40-44.
16. Ahmed DA. Left Ventricle Remodeling for Patients with Heart Failure and its Influence on Cardiac Performance. Journal of the Faculty of Medicine. 2013;55(2):125-130.
17. AL-Daghir HA. Heart block necessitating pacing at Iraqi center for heart diseases, October 2011 – August 2013. Muthanna Medical Journal. 2016;3(1):43-48.
18. Wishel OF. Feeding Problems in Children with Congenital Heart Diseases in Nasiriya Heart Center. Iraqi National Journal of Nursing Specialties. 2014;27(1):111-119.
19. Musa RF, Alyasiri AA, Alghanimi MKS. Effect of the Congenital Heart Disease on Growth and Nutritional State of Children. Diyala Journal of Medicine. 2018;15(2):52-67.
20. Al-Kufy MA. Growth parameters of healthy babies from one day to thirty six months in Najaf city. Kufa Medical Journal. 2009; 12(1):112-119.
21. Al- Rahim QA. Effect of Ventricular Septal Defect on the Growth Pattern of Children. Iraqi Academic Scientific Journal. 2006; 5(1):8-13.
22. Baaker RH. Malnutrition and growth status in patients with congenital heart disease. Iraqi Academic Scientific Journal. 2008; 7(2):152-156.
23. Salih AF. Congenital heart disease in down syndrome: experience of Kurdistan of Iraq. Duhok Medical Journal. 2011;5(2):24-33.
24. Salih DJ, Bakir N, Eissa AA, Al-Allawi NA. Clinical and cytogenetic profile in patients with down syndrome in duhok province, Iraq Medical Journal of Babylon. 2017; 14(2):389-401.
25. Zain AZ, Mahmood SS, Fadhil SZ. Surgical outcome of 65 cases of congenital esophageal atresia with tracheoesophageal fistula: Experience of 5 years in two institutes. Iraqi Journal of Medical Sciences. 2014;12(2):168-172.
26. Rasheed NE, Hamad Sh, Nouri MA. Incidence of cleft lip and palate in erbil city. Mustansiria Dental Journal. 2010;7(1):106-112.
27. Al-Alousi WS --- Nidaa O. AL-Etbi NO. Enamel defects in relation to nutritional status among a group of children with congenital heart disease (*Ventricular septal* defect). Journal of Baghdad College of Dentistry. 2011;23(3):124-129.
28. Al-Haidary MJ, Radhi NJ. Dental caries and treatment needs in relation to nutritional status among children with congenital heart disease Journal of Baghdad College of Dentistry. 2017;29(2):108-114.
29. Ammar A, Attar MA. Transatrial approach for total tetralogy of Fallot TOF correction: analysis of 24 cases. Journal of the Faculty of Medicine. 2017;59(4):280-284.
30. Al-Hamash SM. The catheterization and angiographic variations in iraqi patients with tetralogy of fallot. Journal of the Faculty of Medicine. 2005;47(1):28-34.
31. Mahbuba WA, Sharba LF. Fontan's Iraqi experience. Kufa Med J. 2008;11(2):52-60.
32. Alsawayfee KI. Aortic root dilatation among children with un operated Fallot tetralogy. A clinical and echocardiographic study. Journal of the Faculty of Medicine 2016 ;58(4) 320-324.
33. Khalid ZH. Trans catheter Closure of Nonrestrictive Aorto pulmonary Window Iraqi Academic Scientific Journal 2012;11(3):430-432.
34. Aziz A, Al-Shamma Y, Waheed R. The relation of plasma level of atrial and brain natriuretic peptide to left ventricular function in subjects with congenital heart disease. Kufa Medical Journal. 2011; 14(1):1-9.
35. Nasir HA. Cardiac risk Factors in Young Patients with Ischemic stroke. Kufa Medical Journal. 2008;11(2):45-50.
36. Hulaihil AF. Cardiac arrhythmias in IHD as detected by Holter monitoring. Thi-Qar Medical Journal. 2015;10(2):89-102.

37. Al-Tamimi ZA, Al-Hadithi ' TS, Al-Khalili A, Al-Diwan JK. Brain abscess in Iraq during a 10 years period: Part 1. Epidemiology, aetiology and clinical picture. Journal of the Faculty of Medicine. 2007;49(1):77-81.
38. Al-Janabi MK, Oleiwe AO, Jaber RK. Recurrent Pneumonia in Children at a Tertiary–Pediatric Hospital in Baghdad. Iraqi Academic Scientific Journal. 2018; 17(4):377-383.
39. Hassan D, Al-Rubaiy F, Al-Hamash SM. Electro Cardiographic Features of Patients With Tetralogy of Fallot .Al-Kindy College Medical Journal. 2007;4(1):19-22.
40. Al-Saad RH, Salih FD. Chest Radiographic Finding in Neonatal Dyspnea .Al-Kindy College Medical Journal 2008;4(2):40-44,377-383.
41. Mussa RF, Alyasiri AA, Al-Marzok JM. Maternal satisfaction of pediatric care providers for children with chronic diseases. Al-Qadisiyah Medical Journal. 2015;11(19):41-46.
42. Hameed NN, Majid I. Short term outcome of macrosomic neonates of diabetic & non-diabetic mothers .Journal of the Faculty of Medicine. 2012;54(4):300-305.
43. Mahmood NS, Abbas AM, Ibrahim M. Role of Pulse Oximetry in Detection of Congenital Heart Disease in Children. The Medical Journal of Tikrit University. 2018; 24(1):51-60.
DOI:
<http://dx.doi.org/10.25130/mjotu.24.01.06>
44. Alghanimi MKS, Alyasiri AA, Musa RF. Effect of the Congenital Heart Disease on Growth and Nutritional State of Children. Diyala Journal of Medicine. 2018;15(2):52-67.
Available:<https://doi.org/10.26505/DJM>.
45. Yassen ZM, Fawzi MM, Alsaoor RS. Frequency of congenital heart disease among patients with Down's syndrome in Mosul. Annals of the College of Medicine Mosul. 2018;4(2):24-28.
Available:<https://www.iasj.net/iasj/download/80655880d0bf3763>.
46. Tripathi RR. Ventricular Septal Defect: Echocardiography Evaluation. J Indian Acad Echocardiogr Cardiovasc Imaging. 2020;4:260-6.
DOI: 10.4103/jiae.jiae_42_20
47. Al-Zuhairi HA, Muhsen AA. Pattern of Congenital Heart Disease In Children Attending Central Teaching Pediatric Hospital, Baghdad. Al-Kindy College Medical Journal. 2019;15(2):82-86.
Available:www.jkmc.uobaghdad.edu.iq
48. Al-Dalla Ali FJ, Hammood MD. Al-Dulaimy KM, Salman BM. Pattern of Congenital Heart Disease among Children Referred for Echocardiography in Ramadi City, West of Iraq. Al- Anbar Medical Journal. 2019 ;15(2):40-44.
Available:<https://amj.uoanbar.edu.iq>
49. Attia QA, Al-Obeidi RA. Risk Factors for Congenital Heart Disease among Infants In Mosul City. Mosul Journal of Nursing. 2020;8(2):177-186.
DOI: 10.33899/mjn.2020.167033
50. Alsuwayfee KI, Allbu-Dawlah ME, Mohammed QN. Complete atrioventricular canal defect, Patent ductus arteriosus Congenital heart diseases and pulmonary hypertension among Down syndrome pediatric patients. Annals of the College of Medicine Mosul. 2020;42(1):50-56.
Available:<https://www.iasj.net/iasj/download/74eaf4536b83d33b>
51. Ahmed MH, Maerozy KAM, Mohammad JB, Albarwari N. Effect of Coronavirus Disease 2019 (COVID-19) Pandemic on Catheterization Laboratory Activity in Azadi Heart Center, Duhok, Iraq. Medical Journal of Babylon. 2022;19(1):21-25.
DOI: 10.4103/MJBL.MJBL_52_21

© 2022 Al-Allaf and Mahmmod; This is an Open Access article distributed under the terms of the Creative Commons Attribution License (<http://creativecommons.org/licenses/by/4.0>), which permits unrestricted use, distribution, and reproduction in any medium, provided the original work is properly cited.

Peer-review history:
The peer review history for this paper can be accessed here:
<https://www.sdiarticle5.com/review-history/88672>