

## Repair of Classical Adult Female Exstrophy (Reared as Male) with Management of Surgical and Psychological Issues

Mukesh Chandra Arya<sup>1\*</sup>, Ankur Singhal<sup>1</sup>, Vivek Vasudeo<sup>1</sup>, Ajay Gandhi<sup>1</sup>,  
Manoj Kumar Garg<sup>2</sup> and Yogendra Shyoran<sup>1</sup>

<sup>1</sup>Department of Urology, Sardar Patel Medical College, Bikaner, Rajasthan, India.

<sup>2</sup>Consultant Plastic Surgeon, Tanti General and Multispecialty Hospital, Sriganganagar, Rajasthan, India.

### Authors' contributions

This work was carried out in collaboration among all authors. Author MCA did formal analysis, was a major contributor in writing original draft and provide concept of the study. Author AS played a key role in manuscript development, data curation and writing the original draft. Authors VV and AG helped in acquisition, analysis and contributes in writing the manuscript. Author MKG helped in the abdominal wall reconstruction and gave insight about the key steps of the procedure. Author YS helped in the proof reading and revision of the article. All authors read and approved the final manuscript.

### Article Information

#### Editor(s):

(1) Dr. Muhammad Ujudud Musa, Federal Medical Centre, Nigeria.

#### Reviewers:

(1) Mohamed A Baky Fahmy, AL-Azhar University, Egypt.

(2) Roberto Guarniero, Universidade De Sao Paulo, Brazil.

Complete Peer review History: <http://www.sdiarticle4.com/review-history/63197>

Case Report

Received 20 September 2020

Accepted 25 November 2020

Published 11 December 2020

### ABSTRACT

There are very few case reports of classical bladder exstrophy (CBE) presenting at an adult age. A 19 years old male patient was admitted with complaints of urinary incontinence since birth and was found out to be a CBE with female gender genetically. She underwent complete genitourinary reconstruction in stages. She needed multiple psychiatric consultations to accept change in the gender. Genitourinary reconstruction with achieved continence in adult exstrophy warrants this presentation.

**Keywords:** Adult exstrophy; complete bladder exstrophy; young-dees Bladder repair; ileocystoplasty; rectus abdominis flap.

## ABBREVIATIONS

CIC : Clean Intermittent Catheterization  
IVU : Intravenous Urography  
SPC : Suprapubic Cystotomy  
CBE : Classical Bladder Exstrophy

## 1. INTRODUCTION

Incidence of classical bladder exstrophy (CBE) in females is one in two lacs live births. There are few case reports of adult exstrophy. Presentation of such a female in adulthood brought up as male up to 19 years is unheard of. There are no standard guidelines for management. Herein, we present an adult female CBE who underwent staged genitourinary reconstruction.

## 2. CASE PRESENTATION

A 19-year-old patient presented to us with total urinary incontinence since birth in November 2016. Examination of genitalia revealed classical female exstrophy with good bladder plate (Fig. 1A). She had regular menstruation from last 5 years which she presumed bleeding to be due to infection. Patient's parents sought local physicians' opinion and were advised surgery at the age of 18 years and this was the reason for late presentation. Routine blood and biochemical investigations were normal. USG showed normal both kidneys. MRI revealed female internal genitalia. Karyotype was 46XX. After psychiatric consultation of patient and her relatives for gender dysphoria, they accepted her female gender identity. Multiple bladder biopsies revealed nonspecific inflammatory changes.

Patient's relatives were explained about the need for staged surgery and clean intermittent catheterization (CIC).

Under general anesthesia and supine position, ureters were cannulated. After infiltrating 1 in 1 lakh adrenaline with lignocaine, bladder and urethra were mobilized. Single stage closure of female bladder exstrophy with modified Cohen's ureteric reimplant, Young-Dees bladder neck reconstruction and genitoplasty (Fig. 1C) were done. Ureteric catheters and malecot were brought out after creating neoumbilicus. Bladder was closed in two layers (Fig. 1B).

Post-operative course: She withstood the procedure well. Ureteric catheters were removed after two weeks. Suprapubic cystotomy (SPC) was removed after 3 weeks. After removal of per urethral catheter she voided well. At 6 months dry interval was 2 hours with occasional incontinence. She had improved self-confidence and better social interactions as female.

Intravenous urogram (IVU) (Fig. 2A) after one year had normal upper tracts, well-formed bladder neck with 100 cc bladder capacity. To overcome frequency and incontinence, bladder augmentation with ileum (Fig. 2B) was done. Post-operatively, there was dehiscence of anterior abdominal wall and prolapse of augmented bladder (Fig. 3A). Multiple attempts at simple closure failed due to hardly any intervening tissue. Therefore, right rectus abdominis flap raised on inferior epigastric vessels was mobilized and interposed between augmented bladder and anterior abdominal wall and meshplasty was done (Fig. 3B and 3C).

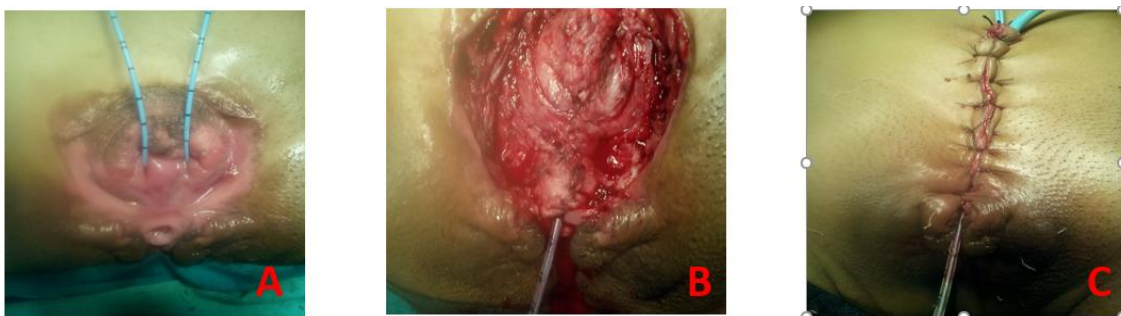
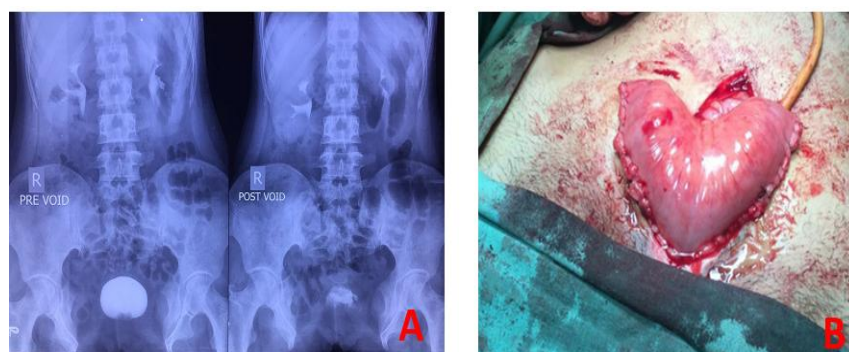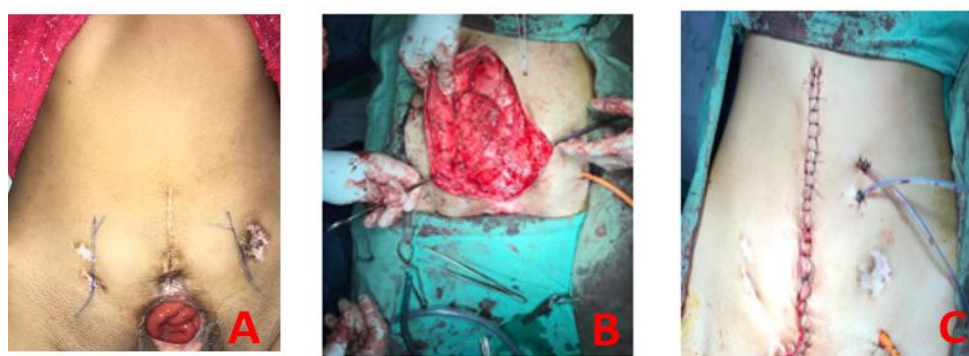


Fig. 1. A) Good bladder plate with cannulated ureters B) Bladder closure in two layers  
C) Completed Genitoplasty and abdominal closure



**Fig. 2. A) IVU showing no hydronephrosis, bladder capacity approximately 100 cc and insignificant post void residual urine. B) ileocystoplasty**



**Fig. 3. A) Dehiscence of anterior abdominal wall and prolapse of bladder, marking of inferior epigastric vessels using color doppler B) Mobilized Rectus Abdominis Flap C) Meshplasty and Closure**

Multiple psychology sessions and support of her elder sister helped her to attain female attire, gesture and mannerism. She felt excellent socially and psychologically. On her insistence, she got married and is sexually cohabiting well. Finally, she is continent and dry with more than 300 ml capacity of bladder, normal upper tract and on CIC every 3-4 hours. She has been followed up for two years with urine culture, renal function tests and ultrasonography abdomen every 6 months. She applied for change of sex in government ID's and passport. She is being followed up with yearly cystoscopy.

### 3. DISCUSSION

Surgical problems with adult exstrophy: Reconstruction should begin at birth to get best results. Because of exposure to external environment, often the bladder plate is small, fibrotic and needs augmentation. A. Jana et al. [1] did augmentation in 7 out of 8 such patients. Patients presenting at adult age have chances of malignancy and they need to be followed up after

reconstruction. Very small bladder plate or malignant changes may need cystectomy and diversion. Perfect continence is very difficult to achieve and they may need CIC and 36.8% patients may report mild to moderate incontinence and may require secondary auxiliary procedures [2] or continence cutaneous diversion [3]. By adulthood, most of the bones are fused and there is no role of osteotomies.

Abdominal closure is very difficult and may need flaps. Because of deficient abdominal wall there is high incidence of vesicocutaneous fistula [4]. Pathak HR et al. [4] reported four adult patients of exstrophy whom they successfully treated with bladder preservation (ileocystoplasty) and reconstruction. Gulati et al. [5] reported two adult females with exstrophy who underwent cystectomy and modified Mainz pouch. R.B.Nerli et al. [6] earlier treated 4 such patients with cystectomy and later 3 patients with bladder preservation with excellent results. J.E. Mensah et al. [3] reported seven adult patients of mean

age 18 years, six of whom had bladder preservation and reconstruction in single or two stages.

Psychological problems- Because of incontinence, these patients have poor self-image, difficult schooling, difficult to play outdoor games, poor social interactions. Our case was even more difficult because she was mentored and cared as male. Psychological problems after gender reassignment could be emotional trauma, catastrophic reaction, depression, violent behaviour, adjustment problems, gender identity crisis and sexual problems including anorgasmia. Majority of these female patients remain sexually active (up to 84%) [2]. Our patient had few sessions with psychiatrist both before and after surgery. Lessons learnt: Bladder augmentation and Rectus abdominis flap interposition should have been combined with urogenital reconstruction in a single-stage.

#### 4. CONCLUSIONS

Adult female exstrophy is rare and our case had unique presentation since she was raised as a male. There are very few reported adult series. Earlier most of such adults underwent cystectomy for the fear of malignancy. Limited available literature suggests no role of osteotomy in such cases. Most adults need bladder augmentation. Abdominal wall closure is difficult and needs flap for successful reconstruction. Perfect continence is the ultimate goal. This report shows bladder preservation and successful reconstruction is possible in adult exstrophy. They need lifelong CIC and yearly check cystoscopy.

#### CONSENT

Patient consent was duly obtained before working on this manuscript.

#### ETHICAL APPROVAL

It is not applicable

#### COMPETING INTERESTS

Authors have declared that no competing interests exist.

#### REFERENCES

1. Jana K Maiti, TK Mondal, TK Majhi. Management of the exstrophy-epispadias complex in adolescents and adults. African Journal of Urology. 2017;23:100-104. Available:<http://dx.doi.org/10.1016/j.afju.2016.09.001>.
2. Bujons A, Lopategui DM, Rodríguez N, Centeno C, Caffaratti J, Villavicencio H. Quality of life in female patients with bladder exstrophy-epispadias complex: Long-term follow-up. J Pediatr Urol. 2016; 12(4):210.1-6. DOI: 10.1016/j.jpurol.2016.05.005. Epub 2016 May 28. PMID: 27290615
3. JE Mensah, EK Asante, WA Mensah, H Glover-Addy. Continent cutaneous diversion for bladder exstrophy in adults. African Journal of Urology; 2013.
4. JE Mensah, EK Asante, WA Mensah, H Glover-Addy. Continent cutaneous diversion for bladder exstrophy in adults. African Journal of Urology; 2013.
5. Pathak HR, Mahajan R, Ali NI et al. Bladder preservation in adult classic exstrophy: early results of four patients. Urology. 2001;57(5):906-10. DOI:[doi.10.1016/s0090-4295\(01\)00959-1](https://doi.org/10.1016/s0090-4295(01)00959-1). PMID: 11337291.
6. Gulati P, Yadav SP, Sharma U. Management of bladder exstrophy in adulthood: report of 2 cases. J Urol. 1997;157(3):947-8. PMID: 9072609.
7. Nerli RB, Kamat GV, Alur SS, Koura A, Prabha V, Amarkhed SS. Bladder exstrophy in adulthood. Indian J Urol. 2008;24(2):164-168. DOI:[10.4103/0970-1591.40609](https://doi.org/10.4103/0970-1591.40609)

© 2020 Arya et al.; This is an Open Access article distributed under the terms of the Creative Commons Attribution License (<http://creativecommons.org/licenses/by/4.0>), which permits unrestricted use, distribution, and reproduction in any medium, provided the original work is properly cited.

*Peer-review history:*  
*The peer review history for this paper can be accessed here:*  
<http://www.sdiarticle4.com/review-history/63197>