

Intravascular Imaging-guided Percutaneous Coronary Intervention for Braid-like Coronary Stenosis in a Patient with Prior Myocardial Infarction

Shigenori Ito^{1,2*}

¹Division of Cardiology, Nagoya City East Medical Center, Nagoya, Japan.
²Sankuro Hospital, 7-80 Kosaka-Cho, Toyota-Shi, Aichi-ken 471-0035, Japan.

Author's contribution

The sole author designed, analyzed and interpreted and prepared the manuscript.

Article Information

DOI: 10.9734/CA/2017/35792

Editor(s):

(1) Francesco Pelliccia, Department of Heart and Great Vessels University La Sapienza, Rome, Italy.

Reviewers:

(1) Nikolaos Kakouros, University of Massachusetts, USA.

(2) Jagadeesh Kalavakunta, Michigan State University, USA.

Complete Peer review History: <http://www.sciencedomain.org/review-history/20864>

Received 29th July 2017

Accepted 2nd September 2017

Published 8th September 2017

Case Report

ABSTRACT

A 77-year-old man was admitted to our hospital because of chest oppression on efforts. He had developed an inferior acute myocardial infarction and had undergone percutaneous coronary intervention (PCI) for the right coronary artery (RCA) 10 years earlier. Significant stenoses were detected in the proximal left anterior descending artery (LAD), obtuse marginal artery (OM), and proximal RCA by coronary angiography. The coronary angiography revealed a braid-like stenosis in the proximal RCA. Because his symptoms continued even after PCI for LAD and OM lesions, we performed PCI for the RCA lesion. OCT revealed the most severe stenosis located proximally and a stenosis with multiple channels located distally. The proximal stenosis had thick homogeneous and high-intensity septum. In contrast, the distal stenosis had multiple lumens separated by high-intensity thin septa. On the other hand, IVUS clearly showed that different channels were connected to the different side branches at both edges of the stenosis, and they converged into a single lumen proximally and distally. IVUS and OCT proved beneficial for the evaluation of coronary artery structure with a braid-like appearance. We performed PCI under the guidance of OCT.

*Corresponding author: E-mail: shigeito918@gmail.com;

Keywords: Myocardial infarction; recanalized thrombus; braid-like coronary stenosis; optical coherence tomography; percutaneous coronary intervention.

1. INTRODUCTION

Recently, the development of intravascular imaging modalities such as intravascular ultrasound (IVUS) and optical coherence tomography (OCT) has delineated the detailed structure of braid-like coronary stenoses detected using coronary angiography. These lesions have been reported to resemble Swiss cheese [1], a lotus-root [2], spider-web-like, a honeycomb [3-5], or arteries in the artery [6] using IVUS and OCT findings. We used IVUS and OCT to evaluate and treat a case of braid-like coronary stenosis during percutaneous coronary intervention (PCI) in a patient with inferior prior myocardial infarction (MI).

2. CASE PRESENTATION

A 77-year-old man who had inferior MI earlier was admitted to our hospital because of chest oppression on effort in November 2009. He had undergone PCI for inferior acute MI at another hospital 10 years earlier. His coronary risk factors included dyslipidemia, hypertension, and an ongoing smoking habit. An electrocardiogram obtained on admission showed normal sinus rhythm without ST-T change, and revealed mild hypokinesia of the inferior left ventricular wall and an ejection fraction of 79%. Cardiac catheterization was performed to evaluate the patient's symptoms. Significant stenoses were detected in the proximal left anterior descending artery (LAD), obtuse marginal artery (OM), and proximal right coronary artery (RCA) by coronary angiography. Irregular linear filling defects and haziness in the proximal RCA were also observed, which had been reported as braid-like stenosis (Fig. 1). We suspected only balloon angioplasty had been performed at the initial PCI because no stent was observed in the RCA. We diagnosed the LAD and OM stenoses to be the culprit lesions and performed PCI for them. Dual anti platelet therapy (aspirin 100 mg/day and clopidogrel sulfate 75 mg/day), diltiazem hydrochloride 100 mg/day and nicorandil 150mg/day were administered after PCI. Angina on effort continued even after PCI for LAD and OM lesions. Thus, we performed PCI for the RCA lesion one month later. As a routine strategy at our institution, our patient first underwent IVUS. A commercial scanner (Boston Scientific, Marlborough, MA, USA), consisting of a rotating 40 MHz transducer within a 3.2-F imaging sheath was used for IVUS. OCT images were acquired

using an occlusive technique, using a commercially available system for intracoronary imaging and a 0.019-inch ImageWire™ (LightLab Imaging, Westford, MA, USA). Because the IVUS catheter did not pass through the most proximal stenosis, dilatation with a small balloon (1.3×10 mm Lacrosse balloon™; Goodman Co, LTd, Nagoya, Japan) was performed. IVUS (Fig. 2) revealed the multiple channels in the vessel and the different channels were found to be connected to different side branches, which originated from both edges of the stenosis. Using OCT (Fig. 3), we found that the lesion was composed of the proximally located most severe stenosis and a distal stenosis involving multiple channels, maximally five in a cross section; moreover, it started at a side branch and ended at the other one, both of which also formed the lumens. The most severe stenosis had a thick septum with homogeneous high-intensity. In the distal stenosis, multiple lumens were separated by high-intensity thin septa. Proximally and distally, the channels converged into a single lumen. Multiple lumens and septa in the stenosis could be detected more clearly via OCT than via IVUS (Figs. 2 and 3). As the most severe stenosis seemed to be very hard, we used a Cutting balloon™ (2.5×10 mm; Boston Scientific, Marlborough, MA, USA), expecting a lesion modification (Figs. 4 and 5) before stent implantation. An Endeavor stent™ (3.0×18 mm; Medtronic, Minneapolis, MN, USA) was implanted to cover the whole stenosis (Fig. 6). Because OCT detected residual lumen outside the stent, an additional dilatation with Powered lacrosse™ (3.25×12 mm; Goodman Co, LTd, Nagoya, Japan) was performed (Fig. 6). Final coronary angiography findings showed excellent results (Fig. 7). Unfortunately, we neglected stress test to evaluate myocardial ischemia before PCI for the RCA. Symptoms of our patient disappeared after PCI for the RCA lesion.

3. DISCUSSION

In this case, IVUS and OCT were found to be beneficial for the evaluation and treatment of coronary artery structure with a braid-like appearance in a patient with prior MI. OCT-guidance enabled the operator to evaluate the intra luminal structure (including the thickness and the intensity of the septa), leading to the use of The Cutting balloon™ (Boston Scientific, Marlborough, MA, USA).

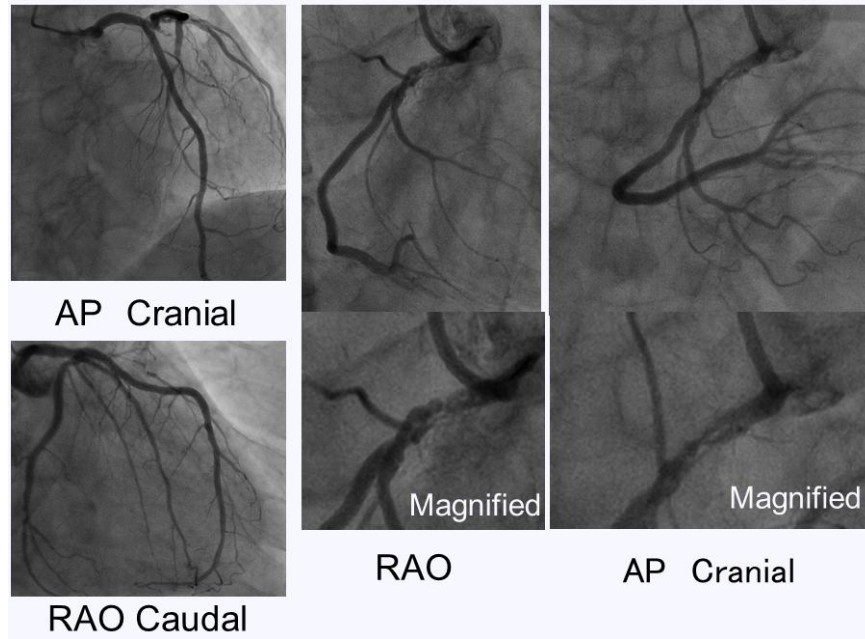


Fig. 1. Baseline coronary angiography before PCI for the RCA lesion.

Left coronary angiography shows satisfactory results without restenosis in the LAD and OM. Right coronary angiography reveals an unusual stenotic lesion resembling a braided grid in the proximal RCA
Abbreviations: PCI, percutaneous coronary intervention; RCA, right coronary artery; LAD, left anterior descending artery; OM, obtuse marginal artery; AP, anteroposterior; RAO, right anterior oblique

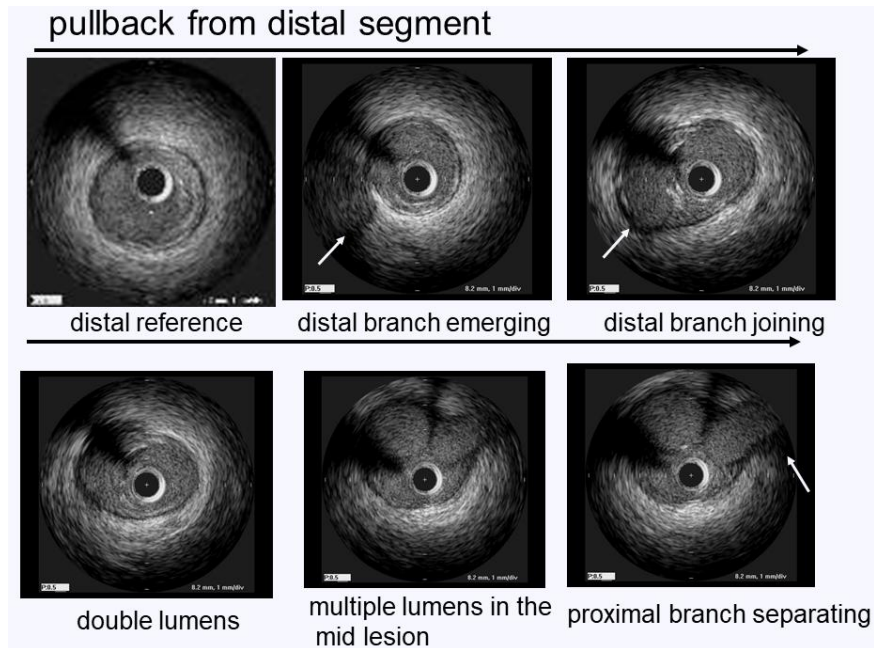


Fig. 2. IVUS images during automatic pullback after dilatation with a small balloon

IVUS clearly shows the relationship between the two side branches and the main vessel. A distal side branch approaches the main vessel and enters the main vessel to compose the multiple lumens. One of the multiple lumens separates from the main vessel and connects to a proximal side branch. The white arrows indicate the side branches

Abbreviation: IVUS, intravascular ultrasound

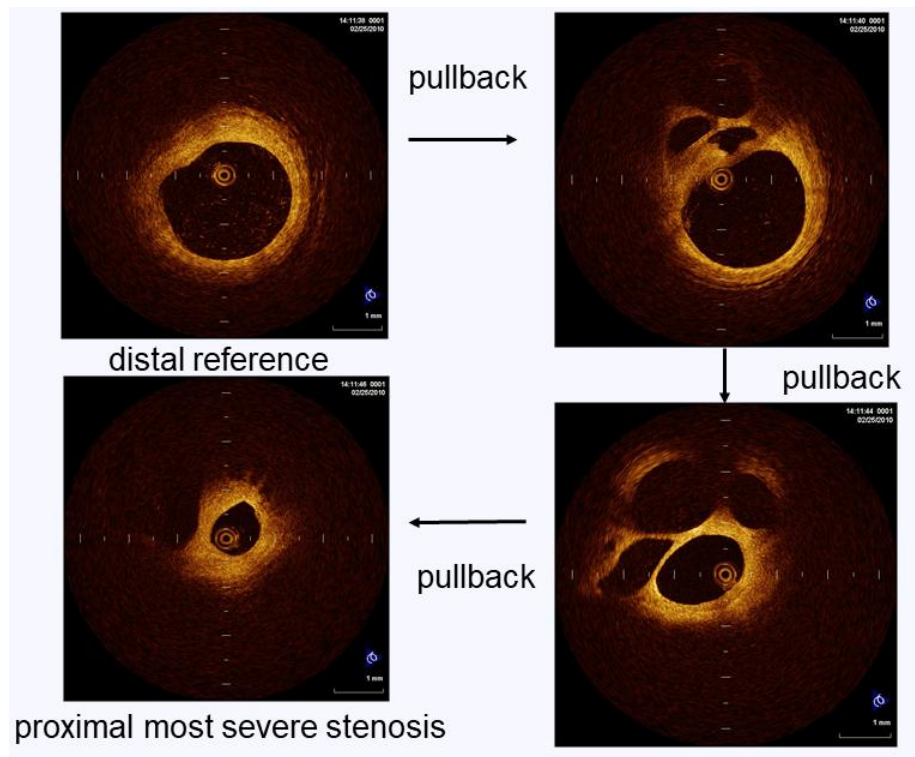


Fig. 3. Optical coherence tomography images during automatic pullback following dilatation with a small balloon

The most severe stenosis in the proximal lesion has a homogeneous and high-intensity thick septum. In the distal lesion, multiple lumens are separated by high-intensity thin septa

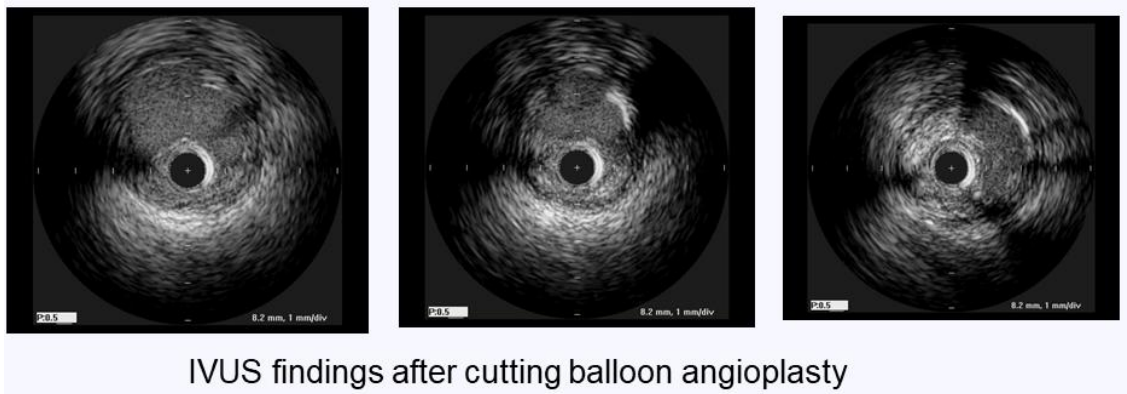


Fig. 4. Intravascular ultrasound findings following Cutting balloon™ (Boston Scientific, Marlborough, MA, USA) angioplasty

Multiple lumens are found to be united, generating an enlarged lumen

3.1 Benefits of OCT

OCT enabled us to observe multiple lumens and septa clearly. This is impossible using conventional methods such as angiography and IVUS. The Cutting balloon™ (Boston Scientific,

Marlborough, MA, USA) had been known as a lesion modification device for hard plaques with severe calcification [7]. In this patient, we successfully dilated the proximal stenosis and cut the inter-luminal septa with a Cutting balloon prior to stent implantation. OCT could clarify the

etiology of angiographic ambiguity. Nakanishi et al. successfully protected the side branches via placement of the guidewires in them to prevent obstruction during PCI for the main vessel, owing

to the provision of IVUS information [2]. In our case, we did not protect the side branches in this patient because of their small branch size.

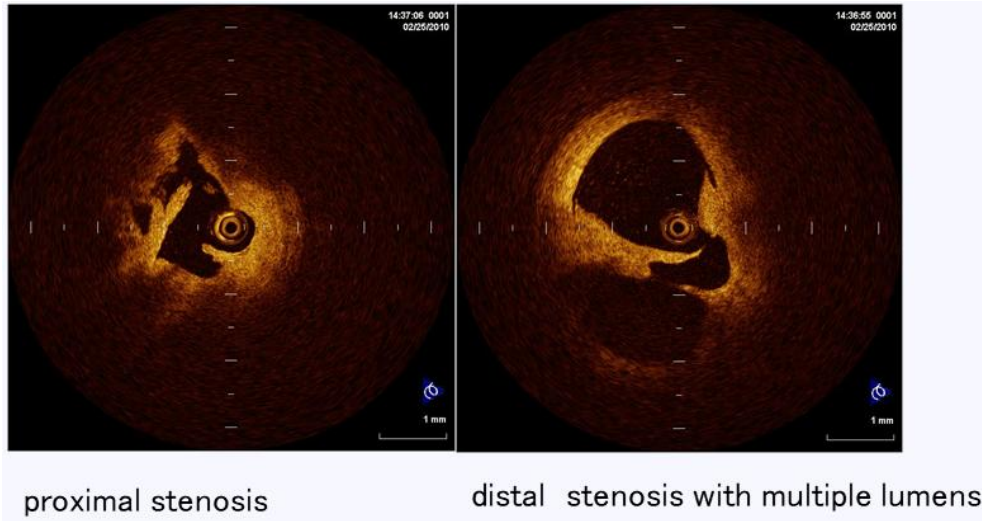


Fig. 5. OCT findings after Cutting balloon™ (Boston Scientific, Marlborough, MA, USA) angioplasty

The fractured septa can be observed clearly. The most proximal stenosis is dilated and lumen is widened, with irregular borders

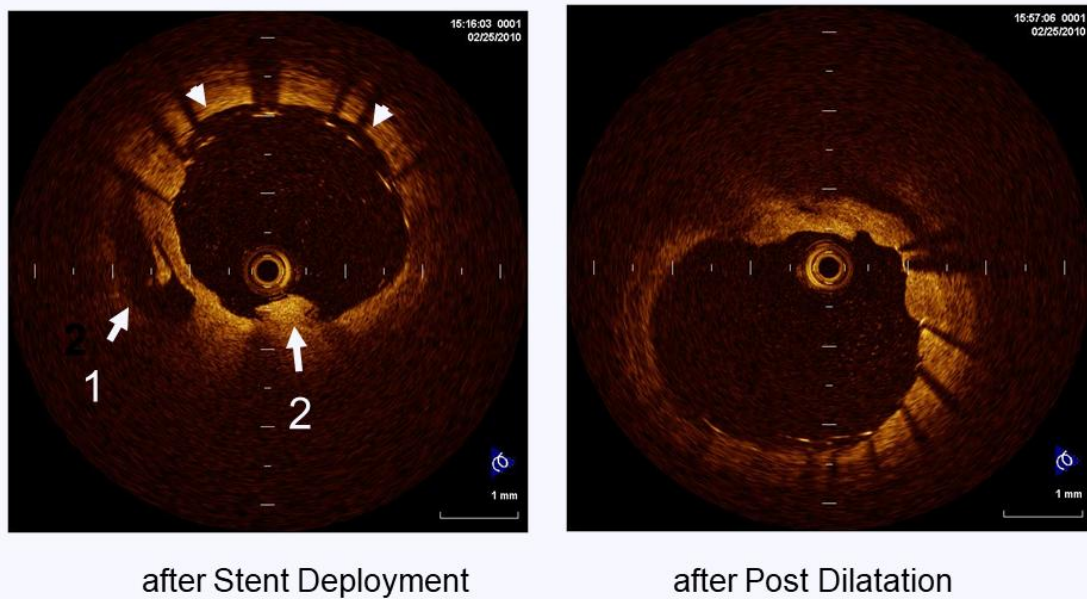


Fig. 6. OCT images before and after the additional dilatation

Mal-apposition (white arrow heads), side-by-side residual lumen outside the implanted stent (white arrow 1), and protrusion on the stent (white arrow 2) are observed. The residual lumen outside the stent is completely compressed and the mal-apposition is corrected via an additional dilatation at a high pressure after stent implantation

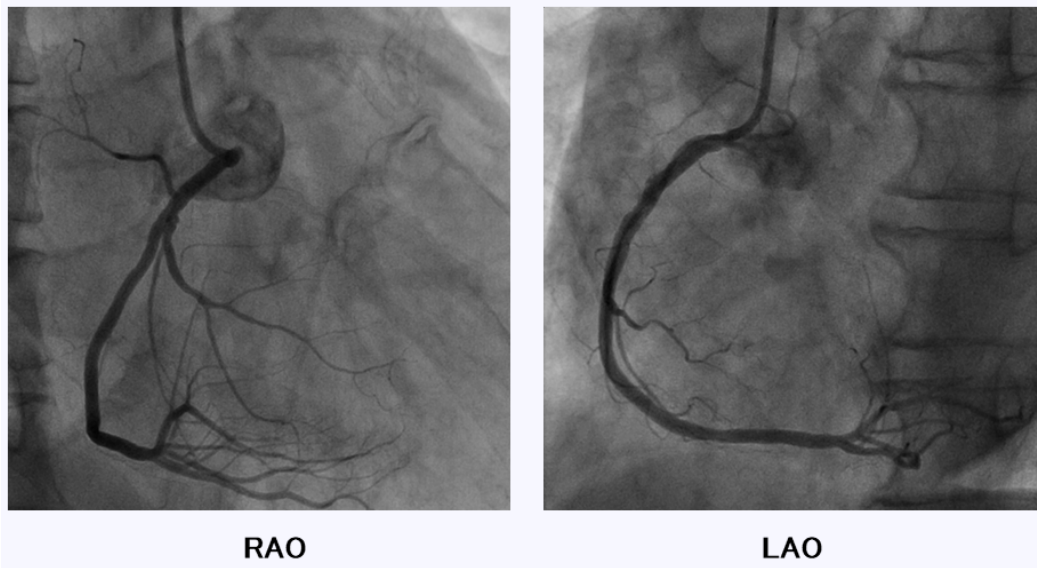


Fig. 7. Final coronary angiography
Excellent results without dissection or slow flow are obtained

4. LIMITATIONS IN THIS CASE REPORT

A stress test for myocardial ischemia was not performed before PCI in this case. Although we decided to treat the LAD and OM lesions first based on the angiographic findings, the coronary angiograms of the LAD and OM lesion before PCI could not be shown.

Written informed consent was obtained from the patient prior to performing the diagnostic and therapeutic procedures, and for the publication of this report. There are no conflicts of interest to report.

5. CONCLUSIONS

IVUS and OCT were beneficial for the evaluation of coronary artery structure with a braid-like appearance. We used OCT as a guide for PCI.

CONSENT

As per international standard or university standard, patient's written consent has been collected and preserved by the authors.

ETHICAL APPROVAL

It is not applicable.

COMPETING INTERESTS

Author has declared that no competing interests exist.

REFERENCES

1. Kang SJ, Nakano M, Virmani R, Song HG, Ahn JM, Kim WJ, Lee JY, Park DW, Lee SW, Kim YH, Lee CW, Park SW, Park SJ. OCT findings in patients with recanalization of organized thrombi in coronary arteries. *JACC Cardiovasc Imaging*. 2012;5:725-732.
2. Nakanishi T, Kawata M, Matsuura T, Kuroda M, Mori K, Hirayama Y, Adachi K, Matsuura A, Sakamoto S. A case of coronary lesion with lotus root appearance treated by percutaneous coronary intervention with intravascular ultrasound guidance. *Cardiovasc Interv Ther*. 2010;25:131-134
3. Koyama K, Yoneyama K, Mitarai T, Kuwata S, Ishibashi Y, Kongoji K, Akashi YJ. Instant protrusion after implantation of a drug-eluting stent in a honeycomb-like coronary artery structure: Complete resolution over 6 months and the role of optical coherence tomography imaging in the diagnosis and follow-up. *JACC Cardiovasc Interv*. 2014;7:e39-40.
4. Musashi M, Tada N, Uemura N, Kawashima O, Ootomo T, Inoue N, Abe H,

- Meguro T. Multivessel honeycomb-like structure finding in optical coherence tomography. JACC Cardiovasc Interv. 2014;7:e7-8.
5. Kimura T, Itoh T, Fusazaki T, Nakamura M, Morino Y. A honeycomb-like structure in the right coronary artery visualized by three-dimensional optical coherence tomography. Coron Artery Dis. 2015;26:356-360.
6. Terashima M, Awano K, Honda Y, Yoshino N, Mori T, Fujita H, Ohashi Y, Seguchi O, Kobayashi K, Yamagishi M, Fitzgerald PJ, Yock PG, Maeda K. Images in cardiovascular medicine. "Arteries within the artery" after Kawasaki disease: A lotus root appearance by intravascular ultrasound. Circulation. 2002;106:887.
7. Ito S, Suzuki T, Suzuki T. Adjunctive use of cutting balloon after rotational atherectomy in a young adult with probable Kawasaki disease. J Invasive Cardiol. 2003;15(5):297-300.

© 2017 Ito; This is an Open Access article distributed under the terms of the Creative Commons Attribution License (<http://creativecommons.org/licenses/by/4.0>), which permits unrestricted use, distribution, and reproduction in any medium, provided the original work is properly cited.

Peer-review history:
The peer review history for this paper can be accessed here:
<http://sciencedomain.org/review-history/20864>