



# **Complete Treatment of a Case of Medically Refractory Ulcerative Colitis with Adoption of the Health Triangle Methods for Lifestyle Modification**

**Hassan Akbari<sup>1,2</sup> and Malihe Ramezani<sup>3\*</sup>**

<sup>1</sup>*Department of Pathology, Shahid Beheshti University of Medical Sciences, Tehran, Iran.*

<sup>2</sup>*Traditional Medicine School, Tehran University of Medical Sciences, Tehran, Iran.*

<sup>3</sup>*University of Traditional Medicine of Armenia, Armenia.*

## **Authors' contributions**

*This work was carried out in collaboration between both authors. Both authors read and approved the final manuscript.*

## **Article Information**

DOI: 10.9734/JPRI/2021/v33i331160

### Editor(s):

(1) Dr. Jongwha Chang, University of Texas, USA.

### Reviewers:

(1) Walysson Alves Tocantins de Sousa, Unifacid Wyden University Center, Brazil.

(2) Hilton Arcoverde Medeiros, Hospital De Olhos Joao Eugenio, Brazil.

Complete Peer review History: <http://www.sdiarticle4.com/review-history/64998>

**Case Study**

**Received 23 November 2020**

**Accepted 27 January 2021**

**Published 20 February 2021**

## **ABSTRACT**

Ulcerative colitis (UC) is an inflammatory disease affecting the mucosa in the colon. Despite significant progress and expansion of the therapeutic armamentarium for UC, there are currently no curative medications available and some cases require colectomy. In this communication, we report the case of a 38 years old male patients with a five-year history of UC who had involvement of the entire colon and was medically refractory. The patient had received treatment with steroids, mesalazine, infliximab, and adalimumab, but failed to achieve remission in the process. He had non-remitting symptoms with endoscopic and histologic evidence of severe disease, and experienced episodes of significant lower gastrointestinal bleeding. Ultimately, the patient was advised to undergo colectomy, but he refused; instead, he adopted a lifestyle modification approach—the health triangle method. In short, this approach emphasizes three aspects of nutrition, use of herbal medicines, and interventions (called aamal-e-yadavi in Traditional Iranian Medicine) like oiling, cupping, and phlebotomy (hejamat). These interventions can improve the cellular energy balance and truly cure the autoimmune disease if adopted over the long term. After three years, the patient reported substantial improvement in symptoms, and the colonoscopy and

\*Corresponding author: E-mail: maliheramezani@gmail.com;

histology showed evidence of remission. This case indicated the potential efficacy and safety of complementary and alternative approaches in patients with UC; however, the health triangle method needs to be investigated in randomized controlled trials.

*Keywords: Ulcerative colitis; inflammatory bowel disease; health triangle; refractory ulcerative colitis.*

## 1. INTRODUCTION

Ulcerative colitis (UC) is characterized by chronic, relapsing and remitting inflammation in the colon that usually starts in the rectal mucosa and extends to proximal colonic segments [1]. The worldwide incidence and prevalence of UC are increasing [2], and its peak incidence is observed between 30 and 40 years of age [3]. The total years lost to disability have almost doubled among UC patients over the past three decades, underlining the substantial burden of the disease [4]. Despite considerable advances in treatment, there are currently no curative medications for UC and some patients might suffer from severe debilitating symptoms without achieving remission. In refractory cases, novel immunomodulating agents have shown promising results, but in up to 15 percent of patients, colectomy will be indicated at some point during the course of disease, due to either medically refractory UC or colonic dysplasia [1,5].

In addition to the expanding therapeutic armamentarium for refractory UC, complementary approaches can be considered for achieving and maintaining remission. Complementary treatments are commonly used among inflammatory bowel disease patients and include a wide array of options such as herbal remedies and exercise; however, large randomized controlled trials are yet to be reported on these therapies [6]. In this manuscript, we report a case of refractory UC in a young man who adopted a combination of complementary approaches to minimize his symptoms.

## 2. CASE

### 2.1 Patient Description

The patient was a 38 years old male who initially presented in 2015 with complaints of severe abdominal pain, frequent defecation, and massive lower gastrointestinal (GI) bleeding. He had suffered from similar symptoms for the previous five years. The pain was more severe with eating, drinking cold water, and at the time of defecation.

### 2.2 Case History

In 2015, he underwent colonoscopy and the colonic biopsy revealed cryptitis and crypt abscess formation, plus lamina propria composed of acute and chronic inflammatory cell-sand eosinophils.

### 2.3 Physical Examination Results

The patient had been referred to a team of GI specialists and diagnosed with ulcerative colitis. The differential diagnosis of early phase inflammatory bowel disease was suggested.

### 2.4 Treatment Plan

The treatment approach at first included meclizine 500 mg, azathioprine 150 mg, and prednisolone 500 mg. Metronidazole 250 mg daily was added and used for 9 months. The patient had severe hemorrhage episodes, frailty, and fatigue, which forced the medical team to refer him to a tertiary center in Tehran. The patient was hospitalized for 27 days and received rectal and oral mezalazine, hydrocortisone, and IV metronidazole. The clinical condition did not improve, resulting in intensifying treatment with 300 mg infliximab (remicade) injections which continued for 5 months after discharge. Unfortunately, the patient did not achieve remission, and asked for the opinion of another gastroenterologist, who prescribed 600 mg infliximab. At this point, due to a high dose of injection, the patient suffered cardiac arrest and, thankfully, he was resuscitated. The patient continued receiving infliximab until summer of 2016.

The next stage of treatment was initiated since the patient did not demonstrate optimal remission. Infliximab was omitted from the treatment regimen and replaced with adalimumab (Humira). Colonoscopy indicated multiple patchy ulcers along with severe erythema and congestion in the rectum and sigmoid. Moreover, mild erythema, hyperemia, and congestion in the descending colon and splenic flexure. The pathology partially ulcerated epithelium in the colonic mucosa accompanied by fibrinoleukocytic exudate. Crypt budding and branching, infiltration of lamina propria by mixed

inflammatory cells, cryptitis, and several lymphoid follicles were reported. Active chronic colitis was diagnosed while the presence of viral inclusions and dysplasia were ruled out. Evidently, the disease did not respond to the treatment regimen. A new brand of adalimumab, CinnoRA, injection was added instead of Humira, along with calcium and iron supplementation. At this stage, the medical team decided on performing colectomy due to suboptimal results achieved with maximally tolerated medications.

The patient and his family did not consent to surgery; instead, they chose a different strategy. The patient was familiar with the triangle of health methods, and had been trying this approach after referral to a health triangle center. In addition to conventional recommendations for lifestyle modification, the scheme of this therapeutic approach included six essential aspects: the weather in the area of residence, eating and drinking, sleep, motion, retention and clearance, and sensual latitudes. The health triangle emphasizes nutrition, the use of herbal medicines, and interventions (called *aamal-eyadavi* in Traditional Iranian Medicine) like oiling, cupping, and phlebotomy (*hejamat*). The nutritional recommendations were consumption of two soft boiled egg yolks daily, organic fresh vegetables every two hours, olives and local pickles, and garlic with each meal. In addition, this therapeutic approach encouraged the use of herbal remedies, mineral compounds, organic rock salt, herbal decoction instead of tea, and fruit-based snacks such as fruit grated in honey, decoctions and jams, plus baked food and bread. The health triangle method recommends several types of syrups, instead of cold or artificial drinks, and involves the use of antidote tablets. Other practices advised by this method include cupping once a month, a mild phlebotomy every three months, dry-cupping, and application of the whole back body ointment every other day for seven minutes. These interventions and lifestyle modifications are thought to improve the cellular energy balance and cure autoimmune diseases over the long term.

### 3. RESULTS

During the following visits, the patient reported full compliance with the health triangle recommendations and a reduction in the use of chemical drugs. After three years, the results were promising. The symptoms had subsided considerably, and the endoscopic and pathologic assessments showed signs of remission. In 2019, the patient underwent colonoscopy which

demonstrated a small ulcer in the rectum (Fig. 1-A), with normal mucosal and vascular pattern seen from sigmoid to 20 cm of terminal ileum (Fig. 1-B). Multiple biopsies were taken from all segments of the colon and the terminal ileum. Histology showed no evidence of UC with only mild inflammation throughout the colon (Figs. 1-C, D). No evidence of neoplasia was observed.

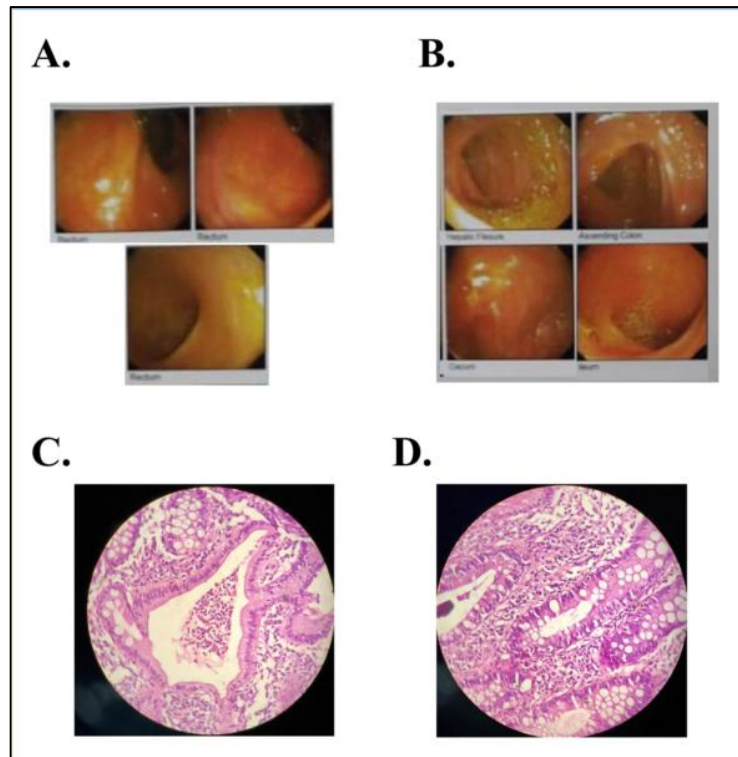
### 4. DISCUSSION

We present a case of a patient with medically refractory UC who achieved remission with adopting the health triangle method—a healthy approach in multiple lifestyle aspects.

Management of medically refractory UC is challenging, and often results in colectomy, leaving patients with a significantly reduced quality of life [5,7]. Complementary and alternative therapeutic approaches are used by more than half of inflammatory bowel disease patients [8], especially in cases where mainstream treatments do not achieve a satisfactory reduction in symptoms. The understood mechanism of UC is autoimmunity, which arises from the immune system failing to recognize the host cells from foreign antigens [9]. This disturbance stems from the energy imbalance of the cells, which can be modified by the health triangle approach. In this regard, UC patients can potentially benefit from adopting the health triangle, since it can completely cure autoimmunity through modifying cellular energy balance. Notably, patients often do not disclose their use of complementary approaches to their physicians, which can lead to confusion in both patients and doctors [6,8] and delineates the need for reliable evidence in this regard. Although there is some evidence on dietary measures, exercise, and mind-body function modifications, the diverse field of complementary and alternative treatments for UC remain largely unsupported by evidence and future studies of their clinical efficacy and safety are required.

Considering the complex pathophysiology of UC, environmental factors have been studied as both etiologic and disease modifying features [1, 7]. Diet is one of the elements influencing the disease course of UC and specific dietary habits have been investigated in this regard [10].

Moreover, dietary modifications have been shown to be synergistically enhanced by addition of exercise [11]. Habitual physical activity can improve gut health and reduce inflammation via altering immune cell homeostasis and microbiota-body interactions [12].



**Fig. 1. A. the rectal mucosa with a small ulcer; B. the healed colonic mucosa with minor involvement; C. & D. histology of the colonic mucosa showing mild chronic colitis**

## 5. CONCLUSION

The proposed therapy was efficient in promoting clinical and endoscopic remission of ulcerative colitis and that this may be an approach to be considered in patients refractory to conventional therapy.

## CONSENT

The patients gave written informed consent for anonymous publication of this case report.

## ETHICAL APPROVAL

It is not applicable.

## COMPETING INTERESTS

Authors have declared that no competing interests exist.

## REFERENCES

1. Ungaro R, Mehandru S, Allen PB, Peyrin-Biroulet L, Colombel JF. Ulcerative colitis. *Lancet*. 2017;389(10080):1756-1770.

2. DOI:10.1016/S0140-6736(16)32126-2  
Molodecky NA, Soon IS, Rabi DM, et al. Increasing incidence and prevalence of the inflammatory bowel diseases with time, based on systematic review. *Gastroenterology*. 2012;142(1). DOI:10.1053/j.gastro.2011.10.001
3. Cosnes J, Gowerrousseau C, Seksik P, Cortot A. Epidemiology and natural history of inflammatory bowel diseases. *Gastroenterology*. 2011;140(6):1785-1794.e4. DOI:10.1053/j.gastro.2011.01.055
4. GBD 2017 Inflammatory Bowel Disease Collaborators. The global, regional, and national burden of inflammatory bowel disease in 195 countries and territories, 1990–2017: A systematic analysis for the global burden of disease study 2017. *Lancet Gastroenterol Hepatol*. 2020;5(1):17-30. DOI:10.1016/S2468-1253(19)30333-4
5. Magro F, Rodrigues A, Vieira AI, et al. Review of the disease course among adult ulcerative colitis population-based longitudinal cohorts. *Inflamm Bowel Dis*. 2012;18(3):573-583.

- DOI:10.1002/ibd.21815
6. Lin SC, Cheifetz AS. The use of complementary and alternative medicine in patients with inflammatory bowel disease. *Gastroenterol Hepatol.* 2018;14(7):415-425. DOI:10.14309/00000434-201210001-01689
  7. Ordás I, Eckmann L, Talamini M, Baumgart DC, Sandborn WJ. Ulcerative colitis. In: *The Lancet.* Lancet. 2012; 380:1606-1619. DOI:10.1016/S0140-6736(12)60150-0
  8. Cheifetz AS, Gianotti R, Luber R, Gibson PR. Complementary and alternative medicines used by patients with inflammatory bowel diseases. *Gastroenterology.* 2017;152(2):415-429.e15. DOI:10.1053/j.gastro.2016.10.004
  9. Sartor RB. Mechanisms of disease: pathogenesis of Crohn's disease and ulcerative colitis. *Nat Clin Pract Gastroenterol Hepatol.* 2006;3(7):390-407. DOI:10.1038/ncpgasthep0528
  10. Keshteli AH, Madsen KL, Dieleman LA. Diet in the pathogenesis and management of ulcerative colitis; A review of randomized controlled dietary interventions. *Nutrients.* 2019;11(7). DOI:10.3390/nu11071498
  11. Stavsky J, Maitra R. The synergistic role of diet and exercise in the prevention, pathogenesis, and management of ulcerative colitis: An underlying metabolic mechanism. *Nutr Metab Insights.* 2019;12:117863881983452. DOI:10.1177/1178638819834526
  12. Cook MD, Allen JM, Pence BD, et al. Exercise and gut immune function: Evidence of alterations in colon immune cell homeostasis and microbiome characteristics with exercise training. *Immunol Cell Biol.* 2016;94(2):158-163. DOI:10.1038/icb.2015.108

© 2021 Akbari and Ramezani; This is an Open Access article distributed under the terms of the Creative Commons Attribution License (<http://creativecommons.org/licenses/by/4.0>), which permits unrestricted use, distribution, and reproduction in any medium, provided the original work is properly cited.

*Peer-review history:*

*The peer review history for this paper can be accessed here:  
<http://www.sdiarticle4.com/review-history/64998>*