



Pseudo Vaginoscopy: A Modified Vaginoscopy Technique for Outpatient Hysteroscopy in Cases with Difficult Access

**Fouzia Rasool Memon¹, Nusrat Fozia Pathan², Asma Naz³, Hazooran Lakan⁴,
Shahida Baloch⁵, Umer Farooque Memon⁶ and Arslan Ahmer^{7*}**

¹Consultant Obstetrician and Gynaecologist, North Cumbria University Hospital, United Kingdom.

²Department of Obstetrics and Gynaecology, Khairpur Medical College, Khairpur Mirs, Sindh, Pakistan.

³Department of Obstetrics and Gynaecology, People's University of Medical and Health Sciences for Women (PUMHSW), Nawabshah, Sindh, Pakistan.

⁴Department of Obstetrics and Gynaecology, Ghulam Muhammad Mahar Medical College (GMMMC), Sukkur, Sindh, Pakistan.

⁵Department of Surgery, People's University of Medical and Health Sciences for Women (PUMHSW), Nawabshah, Sindh, Pakistan.

⁶Medical, Nottingham University, United Kingdom.

⁷Institute of Pharmaceutical Sciences, People's University of Medical and Health Sciences for Women (PUMHSW), Nawabshah, Sindh, Pakistan.

Authors' contributions

This work was carried out in collaboration among all authors. Author FRM designed the study, performed the statistical analysis, wrote the protocol and wrote the first draft of the manuscript. Authors NFP, AN, HL, SB, UFM and AA managed the analyses of the study and managed the literature searches. All authors read and approved the final manuscript.

Article Information

DOI: 10.9734/JPRI/2021/v33i28A31517

Editor(s):

(1) Dr. Prabakaran Nagarajan, The Ohio State University, USA.

Reviewers:

(1) Shashwati Sen, Mohak Hospital, India.

(2) Marzieh Ghasemi, Zahedan University of Medical Sciences, Iran.

Complete Peer review History: <http://www.sdiarticle4.com/review-history/68409>

Original Research Article

Received 27 February 2021

Accepted 04 May 2021

Published 05 May 2021

ABSTRACT

Background: Outpatient hysteroscopy is a safe, reliable and cost-effective alternative to hysteroscopy under a general anaesthetic for the diagnosis of abnormal uterine bleeding.

Objectives: The objective of this study was to introduce new technique of pseudo-vaginoscopy for

*Corresponding author: E-mail: arslan.ahmer@gmail.com;

better movement of hysteroscope and less procedural pain. Also to assess acceptability of patients for outpatient hysteroscopy when appropriate analgesia was given prior to the procedure. **Methodology:** A prospective study was conducted of 74 women attending for outpatient hysteroscopy at the West Cumberland Hospital over a period of one year. Selection criteria include very narrow and atrophic vagina and failed speculum examination in gynaecology outpatient clinics. **Results:** Of the women studied, 95.5% stated that they would recommend the procedure to friends in future, whilst 5.8% would not want to go through it again. The type of anaesthetic administered during the procedure seem to influence whether women would attend for outpatient hysteroscopy in future. **Conclusion:** Our pseudo-vaginoscopic approach allows more freedom for the scope movements not limited by the speculum with the advantage of prior cervical preparation. It was certainly at value for operative outpatient hysteroscopy in patients with very high BMI where access was difficult owing to depth.

Keywords: Pseudo vaginoscopy; outpatient; hysteroscopy.

1. INTRODUCTION

Outpatient hysteroscopy is an established diagnostic test that is in widespread use across the UK. It is indicated preliminarily in the assessment of women with abdominal uterine bleeding [1].

More recently advances in endoscopic technology and ancillary instrumentation have facilitated the development of operative hysteroscopic procedures in an outpatient setting with or without the use of local anaesthesia [2].

However, as with any procedure requiring instrumentation of the uterus outpatient hysteroscopy can be associated with significant pain anxiety and embarrassment [3].

This not only impacts upon women's satisfaction with their experience, but also limits the feasibility and possibly the safety accuracy and effectiveness of the procedure [4].

To minimise pain and discomfort, variations in hysteroscopic equipment adaptations to the technique and use of pharmacological agents have been advocated [5].

Vaginoscopy refers to a technique where the hysteroscope is introduced into the vagina through the cervical canal and into the uterine cavity without the need for a vaginal speculum or cervical instrumentation. Vaginoscopy technique requires thinner scopes and avoids potential vaginal and cervical manipulation. However, there is unknown chance of success given potential cervical stenosis and missing the benefits of cervical block [6].

Vaginoscopy is the recommended standard technique for outpatient hysteroscopy, especially where successful insertion of a vaginal speculum is anticipated to be difficult and where blind endometrial biopsy is not required [7].

Vaginoscopy confers the advantage of increased external movement of the hysteroscope and is associated with significantly less procedural pain however the feasibility of Vaginoscopy in relation to the characteristics of the woman such as body mass index, menopausal status and parity are less well studied. These characteristics inevitably call for a modification to the standard technique to reap the advantages of the vaginoscopic approach minimising the risk of failure of procedure [8].

2. METHODOLOGY

A prospective audit was conducted on 74 women attending for outpatient hysteroscopy at the West Cumberland Hospital over a period of one year. Selection criteria include very narrow and atrophic vagina and failed speculum examination in gynaecology outpatient clinics. Data were analysed using SPSS version 22.

2.1 Technique

1. Local anaesthetic gel is used to prepare the vagina to allow Cusco's speculum and cervical preparation
2. Cervical block to prepare the cervix
3. Cervical dilatation (if required) after stabilisation with tenaculum
4. Then, there is the option of withdrawing all instruments to allow vaginoscopic approach (with the cervix prepared and accessible) OR

5. If cervical traction is required, passing another tenaculum sideways through the speculum's blades to hold the cervix and then disengaging the other instruments.

74. Sixty five (95.5%) would recommend it if done this way to a friend. Four women (5.8%) showed dissatisfaction due to pain during the procedure and would not want to go through it again.

3. RESULTS AND DISCUSSION

Seventy four (74) women were selected for this prospective study. Pseudovaginoscopy was performed in all of them and a patient satisfaction survey was performed from the participants after the completion of procedure. This technique was perfected over 20 hysteroscopy episodes before it was standardised to be studied at our outpatient hysteroscopy suite for cases with difficulties in access.

The majority women were under the BMI of 30 and the principal indication of referral was postmenopausal bleeding. The women selected for this study had narrow and stenosed vagina and failed examination with speculum when seen in gynaecology outpatient clinics.

Pseudovaginoscopy performed in all the cases by using technique as mentioned above. The rate of accessing the cavity was 100%. Failure to remove pathology in the actual episodes 3/74 (4.1%). One could not tolerate pain, in other patient polyp cut but could not retrieve. In the last case pathology could not be removed. All of the failed cases underwent hysteroscopy under GA.

After the procedure a patient satisfaction survey was conducted. Sixty eight women replied out of

Our technique of pseudo-vaginoscopy and results of the study have shown that all the patient who had optimum analgesia in the form of local anaesthetic gel in the vagina tolerated speculum examination. We used instillagel as local anaesthetic gel. The primary outcome measures included [9] success of the procedure, defined as adequate inspection of the entire endometrial cavity including the uterine cornua, tubal ostia, uterine fundus, lateral walls, anterior and posterior walls, and cervical canal); [10] duration of hysteroscopy, defined as the interval between introduction of the speculum to completion of diagnostic hysteroscopy using the traditional approach or introduction of the hysteroscope using the vaginoscopic approach; [11] duration of endometrial biopsy, defined as the interval between completion of the diagnostic hysteroscopy and removal of the biopsy device from the uterine cavity; [12] adequacy of endometrial biopsy; and [13-14] adverse events.

The secondary outcome measure was pain score using a 10-point visual analog scale: 0 = no pain; 10 = worst possible pain. Women were asked to give pain scores before, during and immediately after the procedure by a nurse who scored their degree of pain during the procedure.

Table 1. Mean age of patients, BMI and indication for referral for outpatient hysteroscopy on patients with difficult access

Patient Demographics	(N=74)
Age (years, mean±SD)	51.8±12.8
BMI	
<30 (n 46)	62.2%
31-40 (n 18)	24.3%
41-50 (n 6)	8.1%
>50 (n 4)	5.4%
Indication of referral	
Postmenopausal bleeding	63%
Postmenopausal bleeding/Postcoital bleeding	4%
Postmenopausal bleeding on HRT	5%
Pyometra	1%
Incidental increased endometrial thickness	9%
Intermenstrual bleeding	2%
Menorrhagia	8%
Perimenopausal bleeding	8%

Before discharge from the hospital, women were interviewed about their experience with the procedure in terms of acceptability (very acceptable, fairly acceptable, or not acceptable), whether they would recommend the procedure to a friend who required the procedure (yes or no), and whether they would agree to have outpatient hysteroscopy with pseudo-

vaginostomy if they needed the same procedure in the future.

Few studies have been published in the literature where different modalities were applied to reduce pain during the procedure and improves patient satisfaction.

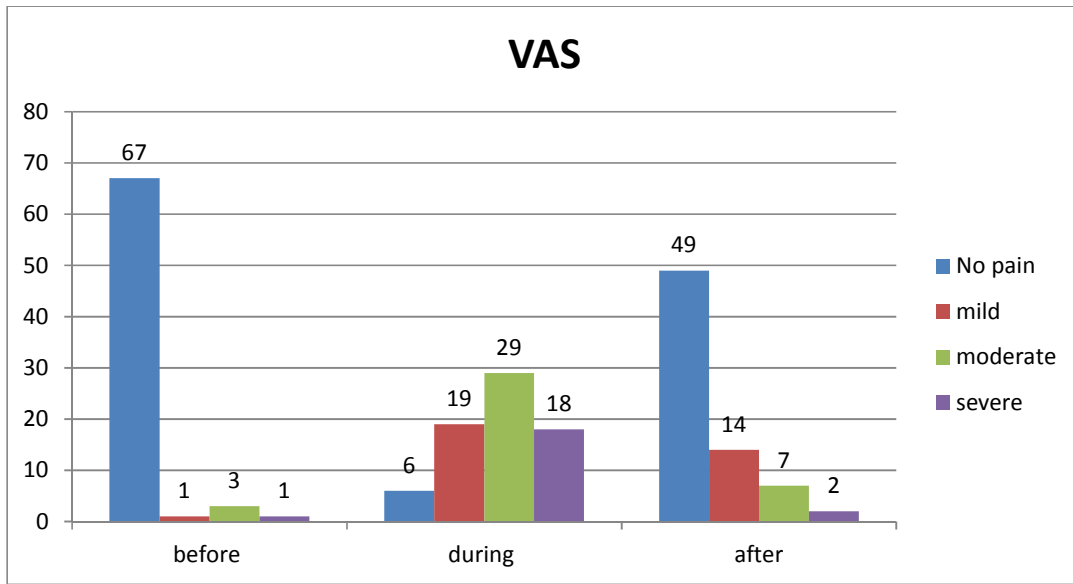


Fig. 1. Pain score using visual analog scale (VAS)

Table 2. Results of the following studies on the use of different methods to reduce pain during hysteroscopy

Author	N	Outcomes
Daive et al ¹	175	Our findings demonstrate that removal of endometrial polyps using the 16F mini-resectoscope in an office setting is a feasible and safe surgical option. Outpatient see-and-treat polypectomy is an acceptable and effective alternative to inpatient resectoscopic polypectomy.
Christina et al ²	106	Nitrous oxide is a safe and effective analgesic technique for polypectomy office hysteroscopy compared with the paracervical infiltration and control groups
Hikmet et al ³	158	We were unable to demonstrate a benefit in pain reduction and patient acceptance with the use of vaginal misoprostol or rectal NSAIDs during vaginostomy

Author	N	Outcomes
Cooper N et al ⁵	Systemic review	diagnostic outpatient hysteroscopy in nulliparous infertile women without a history of cervical stenosis There is no evidence to recommend the routine administration of mifepristone or misoprostol to women before outpatient hysteroscopy. Cervical priming with vaginal prostaglandins may be considered in postmenopausal women if using hysteroscopic systems >5 mm in diameter
Cooper N et al ⁶	Systemic review	The vaginoscopic approach to outpatient hysteroscopy is successful and significantly reduces the pain experienced by patients during the procedure, compared with traditional techniques using a vaginal speculum. Vaginoscopy should become standard practice for endoscopic instrumentation of the uterine cavity in the outpatient setting

One study has shown reduction in pain when used for hysteroscopy⁷.

4. CONCLUSION

Our pseudo-vaginoscopic approach allows more freedom for the scope movements not limited by the speculum with the advantage of prior cervical preparation. It was certainly at value for operative outpatient hysteroscopy in patients with very high BMI where access was difficult owing to depth.

Pseudo-vaginoscopy eliminates the risk of missed cancers of vulva, vagina and cervix, readily appreciated by naked eye inspection of the vulva and speculum examination.

CONSENT

As per international standard or university standard, patients' written consent has been collected and preserved by the author(s).

ETHICAL APPROVAL

As per international standard or university standard written ethical approval has been collected and preserved by the author(s).

COMPETING INTERESTS

Authors have declared that no competing interests exist.

REFERENCES

- Gordts S, Grimbizis G, Campo R. Symptoms and classifications of uterine adenomyosis, including the place of hysteroscopy in diagnosis. *Fertil Steril*. 2018;109:380–388.
- Lagana AS, Vitale SG, Muscia V, Rossetti P, Buscema M, Triolo O, et al. Endometrial preparation with Dienogest before hysteroscopic surgery: a systematic review. *Arch Gynecol Obstet*. 2017; 295:661–67.
- Uglietti A, Buggio L, Farella M, Chiaffarino F, Dridi D, Vercellini P, et al. The risk of malignancy in uterine polyps: A systematic review and meta-analysis. *Eur J Obstet Gynecol Reprod Biol*. 2019;237:48–56.
- Luerti M, Vitagliano A, Di Spiezio Sardo A, Angioni S, Garuti G, De Angelis C.

- Effectiveness of hysteroscopic techniques for endometrial polyp removal: The Italian Multicenter Trial. Italian School of Minimally Invasive Gynecological Surgery Hysteroscopists Group. J Minim Invasive Gynecol. 2019;26:1169–76.
5. Prevention of infection after gynecologic procedures. ACOG Practice Bulletin No. 195. American College of Obstetricians and Gynecologists. Obstet Gynecol. 2018; 131:e172–189.
 6. Ahmad G, Saluja S, O'Flynn H, Sorrentino A, Leach D, Watson A. Pain relief for outpatient hysteroscopy. Cochrane Database of Systematic Reviews. 2017; Issue 10. Art. No.: CD007710. DOI: 10.1002/14651858.CD007710.pub3.
 7. Deutsch A, Sasaki KJ, Cholkeri-Singh A. Resectoscopic surgery for polyps and myomas: a review of the literature. J Minim Invasive Gynecol. 2017;24:1104–10.
 8. Li C, Dai Z, Gong Y, Xie B, Wang B. A systematic review and meta-analysis of randomized controlled trials comparing hysteroscopic morcellation with resectoscopy for patients with endometrial lesions. Int J Gynaecol Obstet. 2017;136:6–12.
 9. Davide Dealberti MD, Francesca Riboni MD, Stefano Cosma MD, Carla Pisani MD, Fabio Montella MD, Salvatore Saitta MD, Gloria Calagna MD and Attilio Di SpiezioSardo MD, PhD. Feasibility and Acceptability of Office-Based Polypectomy With a 16F Mini-Resectoscope: A Multicenter Clinical Study. Journal of Minimally Invasive Gynecology, The. 2016-23(3):418-424.
 10. Cristina del Valle Rubido MD, Juan Antonio SolanoCalvo MD, PhD, Antonio Rodríguez Miguel MD, Juan José Delgado Espeja MD, Jerónimo González Hinojosa MD and Álvaro ZapicoGoñi MD, PhD. Inhalation Analgesia With Nitrous Oxide Versus Other Analgesic Techniques in Hysteroscopic Polypectomy: A Pilot Study Journal of Minimally Invasive Gynecology, The. 2015;22(4):595-600.
 11. Hikmet Hassa MD, Yunus Aydin MD, TufanOge MD and KiymetCicek MD . Effectiveness of Vaginal Misoprostol and Rectal Nonsteroidal Anti-Inflammatory Drug in Vaginoscopic Diagnostic Outpatient Hysteroscopy in Primarily Infertile Women: Double-Blind, Randomized, Controlled Trial. Journal of Minimally Invasive Gynecology, The. 2013;20(6):880-885
 12. [Ahmad G, O'Flynn H, Attarbashi S, Duffy JM, Watson A Cooper N, Smith P, Khan K, Clark T. Does cervical preparation before outpatient hysteroscopy reduce women's pain experience?A systematic review. BJOG. 2011;118:1292–1301.
 13. Cooper N, Smith P, Khan K, Clark T. Does cervical preparation before outpatient hysteroscopy reduce women's pain experience?A systematic review. BJOG. 2011;118:1292–1301.
 14. Cooper N, Smith P, Khan K, Clark T. Vaginoscopic approach to outpatient hysteroscopy: a systematic review of the effect on pain. BJOG. 2010;117:532–539.

© 2021 Memon et al.; This is an Open Access article distributed under the terms of the Creative Commons Attribution License (<http://creativecommons.org/licenses/by/4.0>), which permits unrestricted use, distribution, and reproduction in any medium, provided the original work is properly cited.

Peer-review history:
The peer review history for this paper can be accessed here:
<http://www.sdiarticle4.com/review-history/68409>