



Perineal Ectopic Testis: A Rare Case of Congenital Anomaly

**S. N. Jatal^{a*}, Sudhir Jatal^{b++}, Supriya Jatal^{c#}
and Shubhangi Jatal^{d†}**

^a Jatal Hospital and Research Centre, Latur, India.

^b Jatal Hospital and Research Centre, Latur, Tata Hospital, Mumbai, India.

^c Fellow in Clinical Nephrology, MGM Hospital & College, Navi Mumbai, India.

^d HBT hospital, Jogeshwari, Mumbai, India.

Authors' contributions

This work was carried out in collaboration among all authors. All authors read and approved the final manuscript.

Article Information

Open Peer Review History:

This journal follows the Advanced Open Peer Review policy. Identity of the Reviewers, Editor(s) and additional Reviewers, peer review comments, different versions of the manuscript, comments of the editors, etc are available here: <https://www.sdiarticle5.com/review-history/112465>

Case Study

Received: 25/11/2023

Accepted: 30/01/2024

Published: 03/02/2024

ABSTRACT

Perineal ectopic testis is an uncommon congenital anomaly observed in less than 1% of undescended testis cases. Typically, it arises from either an overdeveloped lengthening of a segment of the gubernaculum or an obstruction at the entrance to the scrotum. Diagnosis is usually straightforward through a physical examination of the ectopic regions and an empty scrotum on the same side. While imaging techniques such as ultrasonography and tomography may rarely be necessary, it is predominantly identified during childhood, with its occurrence being even rarer in adults and young boys. The recommended and widely accepted treatment for perineal ectopic testis is open orchiopexy.

We present a 5 years boy with empty left scrotum and there was a palpable left testicle in the left perineum, which confirmed by ultrasonography. Left dartos pouch orchidopexy done through inguinal incision.

⁺⁺ Fellow in Colorectal Cancer;

[#] Assistant professor and Fellow in Clinical Nephrology;

[†] Specialist medical consultant;

^{*}Corresponding author: E-mail: jatalhospital@gmail.com;

Keywords: Perineal ectopic testis; cryptorchidism; orchiopexy.

1. INTRODUCTION

Ectopic testes can be found in various locations, with common sites including the superficial inguinal pouch, perineum, crossed testicular ectopic, femoral canal, and the pubo-penile region. The most prevalent site, accounting for 75% of cases, is the superficial inguinal pouch, followed by perineal ectopic testes as the second most common anomaly. John Hunter first described perineal ectopic testes in 1786. Diagnosis is typically straightforward, relying on the observation of an empty scrotum and swelling in the perineal region on the same side. Palpation of the testis aids in confirming the diagnosis [1,3,5].

According to guidelines from the British Association of Paediatric Urologists, early orchidopexy is recommended to minimize the

risk of infertility. The procedure should be performed between 6 and 18 months of life. Orchidopexy involves an open surgical approach [2,4,6].

2. CASE REPORT

On October 12, 2020, a 5-year-old boy was brought to our centre with a history of a left empty scrotum since birth. Upon physical examination, the left hemiscrotum was found to be empty, and the left testicle could not be palpated in the scrotum. The right hemiscrotum and right testicle appeared normal. A lump was identified in the left perineal region, beneath which a palpable mass suggestive of a testicle was detected. Ultrasonography confirmed the ectopic localization of the left testis in the left perineum, confirming the diagnosis of left perineal ectopic testis.

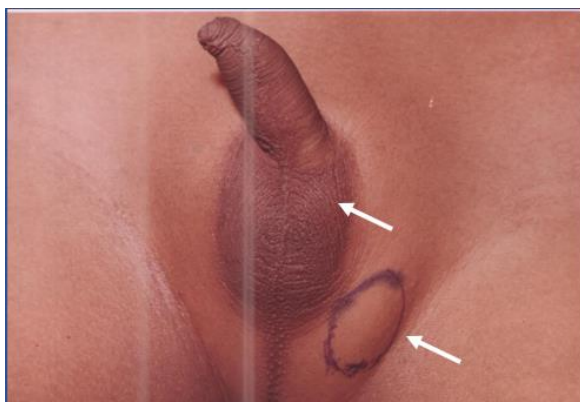

Fig. 1. Photographs showing left perineal ectopic testis with empty left scrotum

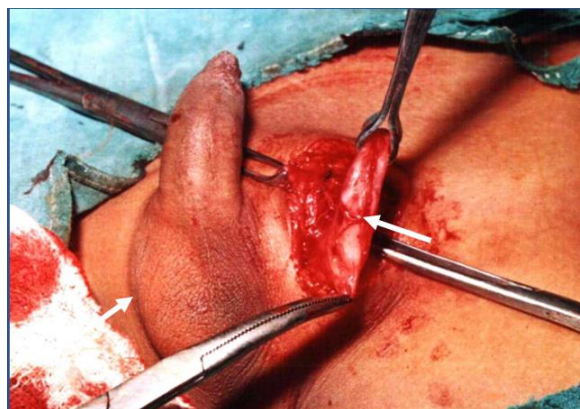

Fig. 2. Photographs showing left inguinal skin crease incision with perineal ectopic testis

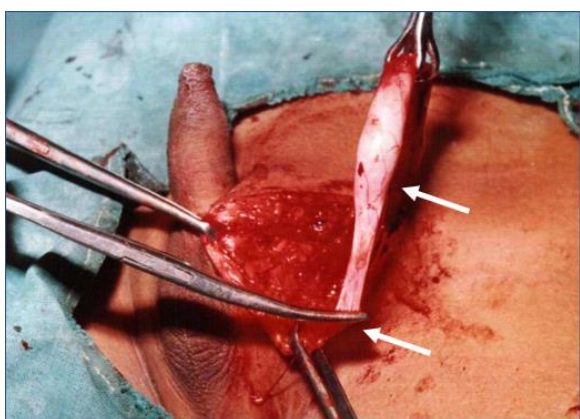


Fig. 3. Intraoperative Photographs showing normal left testis with gubernaculum

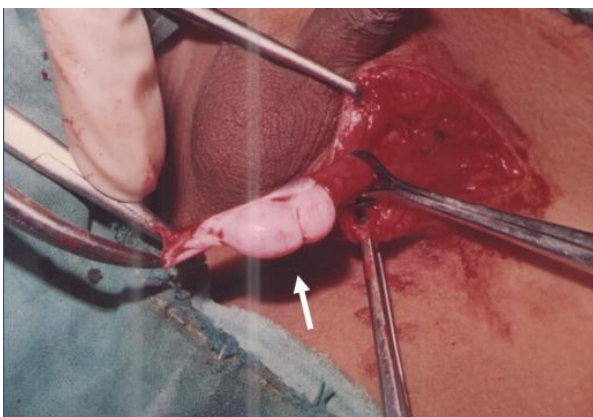


Fig. 4. Intraoperative Photographs showing normal left testis

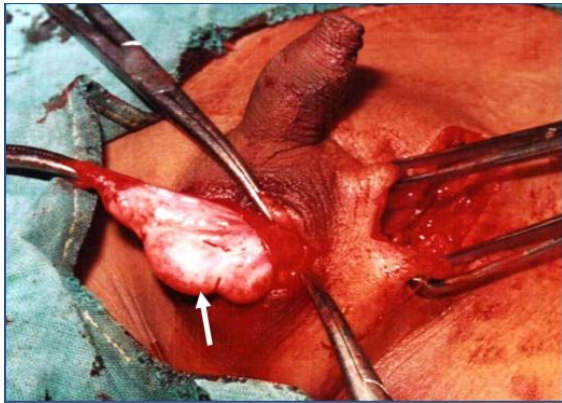


Fig. 5. Intraoperative Photographs showing Dartos pouch orchidopexy

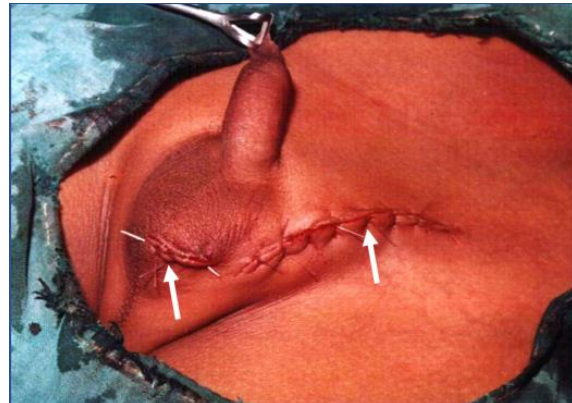


Fig. 6. Photographs showing open orchidopexy

Surgical exploration was conducted through an incision along the inguinal skin crease on the left side. The gubernaculum testis was found to be affected, involving perineal tissue. The left ectopic testis exhibited normal size and shape, with the vas and testicular vessels being elongated. The gubernaculum and ectopic testis were released from the inner side of the perineum and guided through a path created by finger dissection from the external ring to the left hemiscrotum. Subsequently, they were fixed to the left subdartal pouch and orchidopexy was performed. No congenital inguinal hernia was detected in this case. The boy was discharged on the 5th post-operative day, and the post-operative course was uneventful. Follow-up after 1 year revealed the presence of normal testes inside the scrotum (Figs. 1-6).

3. DISCUSSION

The development of the testis and their descent from the abdomen to the scrotum is complex and multistage process. The testes migration is under the inheritance of andrological hormones and various mechanical factor of gubernaculum of testis. It has been thought to involve overdevelopment and elongation of segment of gubernaculum, genitofemoral nerve anomaly or an obstruction in the entrance to the scrotum [1,3,4]

Ectopic testes can be found in different locations, including the superficial inguinal pouch, perineum, crossed testicular ectopic, femoral region, and the pubo-penile region [7]. The most common site, observed in 75% of cases, is the superficial inguinal pouch, followed by perineal ectopic testes as the second most common

anomaly. First described by John Hunter in 1786, perineal ectopic testis is a rare anomaly constituting less than 1% of all cases of undescended testis [2,8,9].

The development of gonads, starting adjacent to the rudimentary kidney, involves transabdominal descent beginning at the 5th week of gestation. By the 10th week, they are in close proximity to the internal inguinal ring, and by the 12th week, the gubernaculum begins to develop. Between the 20th and 28th weeks, the testes pass through the inguinal canal, with further descent into the scrotum occurring up to birth [1,2,3].

Perineal ectopic testis is exceptionally rare, and bilateral cases are even scarcer, with only six reported cases. Approximately 175 cases of perineal ectopic testes have been documented, and 80% of these cases are unilateral. An empty scrotum with a soft perineal mass on the ipsilateral side strongly suggests perineal testis. Palpation of the testis facilitates diagnosis, and while most cases present in childhood, adult presentations are exceedingly rare. Delay in diagnosis and treatment can lead to complications such as testicular atrophy, trauma, torsion, infertility, and cancer. A comprehensive clinical examination, coupled with ultrasonography, is ideal for diagnosing perineal ectopic testes [2,3,4].

Surgical treatment typically involves open orchidopexy through a standard inguinal skin crease incision. The gubernaculum, often fixed to the perineum, is easily released, allowing the testes to be placed in the ipsilateral hemiscrotum, facilitated by the sufficient length of the spermatic cord and vessels [9,10].

4. CONCLUSION

Perineal ectopic testis is a rare disease and the diagnosis can easily be made by physical examination of ectopic regions and an empty scrotum. Imaging technique such as ultrasonography and tomography may be required. The recommended and widely accepted treatment for perineal ectopic testis is open orchiopexy.

CONSENT AND ETHICAL APPROVAL

It is not applicable.

COMPETING INTERESTS

Authors have declared that no competing interests exist.

REFERENCES

1. Ulubay M. Perineal ectopic testis: A rare congenital anomaly. Urol Case Rep. 2019 Feb 21;24:100853. DOI: 10.1016/j.eucr.2019.100853. PMID: 31211064; PMCID: PMC6562294.
2. Ngowi BN, Bright F, Mbwambo JS, Mmbaga BT, Lekei E, Kimolo M, Mteta KA, Mbwambo OJ. Perineal ectopic testis in adult: Experience from tertiary hospital, northern Tanzania. Int J Surg Case Rep. 2022 Mar;92:106817. DOI:10.1016/j.ijscr.2022.106817. Epub 2022 Feb 7. PMID: 35183004; PMCID: PMC8857501.
3. Stephanie Jensen, Catherine J. Chen, Ectopic perineal testicle: Case report and review of literature, Urology Case Reports, Available:https://doi.org/10.1016/j.eucr.2022.102274.
4. Cobellis G, Novierllo C, Nino F, Romano M, Mariscoli F, Martino A, Parmeggiani P, Papparella A. Spermatogenesis and cryptorchidism. Frontiers in Endocrinology. 2014;5(63). DOI:10.3389/fendo.2014.00063 Jafarov, V., 2019.
5. Gadelkareem RA, Shahat AA, Reda A. et al. Ectopic testis: an experience of a tertiary-level urology center at Upper Egypt. Ann Pediatr Surg. 2020;16:27. Available:https://doi.org/10.1186/s43159-020-00038-8
6. Punwani VV, Wong JSY, Lai CYH, Chia JCY, Hutson JM. Testicular ectopia: Why does it happen and what do we do? J Pediatr Surg. 2017;52(11):1842–1847
7. Surya PA, Faadilah AH, Sriyono. Perineal ectopic testis in one and a half year old child as a rare congenital anomaly: A case report. Medicra (Journal of Medical Laboratory Science/Technology). 2023;6(1):6-9. Available:https://doi.org/10.21070/medicra.v6i1.1689
8. Safdar Hussain Awan, Naveed Ahmed, C. Aqeel Safdar, Iftikhar Ahmed, Hashim Zaidi. Perineal ectopic testis - A rare anomaly with empty scrotum, Pak Armed Forces Med J. 2020;70(6):1944-46
9. Nepal P, Kumar D, Ojili V. Abnormal descent of the testis and its complications: A multimodality imaging review. Radiological Society of South Africa. 2018;22(1):374. DOI:10.4102/sajr.v22i1.1374
10. Joda A. Five different cases of ectopic testes in children: a self-experience with literature review. World Journal of Pediatric Surgery. 2019;2(3):e000068. DOI: 10.1136/wjps-2019-000068

© 2024 Jatal et al.; This is an Open Access article distributed under the terms of the Creative Commons Attribution License (<http://creativecommons.org/licenses/by/4.0>), which permits unrestricted use, distribution, and reproduction in any medium, provided the original work is properly cited.

Peer-review history:
The peer review history for this paper can be accessed here:
<https://www.sdiarticle5.com/review-history/112465>