



Isolated Saphena Varix: A Rare Case of Groin Swelling

Aditya Jayaprakash^a, Nithila Sivakumar^{a*},
Lakshmi Murugesan^a and Lakshiya Ramamoorthy^a

^a Institute of General Surgery, Madras Medical College, Chennai, Tamil Nadu -600003, India.

Authors' contributions

This work was carried out in collaboration among all authors. Authors AJ, NS, LM and LR helped in study conception. Author AJ collected the data. Authors NS, LM and LR prepared the manuscript. Authors AJ, NS, LM and LR critically reviewed the manuscript. All authors read and approved the final manuscript.

Article Information

Open Peer Review History:

This journal follows the Advanced Open Peer Review policy. Identity of the Reviewers, Editor(s) and additional Reviewers, peer review comments, different versions of the manuscript, comments of the editors, etc are available here: <https://www.sdiarticle5.com/review-history/117542>

Case Report

Received: 14/03/2024

Accepted: 17/05/2024

Published: 22/05/2024

ABSTRACT

A saphena varix, characterized by the dilation of the great saphenous vein (GSV) near its insertion into the femoral vein, typically manifests along with varicose veins, and isolated occurrences are particularly rare. Clinically, this swelling exhibits a cough impulse, but the diagnosis is confirmed by ultrasonography. The challenge lies in distinguishing such varices from uncomplicated femoral hernias, necessitating the utilization of advanced diagnostic modalities. Here we present a case of isolated saphena varix in a 65-year-old female who was successfully treated with surgery. The objective of this case report is to prompt clinicians to consider this rare presentation as a possible diagnosis when evaluating a patient presenting with groin swelling.

Keywords: Saphena varix; varicose veins; groin swelling; saphenofemoral junction.

*Corresponding author: E-mail: nithila99@gmail.com;

Cite as: Jayaprakash, A., Sivakumar, N., Murugesan, L., & Ramamoorthy, L. (2024). Isolated Saphena Varix: A Rare Case of Groin Swelling. *Asian Journal of Case Reports in Surgery*, 7(1), 272–277. Retrieved from <https://journalajcrs.com/index.php/AJCRS/article/view/535>

1. INTRODUCTION

A saphena varix is a saccular outpouching of the great saphenous vein, usually close to the level of the saphenofemoral junction, and is commonly found in patients with varicose veins. Saphena varix tends to occur within 2 cm of the saphenofemoral junction¹. Isolated saphena varix is a rare vascular anomaly that is characterized by the dilation and incompetence of the saphenous vein system without significant involvement of tributaries or perforator veins. It poses diagnostic and management challenges, emphasizing the need for a focused understanding of its etiology, presentation, and treatment modalities. The diagnosis may be compounded by its similarity in presentation to femoral hernias. Imaging modalities are usually necessary in making a definite diagnosis, such as a duplex scan of the lower limbs [1]. Surgical management is the most definitive option, which is indicated in these cases [2,3].

This case report describes a 65-year-old female who presented with swelling in the antero-medial aspect of the left thigh, initially suspected to be a femoral hernia given its higher occurrence in older females. However, upon further evaluation with duplex ultrasound, a diagnosis of an isolated saphena varix was confirmed. She was successfully treated with high saphenous flush ligation of the GSV.

2. CASE REPORT

A 65-year-old female patient who came to the Department of Geriatric Surgery Outpatient Clinic at Rajiv Gandhi Government General Hospital presented with a 2-month history of swelling on the anterior aspect of the left thigh. The swelling has been insidious in onset but non-progressive in size and is found to decrease in size when lying down. The patient was unsure if the swelling increased in size upon coughing. Additionally, she gives a history of pain in the region during prolonged periods of walking, which is a necessity in her job as a food cart vendor. She is a known case of hypothyroidism on regular medication and is in good control. She had no significant medical or past surgical history.

On examination, a 3x3 cm diffuse swelling was seen on the antero-medial aspect of the left thigh with ill-defined edges, a smooth surface, and soft

consistency. The skin over the swelling was smooth and pinchable. Moreover, the surrounding area also appeared normal without any discoloration. The swelling was found to decrease in size when lying down. The contralateral thigh was normal. No dilated or tortuous veins were visible in the bilateral lower limbs, and an abdominal examination showed no abnormality. A palpable but not visible cough impulse was present over the swelling. Based on the above history and examination, a clinical diagnosis of left uncomplicated femoral hernia was made.

Initial high-frequency ultrasound of the groin swelling suggested femoral hernia with a 5mm defect and peritoneal fluid as content. However, a subsequent computed tomography (CT) abdomen revealed multiple dilated tortuous veins in the region of the saphenofemoral junction, leading to a diagnosis of left-sided saphena varix. No significant abdominal pathology was noted. To reconcile the disparate diagnoses, a duplex scan was performed, confirming left-sided isolated saphena varix with saphenofemoral incompetence demonstrated by reflux at the level of the SFJ (Fig. 1). Notably, tortuous venous dilations were observed only around the saphenofemoral junction, with no evidence of varicose veins elsewhere in the limb or in the contralateral limb. Furthermore, an endoscopy was also performed to rule out intraluminal lesions of the gastrointestinal tract. A final diagnosis of isolated saphena varix was made, and the patient was taken up for high saphenous flush ligation of the GSV.

2.1 Management

Procedure: Under regional anaesthesia and aseptic precautions, the patient was placed in the supine position with the knee flexed and the hip abducted and externally rotated. An incision was made 2cm below and lateral to the pubic tubercle. Layers were deepened, and the SFJ (saphenofemoral junction) was identified. Five corresponding tributaries were identified and ligated individually (Fig. 2). Through meticulous dissection, the GSV (great saphenous vein), accessory saphenous vein, and the saphenous varix were dissected and excised in toto. Flush ligation of the SFJ was performed. Venous stripping was not performed, as no dilated veins were found. Haemostasis was achieved, and the wound was closed in layers.

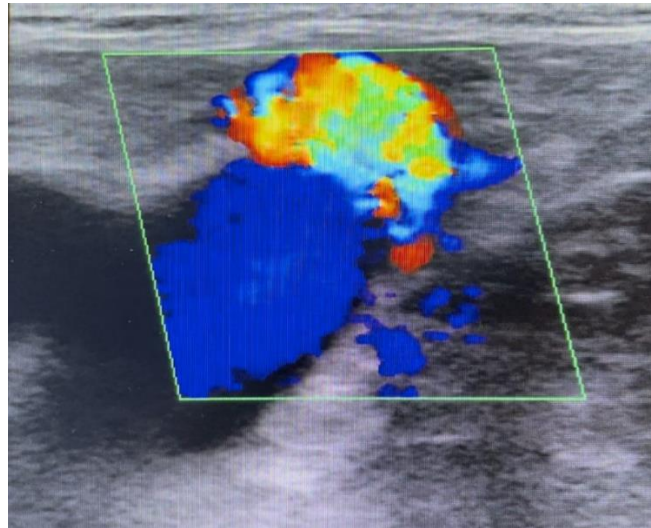


Fig. 1. Pre-operative Duplex ultrasonography indicating the presence of reflux blood flow at the site of the saphenous varix when the patient was asked to cough

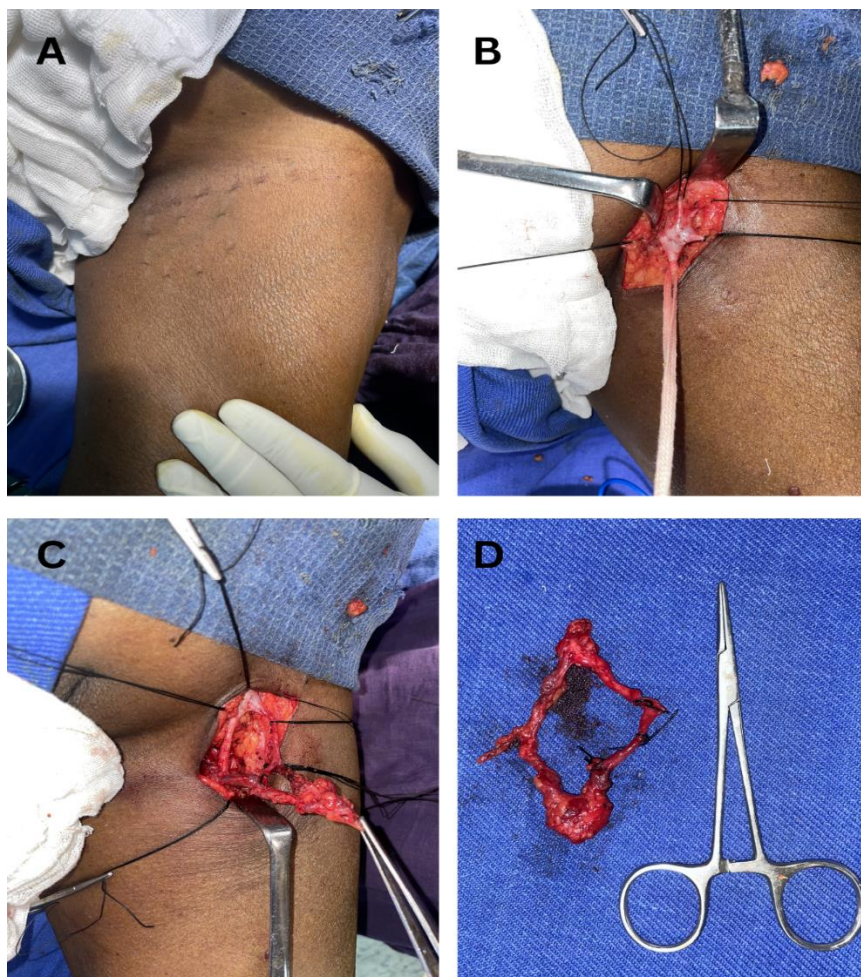


Fig. 2. (A)Pre-operative image with markings of the surgical site; (B)Intra-operative image of saphenofemoral junction (SFJ) and its tributaries in the left lower extremity; (C)Intra-operative image showing dissection of the dilated SFJ; (D)Post-operative surgical specimen of the saphena varix, with size comparison to a straight mosquito

Follow-up and outcome: The patient had an insignificant postoperative course and was discharged on postoperative day 7. A postoperative duplex scan was found to be normal. The patient was advised to follow up in the clinic for a routine check-up. Overall, the procedure was successful in addressing the isolated saphena varix without any complications.

3. DISCUSSION

Saphena varix is a rare vascular anomaly marked by localized dilation of the GSV, which clinically presents as a painless, palpable, bluish subcutaneous mass along the course of the GSV in the antero-medial aspect of the thigh. The lower limb functions with dual venous drainage systems: deep and superficial. These systems intersect at various levels through perforators, which include major intersections such as the saphenofemoral and saphenopopliteal junctions. When these communicating areas malfunction, blood refluxes from the deep to the superficial system, which manifests as varicose veins [1].

The precise pathophysiology remains a topic of debate, but it generally involves genetic predisposition, valve incompetence, weakened vascular walls, and elevated intravenous pressure. Typically, valvular malfunction is attributed to a loss of vein wall elasticity, leading to the inability of valve leaflets to approximate properly. Instead of the normal flow pattern from distal to proximal and superficial to deep, defective valves allow blood to reverse its course. This results in increased pressure within the affected venous system, potentially causing enlargement and tortuosity of larger veins. Additionally, shear stress on venous endothelial cells due to turbulent or reversed blood flow, along with inflammation, are significant contributing factors to venous disease [3]. A similar mechanism of reflux leads to a dilation of the saphenofemoral junction (SFJ), which presents as a saphena varix. Incompetence and consequent reflux may be primary or secondary to an obstructing lesion at a proximal level. Common risk factors include a family history of venous disease, female gender, old age, prolonged periods of standing, a history of deep vein thrombosis leading to valve damage and subsequent revascularization, and arteriovenous shunting. Conditions causing elevated abdominal pressure for a prolonged period, such as obesity, pregnancy, chronic constipation, or tumors, also

pose a risk for the development of this condition [4].

Saphena varix appears as a soft, solitary, compressible swelling in the subcutaneous plane. If sufficiently enlarged, it may exhibit a visible cough impulse, while a palpable cough impulse can be elicited using the Morrisey's cough impulse test. This impulse may range from a mild sensation to a pronounced expansion and can even be induced by a Valsalva manoeuvre. It can have complications such as bleeding, thrombosis, and thrombophlebitis [5]. A thrombosis of an isolated saphena varix has been known to mimic an incarcerated femoral hernia [6]. Femoral hernia exhibit features similar to saphena-varix, such as reducibility and positive cough impulse test, posing challenges even for skilled surgeons. Nevertheless, the saphena-varix tends to enlarge when standing, resulting in a bluish discoloration beneath the skin. When coupled with complete reducibility, these signs suggest a higher likelihood of this diagnosis [7]. Ultrasound or ascending venography can help confirm the diagnosis [8]. Unlike most femoral hernia, the saphena varix is soft and reduces completely upon assuming a recumbent position. Other potential differential diagnoses for saphena varix encompass inguinal lymphadenopathy, cysts, lipoma, abscesses, undescended testis, retractile testes, and vascular conditions such as femoral artery aneurysms [9]. Saphena varix can be discerned from femoral artery aneurysm by its lack of pulsation and reduction with recumbency [8].

Our case is notable because isolated saphena varix is an exceedingly uncommon condition with only a handful of documented cases in literature. The absence of varicosities elsewhere makes this case unique and interesting [8]. Duplex ultrasound emerges as the preferred diagnostic tool due to its capability to distinguish between various potential diagnoses [1]. It effectively reveals reflux at the saphenofemoral junction (SFJ) through the visualization of flow reversal on colour Doppler imaging. When duplex ultrasound yields inconclusive results, CT venography proves beneficial. Moreover, MR venography serves as a valuable alternative for patients with contraindications to iodinated contrast agents utilized in CT scans. In our specific scenario, a CT abdomen was performed to exclude secondary causes of SFJ incompetence. Notably, relying solely on plain USG may lead to misleading interpretations, as evidenced in our case [10].

Management options encompass conservative and surgical approaches. Conservative management involves the utilization of leg hosiery, which only offers limited value and benefit to the patient. Surgical intervention stands as the cornerstone of treatment, typically involving high-saphenous flush ligation of the saphenofemoral junction. In cases where associated varicose veins are present, foam sclerotherapy and venous stripping may be considered an adjunct procedure [3,1,11,12]. Endovascular laser ablation is also gaining popularity, but there is not enough evidence to support its effectiveness in treating saphena varix.

4. CONCLUSION

While saphena varices are frequently seen in association with varicose veins, isolated saphena varix of the groin is an extremely rare clinical entity and can masquerade as femoral hernias on clinical examination. Heightened clinical suspicion is essential for early recognition of this condition. While physical examination plays a significant role, diagnostic imaging such as duplex ultrasound is essential for accurate diagnosis. Furthermore, a thorough understanding of the anatomy and pathophysiology of saphena varix is crucial for clinicians to differentiate it from other similar conditions. Therefore, a multidisciplinary approach is paramount for the optimal management of patients with suspected saphena varix.

CONSENT

Informed written consent has been obtained from the patient.

ETHICAL APPROVAL

As per international standards or university standards written ethical approval has been collected and preserved by the author(s).

ACKNOWLEDGEMENTS

We would like to express our heartfelt appreciation to the late Dr. Maruthupandian, whose surgical expertise and encouragement were instrumental in the treatment of this case. His invaluable insights and support have greatly contributed to the management of this patient, and his memory will always remain cherished.

COMPETING INTERESTS

Authors have declared that no competing interests exist.

REFERENCES

1. Ballard JL, Bergan J: Chronic Venous Insufficiency: Diagnosis and Treatment. New York, USA: Springer Science & Business Media. 2012;135.
2. Raetz J, Wilson ME, Collins K: Varicose veins: Diagnosis and treatment. PubMed. 2019;99(11): 682-688. Available:<https://pubmed.ncbi.nlm.nih.gov/31150188>
3. Bhuiyan M, Fahim E, Sadik B, et al. Management of Saphena Varix: A rare case in Surgical Practice. Cardiovasc J. 1970;1:229-30.
4. Beebe-Dimmer JL, Pfeifer JR, Engle JS, et al. The epidemiology of chronic venous insufficiency and varicose veins. Ann Epidemiol. 2005;175-184. DOI: 10.1016/j.annepidem.2004.05.015
5. Owen TD: Thrombosed sapheno-varix: An important and unusual differential diagnosis of strangulated femoral hernia. Br J Clin Pract. 1990;754. DOI:10.1111/j.1742-1241.1990.tb10201.x
6. Ravikanth R. Thrombosed saphena varix. Journal of Medical Ultrasound. 2019;27*(1):54-55. Available:https://doi.org/10.4103/JMU.JMU_35_18
7. Lea MS, Deshmukh NL: Saphena Varix: A Case Report. Mil Med. 1990;368.
8. Wales LR, Azose AA: Saphenous varix: ultrasonic diagnosis. J Ultrasound Med. 1985;143-145. DOI: 10.7863/jum.1985.4.3.143
9. Harrison L, Keesling C, Martin N, et al.: Abdominal wall hernias: Review of herniography and correlation with cross-sectional imaging. Radiographics. 1995: 315-32. DOI: 10.1148/radiographics.15.2.7761638
10. Ohuegbe CI, Ehiwe E, Vivek M, et al.: Saphenous varix - A pitfall in ultrasound imaging of femoral hernia: A case report. DOI:10.1016/j.ejradi.2010.09.003
11. Karacalilar M, Kutas HB. Approach to tortuous vena saphena magna with insufficiency: Foam sclerotherapy. Vascular. 2022;31(5):1003–1010. Available:<https://doi.org/10.1177/17085381221098907>

12. Fabián V, Honěk J, Horváth V, Horváth M, Šlais M, Vítovec M, Stehno O, Šedivý P, Šebesta P, Weiss J, Honěk T. Endovenous laser ablation of saphenous veins - favorable clinical results confirm theoretical advantages of the 1940nm diode laser. **Rozhledy v Chirurgii*. 2022;101*(8): 395-400. Available:<https://doi.org/10.33699/PIS.2022.101.8.395-400>

© Copyright (2024): Author(s). The licensee is the journal publisher. This is an Open Access article distributed under the terms of the Creative Commons Attribution License (<http://creativecommons.org/licenses/by/4.0>), which permits unrestricted use, distribution, and reproduction in any medium, provided the original work is properly cited.

Peer-review history:

The peer review history for this paper can be accessed here:

<https://www.sdiarticle5.com/review-history/117542>