



Pheochromocytoma as a Cause of Decompensated Dilated Cardiomyopathy: A Rare Case Report

A. Boucetta ^{a,b*}, I. EL Fakihi ^{a,b}, A. Ennaciri ^{a,b},
M. Haboub ^{a,b} and R. Habbal ^{a,b}

^a Cardiology Department, Ibn Rochd University Hospital, Morocco.

^b Faculty of Medicine and Pharmacy Casablanca, FMPC, Morocco.

Authors' contributions

This work was carried out in collaboration among all authors. All authors read and approved the final manuscript.

Article Information

Open Peer Review History:

This journal follows the Advanced Open Peer Review policy. Identity of the Reviewers, Editor(s) and additional Reviewers, peer review comments, different versions of the manuscript, comments of the editors, etc are available here: <https://www.sdiarticle5.com/review-history/123099>

Case Report

Received: 07/07/2024

Accepted: 09/09/2024

Published: 12/09/2024

ABSTRACT

Introduction: Pheochromocytoma is a neuroendocrine tumour derived from chromaffin cells that produce catecholamines. The classical clinical triad is characterised by headaches, palpitations and sweating. Our patient presented initially with severe dilated cardiomyopathy and acute decompensated heart failure, which necessitated optimisation prior to surgical removal of the adrenal glands.

Case Presentation: A 57-year-old female patient was admitted to the hospital with symptoms of dyspnoea, oedema of the lower extremities, and atrial fibrillation.

Echocardiography demonstrated a dilated left ventricle with global hypokinesia and a left ventricular ejection fraction of 10%. The patient was treated for acute systolic heart failure decompensation with diuresis and afterload reduction. Unexpectedly, an abdominal CT scan revealed bilateral

*Corresponding author: Email: boucetta28abdellah@gmail.com;

adrenal mass, and subsequent serum/urinary metanephrine tests indicated the presence of pheochromocytoma.

Conclusion: In conclusion, the presence of acute congestive heart failure resulting from the development of dilated cardiomyopathy, the aetiology of which remains uncertain, should prompt consideration of the potential existence of a pheochromocytoma. It is important to note that pheochromocytomas do not always manifest in accordance with the established triad of symptoms, which includes headache, palpitations and diaphoresis. Furthermore, catecholamines have been demonstrated to induce cardiomyopathy and, subsequently, to progress to congestive heart failure.

Keywords: Acute congestive heart failure; pheochromocytoma; dilated cardiomyopathy.

1. INTRODUCTION

Pheochromocytoma is a rare tumor composed of chromaffin cells which secrete catecholamines. It is found in the adrenal medulla in 85% of cases.

The diagnosis is typically established as part of a comprehensive evaluation for hypertension or in the presence of the Menard's triad of symptoms [1].

In rare instances, pheochromocytoma may be identified through the investigation of dilated cardiomyopathy.

We present the case of a 57-year-old woman in whom a pheochromocytoma was identified subsequent to left heart decompensation with atrial tachycardia and dilated cardiomyopathy.

2. CASE PRESENTATION

This case study presents the case of a 57-year-old female patient with no specific pathological

history and no cardiovascular risk factors other than age and menopause.

The patient was admitted for decompensation of the left heart, which was attributed to dilated cardiomyopathy with atrial fibrillation.

Upon examination, the patient was found to be conscious, dyspneic at rest, and to exhibit epigastric tenderness.

The patient's blood pressure was 16/10 mmHg, heart rate was 120 bpm/min, and the free oxygen saturation was 96%.

The patient exhibited crackles between the bases and mid-chest, as well as bilateral oedema of the lower limbs extending to the ankles.

An electrocardiogram was conducted, which revealed atrial fibrillation tachycardia at 139 beats per minute, with no additional concomitant indications (Fig. 1).

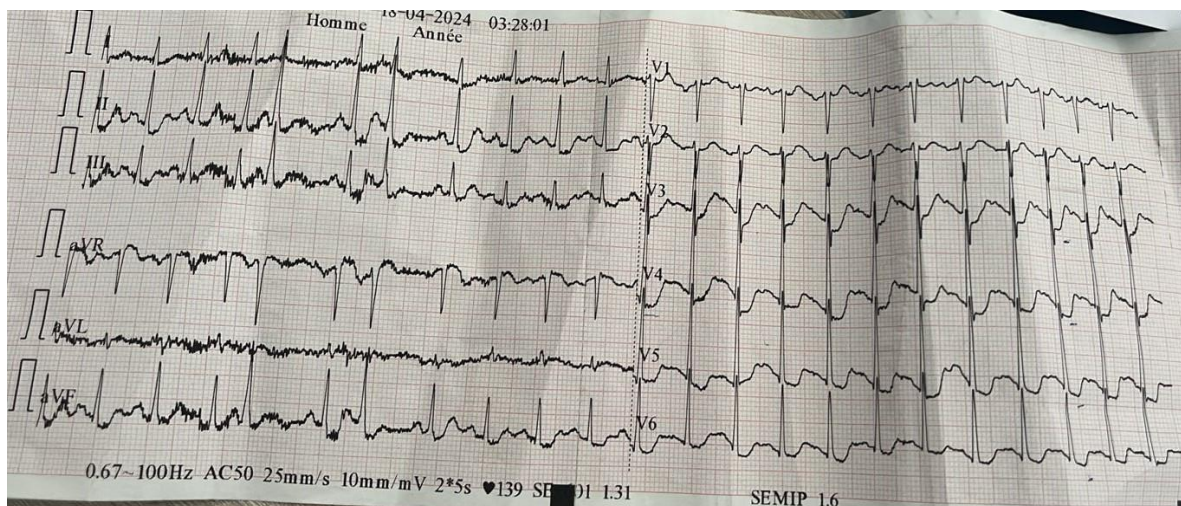


Fig. 1. The electrocardiogram (ECG) demonstrates atrial tachycardia-fibrillation at a heart rate of 139 beats per minute (bpm)

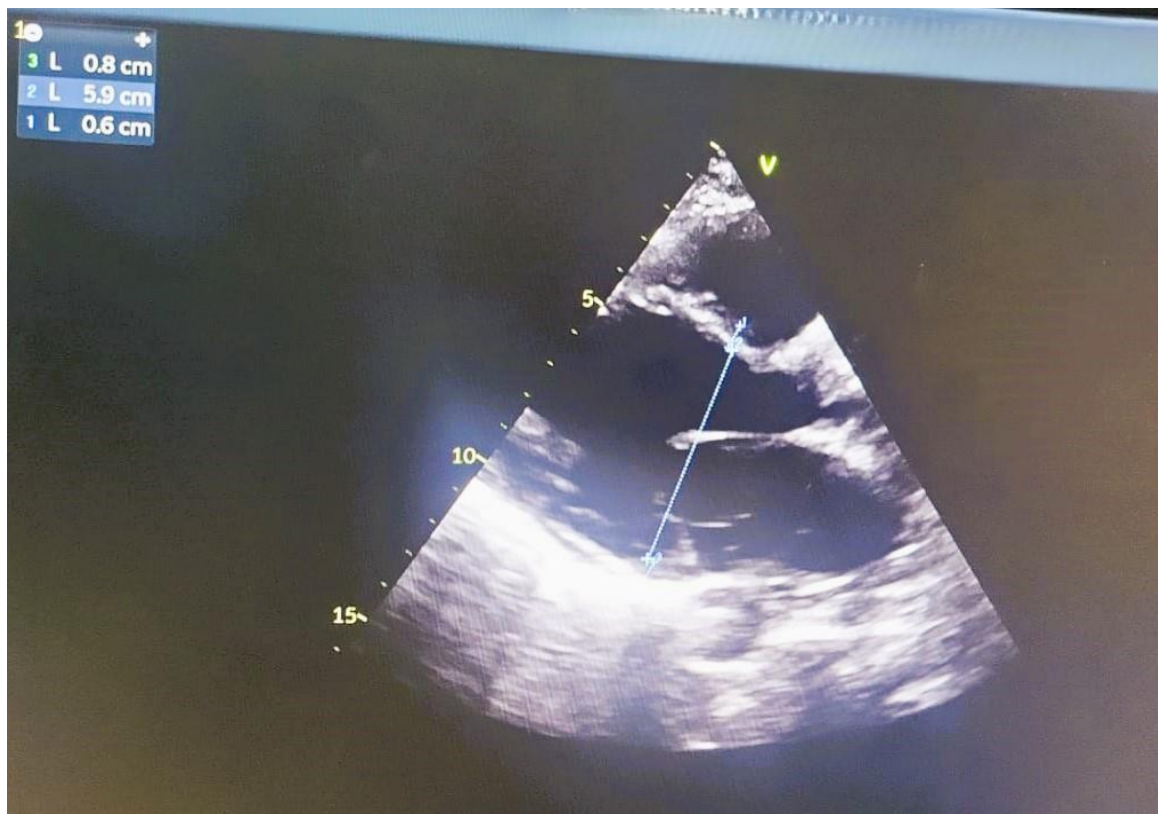


Fig. 2. The ultrasound image demonstrates a dilated left ventricle

An echocardiogram was conducted, which revealed a dilated left ventricle with global hypokinesia, LVEF 10%, with an intermediate probability of PAH (PAPS 60 mmHg), and no additional associated signs (Fig. 2).

The patient was initiated on Lasilix 240 mg SAP, with potassium supplementation, and a course of treatment for heart failure has been prescribed. From a biological perspective, the patient exhibited hyperleukocytosis, reaching 12,000/mm³, and elevated CRP levels, at 160 mg/L. Additionally, the patient displayed normocytic normochromic anemia, with a hemoglobin concentration of 10 g/dL.

The natremia and hemogram were within the normal range. The lipid profile was within the normal range.

The patient reported paroxysmal palpitations, sweating, and headaches.

An abdominal CT scan revealed the presence of bilateral adrenal adenomas, which may be indicative of a pheochromocytoma.

The urinary catecholamines revealed markedly elevated levels of adrenaline and noradrenaline, at 8.68 micromole/24h and 3.51 μ mol/24h, respectively. The patient was initiated on oral antibiotics. It was recommended that this work-up be completed by coronary angiography, with the aim of investigating the etiology of her dilated cardiomyopathy, before she underwent surgery.

3. DISCUSSION

A pheochromocytoma is a rare tumour of chromaffin cells, which are known to produce excess catecholamines. The prevalence of this tumor among patients with sustained hypertension is 0.05–0.1% [2].

It has been established that the majority of cases of heart failure in patients diagnosed with pheochromocytomas are indicative of a stress-induced cardiomyopathy, which is more commonly known as Takotsubo cardiomyopathy or broken heart syndrome [3].

The diagnosis of an unrecognised pheochromocytoma can prove challenging in this context.

Delby and colleagues reported the late discovery of a pheochromocytoma in two patients who had undergone heart transplantation for ischaemic dilated cardiomyopathy [4].

The diagnosis is typically made as part of an investigation into the cause of arterial hypertension or in the presence of the Ménard triad of symptoms.

Although the prognosis is often favorable following the removal of the tumor, it can also give rise to cardiovascular complications, some of which can be dramatic.

The pathophysiological mechanisms of adrenergic cardiomyopathy associated with pheochromocytoma remain unclear, giving rise to several hypotheses [5].

It remains uncertain as to the precise etiology of cardiomyopathy in patients presenting with pheochromocytoma. There is evidence to suggest that the administration of exogenous epinephrine and norepinephrine has the potential to elicit a cardiotoxic effect, which is dependent on dosage [6].

The curative treatment is based on surgical removal of the tumor.

In several cases, the reversibility of cardiomyopathy after removal of the pheochromocytoma has been reported; however, this is only seen in cases of minimal myocardial damage and absence of generalised myocardial fibrosis [7].

Although surgical resection of the tumor is the optimal treatment, it is essential that patients be stabilised with sufficient α and β blockade prior to undergoing surgery.

As previously reported, cardiomyopathy associated with pheochromocytoma can be reversed by surgical removal of the tumor [8]. It has been demonstrated that the heart failure induced by pheochromocytoma can be reversed by medical treatment alone, with the ejection fraction increasing from 10% to 55% over the course of 10 days of treatment with α -blockers and β -blockers [9,10].

4. CONCLUSION

This case study illustrates the importance of considering dilated cardiomyopathy as a

potential indicator of pheochromocytoma. Early diagnosis and prompt treatment are crucial, given the significant risk of morbidity and mortality associated with these conditions.

DISCLAIMER

Author(s) hereby declare that NO generative AI technologies such as Large Language Models (ChatGPT, COPILOT, etc) and text-to-image generators have been used during writing or editing of this manuscript.

AVAILABILITY OF DATA AND MATERIAL

All data generated or analysed during this study are included in this published article.

CONSENT

Written informed consent was obtained from the patients for publication of this case report and any accompanying images.

ETHICAL APPROVAL

As per international standards or university standards written ethical approval has been collected and preserved by the author(s).

COMPETING INTERESTS

Authors have declared that no competing interests exist.

REFERENCES

1. Plouin PF, Degoulet P, Tugaye A, Ducrocq MB, Menard J. Dépistage du phéochromocytome chez quels hypertendus? Étude sémiologique chez 2585 hypertendus dont 11 ayant un phéochromocytome. *Nouv Presse Med.* 1981 Mar 7;10(11):869–72.
2. Manger WM. An overview of pheochromocytoma: history, current concepts, vagaries, and diagnostic challenges. *Ann N Y Acad Sci.* 2006; 1073:1–20.
3. Park JH, Kim KS, Sul JY, et al. Prevalence and patterns of left ventricular dysfunction in patients with pheochromocytoma. *J Cardiovasc Ultrasound.* 2011;19: 76–82.
4. Miles Dalby C, Burke M, Radley-Smith R, Banner NR. Pheochromocytoma

- Presenting After Cardiac Transplantation for Dilated Cardiomyopathy. J Heart Lung Transplant. 2001 Jul;20(7):773–5.
5. Tréguer F, Jeanneteau J, Rouleau F, Furber A. La myocardite aiguë, un mode de révélation peu fréquent du Phéochromocytome. Rev Med Interne. 2008Dec;29(12):1050–3.
 6. Mobine HR, Baker AB, Wang L, et al. Pheochromocytoma-induced cardiomyopathy is modulated by the synergistic effects of cell-secreted factors. Circ Heart Fail. 2009;2:121–8.
 7. Schürmeyer TH, Engeroff B, Dralle H, von zur Mühlen A. Cardiologic effects of catecholaminesecreting tumours. Eur J Clin Invest. 1997;27(3):189-195.
 8. Salinas CL, Gomez Beltran OD, Sanchez-Hidalgo JM, et al. Emergency adrenalectomy due to acute heart failure secondary to complicated pheochromocytoma: A case report. World J Surg Oncol. 2011;9:49.
 9. Mulla CM, Marik PE. Pheochromocytoma presenting as acute decompensated heart failure reversed with medical therapy. BMJ Case Rep. 2012 Jul 19;2012:bcr2012006319. DOI: 10.1136/bcr-2012-006319.
 10. Jiang, Xuandong, Zhang Weimin, Fang Qiang. Pheochromocytoma-related cardiomyopathy presenting as acute myocardial infarction: A case report. Medicine. 2021;100(11):e24984..

Disclaimer/Publisher's Note: The statements, opinions and data contained in all publications are solely those of the individual author(s) and contributor(s) and not of the publisher and/or the editor(s). This publisher and/or the editor(s) disclaim responsibility for any injury to people or property resulting from any ideas, methods, instructions or products referred to in the content.

© Copyright (2024): Author(s). The licensee is the journal publisher. This is an Open Access article distributed under the terms of the Creative Commons Attribution License (<http://creativecommons.org/licenses/by/4.0>), which permits unrestricted use, distribution, and reproduction in any medium, provided the original work is properly cited.

Peer-review history:

The peer review history for this paper can be accessed here:

<https://www.sdiarticle5.com/review-history/123099>