



Evaluation of Coronary Stent Expansion during Percutaneous Coronary Interventions Using Stent Boost Visualization in Comparison with Intravascular Ultrasound

Omran Mohamed Omran ^{a*}, Mohammed Hamed Sherif ^a, Ekram Sadek Saied ^a,
Medhat Mohamed El-Ashmawy ^a, Amr Dawood El-guindy ^a
and Samia Mahmoud Sharaf El-den ^a

^a *Department of Cardiology, Faculty of Medicine, Tanta University, Tanta, Egypt.*

Authors' contributions

This work was carried out in collaboration among all authors. All authors read and approved the final manuscript.

Article Information

DOI: 10.9734/JAMMR/2022/v34i1931454

Open Peer Review History:

This journal follows the Advanced Open Peer Review policy. Identity of the Reviewers, Editor(s) and additional Reviewers, peer review comments, different versions of the manuscript, comments of the editors, etc are available here: <https://www.sdiarticle5.com/review-history/88425>

Original Research Article

Received 07 April 2022

Accepted 14 June 2022

Published 20 June 2022

ABSTRACT

Background: Even in the era of drug-eluting stents, underexpansion of coronary stents remains a prominent cause of in-stent thrombosis and restenosis in patients having percutaneous coronary interventions (PCI). The aim of this work was to evaluate the value of using stent boost (SB) to detect stent under expansion (UE) by comparing this method to the gold-standard method of measurement by intravascular ultrasound (IVUS).

Methods: This prospective observational cross-sectional research enrolled 21 cases with chronic coronary artery disease who had elective PCI with IVUS and SB. Every patient was exposed to full history taking, full clinical examination and echocardiography. Pre-stenting IVUS was done to assess lesion characteristics, vessel measurements specifically distal reference lumen diameter and area (distal RLD, RLA) and to assess the size of the needed stent. SB image was obtained helped by the deflated balloon of the immediately deployed stent. IVUS was introduced post-stenting to obviate any hidden complication as well as to assess stent measurements of minimal stent diameter and area (MSD, MSA), hence, identify the group of patients with stent UE for which subsequent high pressure balloon dilatation was done. Post-procedure off-line processing of SB and QCA images to evaluate the presence of UE by both modalities.

*Corresponding author;

Results: SB showed good agreement to IVUS regarding MSD which became optimal agreement when done for Xience Xpedition stent (as the commonly used stent in our study). SB was able to detect optimal expansion compared to IVUS with 100% sensitivity and 33.33% specificity ($p=0.005$, $AUC=0.808$) at cut-off value criteria of MSD/distal RLD of 70%. The specificity increased to 66.67% when the cut-off value criteria of MSD/distal RLD was 76%. There was less agreement between QCA and IVUS.

Conclusions: Stent boost showed good agreement to IVUS regarding MSD which became optimal agreement when done for Xience Xpedition stent (as the commonly used stent in our study). SB was able to detect optimal expansion compared to IVUS with 100% sensitivity and Expedition 66.67% specificity ($p=0.005$, $AUC=0.808$) at MSD/distal RLD of 76% as a cut-off value criteria.

Keywords: *Coronary stent under expansion; percutaneous coronary interventions; stent boost visualization; intravascular ultrasound; quantitative angiography.*

1. INTRODUCTION

Coronary stent under expansion (UE) contributes significantly to the incidence of in-stent thrombosis and restenosis in patients having percutaneous coronary interventions (PCI), especially in the era of drug-eluting stents [1].

Quantitative coronary angiography (QCA) showed that existence of stent under expansion shares in stent thrombosis and restenosis [2].

The application of coronary intravascular ultrasound (IVUS) allows for a more exact evaluation of stent expansion than QCA and detects stent mal-apposition [1,3]. Multiple IVUS investigations have demonstrated that inadequate stent expansion and mal-apposition continue to be key indicators of stent thrombosis. This method is not used routinely in daily practice, being costly, time-consuming, and necessitates a learning curve (requiring skilled operators and laboratory team) [4].

Stent Boost subtract (SBS) is a recently discovered imaging technology that improves the stent's fluoroscopic visibility. By using motion-corrected acquisition frames, a clearer image of the stent and its relationship to the vessel wall may be acquired [5,6]. The aim of this work was to evaluate the value of using SB to detect stent under expansion by examining the association between stent diameters and gold standard IVUS readings.

2. PATIENTS AND METHODS

This prospective cross-sectional observational research was conducted on 21 patients aged from 48 to 65 years old and had chronic coronary artery disease with anatomical or functional

evidence of ischemia and underwent elective PCI with the use of IVUS and stent boost.

Exclusion criteria were patient refusal, marked renal impairment (e-GFR less than 30 ml/min), intolerance to antiplatelet therapy, presence of any significant co-morbid condition that severely limit patient's life span, known allergy to iodine contrast media, severe left ventricular dysfunction < 30% and conditions that preclude the use of IVUS.

Every patient was underwent: Full history taking [as regard risk factors (HTN, DM, DLP, smoking), ischemic symptoms, prior MI, prior coronary intervention (CABG & PCI) and drug history], full clinical examination (ECG and routine laboratory tests) and echocardiography.

- Digital Imaging and Communications in Medicine (DICOM)-compliant digital equipment was utilised to acquire the diagnostic angiograms; Philips Allura-Xper FD20, with a frame rate of 15 per second (fps).
- IVUS was done prior to PCI using Volcano s5i IVUS system and Eagle Eye Platinum ST catheter to assess the distal RLA, distal RLD, MLA and plaque type and burden hence allowed the decision regarding optimal diameters of the needed stent.
- Diameter of stent was chosen in accordance with the ratio of the distal reference lumen diameter (0.8 to the medium diameter or 1:1 to the lumen diameter). The landing areas for the stent proximally and distally were selected according to IVUS measurement as the locations where the plaque burden was <40%. Pre-dilation

was left to the discretion of the physician. according to IVUS results and type of plaque.

- SB imaging was done immediately after stent deployment, using the deflated balloon of the deployed stent in the most appropriate projection for the imaged coronary artery segment and that showed mostly obvious stent deformation and indentation.
- SB was generated by capturing 20 cine frames over 3 seconds, with the radiopaque dots of the delivery balloon serving as an anchor to position the stent across all frames. Although IVUS allowed circumferential stent evaluation, SB augmentation allowed two-dimensional assessment of diameters except if taken in two perpendicular planes with area calculation.
- IVUS was done again after PCI to measure minimum stent diameter and area, maximum stent diameter and diameters at proximal and distal margins of the stents well as to detect any complications.

Inadequate stent expansion was determined according to the following criteria MSA $\geq 90\%$ of distal reference lumen area [7-9]. Patients with suggested stent UE by IVUS criteria underwent post-dilatation using high pressure.

Post procedure offline assessment of QCA and SB images was done. Max SD, MSD, mean SD, stent SI and SD at proximal and distal stent edges were measured and then criteria of after the end of the procedure and data are filed for comparison with the gold standard IVUS.

Following the procedure, Independent of and blind to the QCA and IVUS data, offline manual digital reconstruction of the improved stent edges was acquired to produce the following stent diameter measurements: -

- Maximum, Minimum Stent Diameters. Mean Stent Diameter: automatically calculated. Stent symmetry index: (Max SD-MSD) /Max SD.
- Diameters at the proximal and distal edges of the stent.

After obtaining SB measures, they were filed for comparison and then were divided into two groups according to being well or under expanded where the well expanded stents had MSD $\geq 70\%$ of the distal RLD [10,11].

2.1 Quantitative Coronary Angiography

Digital flat-panel cardiac imaging was used to acquire all angiographic pictures Philips Allura-Xper FD20, with a frame rate of 15 per second (fps) system. It was used for offline assessment and analysis by validated and automated edge-detection software (Philips Medical Systems) in all cases in the angiographic projection with the clearest visibility of stent edges using the contrast-filled catheter was for calibration [12]. Measurements were done at the edges of the stent and included the following [12]; Maximum, Minimum Stent Diameters, Mean Stent Diameter (the mean between minimum and maximum), Stent symmetry index: (Max SD-MSD) divided by Max SD, Diameters at the proximal and distal edges of the stent. After that data were prepared for statistical analysis.

Patients were classified as being well expanded or under expanded using the predefined optimal expansion criteria: MSA $\geq 90\%$ of distal RLA for IVUS and MSD $\geq 70\%$ of distal RLD for SB.

2.2 Statistical Analysis

As a part of the SPSS version 23.0 for Windows statistical software for social sciences (SPSS), we analysed the acquired data. The Mean standard deviation (SD), frequency, and percentage of the data are shown. The chi-square (2) and Fisher's exact tests were used to compare categorical variables (if required). Student t tests (two-tailed) were used for parametric data to compare continuous variables. Mann-Whitney Nonparametric data was compared using the U test. diagnostic sensitivity, specificity and positive predictive value (PPV) and negative predictive value are evaluated (NPV). Bland-Altman analysis was used to determine the degree of agreement between quantitative variables. If the P value was less than 0.05, the study's findings were considered significant.

3. RESULTS

Table 1 shows demographic data, Echo findings and angiographic characteristics, of the studied patients.

Table 1. Demographic data, Echo findings and angiographic characteristics of the studied patients (n = 25)

		Patients (n = 21)
Age (years)		57.19 ± 5.501
Sex	Male	21 (100%)
	Female	0 (0%)
Medical history	HTN	17(81%)
	DM	14 (66.7%)
	Dyslipidemia	16 (76.2%)
Smoking habits	Non-smoker	6 (28.6%)
	Smoker	11 (52.4%)
	Ex-smoker	4 (19%)
Prior PCI		12 (57.1%)
Prior CABG		0 (0%)
Echo findings	EF %	57.29 ± 5.169
	Resting wall motion abnormalities.	10 (47.6%)
The diseased vessel	LAD	11(52.4%)
	LM	5 (23.8%)
	LCX	2 (9.5%)
	RCA	2 (9.5%)
	Ramus	1 (4.8%)

Data are presented as mean ± SD or frequency (%). HTN: Hypertension, DM: Diabetes Mellitus, PCI: Percutaneous coronary intervention, CABG: coronary artery bypass graft, EF: Ejection fraction, LAD: left anterior descending artery; LM: Left Main, LCX: left circumflex artery, RCA: left coronary artery

Table 2. Distribution of patients according to stent type and diameter

Type	Xience	11(52.4%%)
	Ultimaster	3 (14.3%)
	firehawk	3 (14.3%)
	ONYX	2(9.5%)
	Biofreedom	1(4.8%)
	Promus	1(4.8%)
Diameter		3.5 ± 0.518

Data are presented as mean ± SD or frequency (%).

Table 2 shows distribution of patients according to stent type and diameter.

Comparison of measurements by IVUS, QCA and SB showed that there were no statistically significant differences between all measurement types Table 3.

The Bland–Altman analysis:

demonstrated a strong agreement between stent boost and IVUS for assessing the minimal stent diameter, although the agreement between QCA and IVUS was less. Fig. 1 and Fig. 2

Table 3. Comparison of measurements by IVUS, QCA and SB

	QCA	SB	IVUS	P1	P2	P3
Maximal SD	3.51 ± 0.625	3.25 ± 0.524	3.61 ± 0.644	0.931	0.379	0.196
Minimal SD	2.38 ± 0.583	2.5 ± 0.504	2.65 ± 0.528	0.468	0.343	0.304
Mean SD	2.88 ± 0.594	3.11 ± 0.523		0.100		
Stent symmetry index	0.33 ± 0.091	0.28 ± 0.096	0.26 ± 0.143	0.424	0.495	0.720
Stent diameter at proximal edge	3.09 ± 0.878	3.08 ± 0.730	3.84 ± 0.804	0.642	0.076	0.064
Stent diameter at distal edge	2.64 ± 0.611	2.68 ± 0.584	2.82 ± 0.510	0.472	0.400	0.271

Data are presented as mean ± SD. P1: comparison between QCA and SB, P2: Comparison between QCA and IVUS, p3: comparison between SB and IVUS

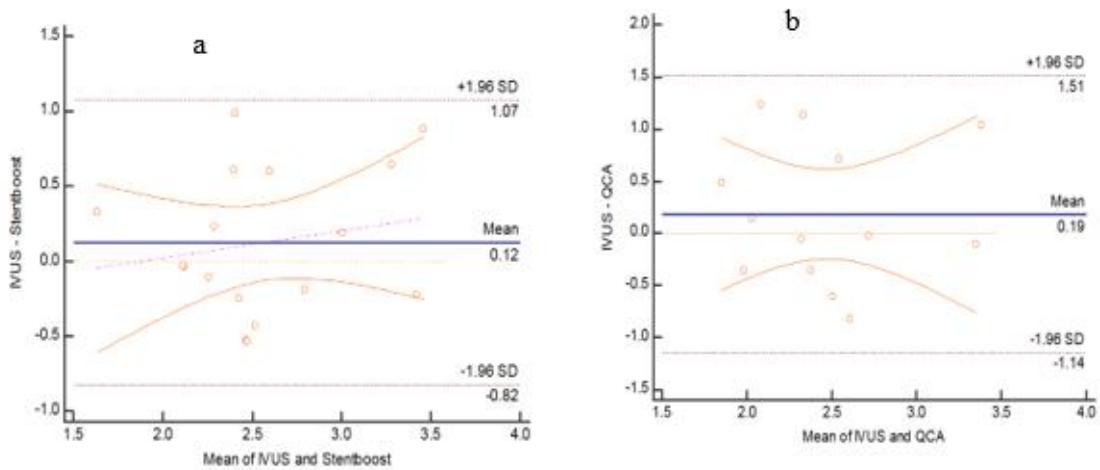


Fig. 1. Bland–Altman analysis: demonstrates good agreement in minimal stent diameter assessment between stent boost and IVUS (a) and suboptimal agreement between QCA and IVUS (b)

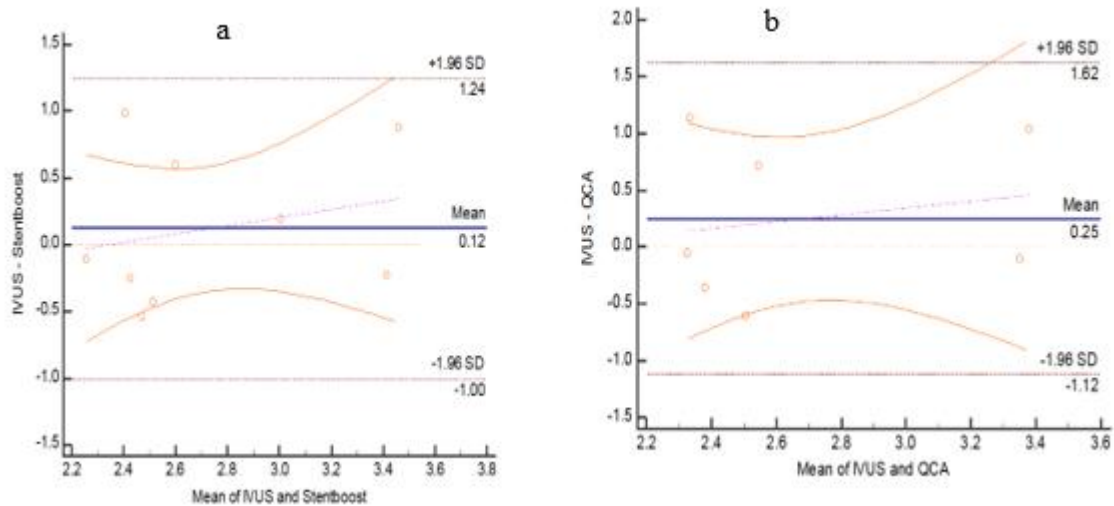


Fig. 2. Bland–Altman analysis in patients with Xience stent type: demonstrates optimal agreement in minimal stent diameter assessment between stent boost and IVUS (a) and suboptimal agreement between QCA and IVUS (b)

Chart 1. Plaque type and their frequency

N=21		
Plaque type	Fibrofatty	11(52.4%)
	Calcific	1(4.8%)
	Soft	3(14.3%)
	Mixed	6(28.6%)
RLA (mm ²)		9.15 ± 3.71
MLA (mm ²)		3.32 ± 0.774
Minimal stent area (mm ²)		6.53 ± 2.253

Data are presented as mean ± SD or frequency (%), RLA: reference luminal area, MLA: minimal luminal area

ROC curve analysis between IVUS and stent boost revealed that SB was able to detect optimal expansion with 100% sensitivity and 33.33% specificity (p-value=0.005, AUC=0.808). The specificity increased to 66.67% when the cut-off value criteria of MSD/distal RLD was 76% Fig. 3.

4. DISCUSSION

Even in the era of drug-eluting stents, coronary stent UE has a crucial role in the development of in-stent thrombosis and re-stenosis in patients undergoing PCI [1].

QCA showed that the occurrence of stent under expansion shares in stent thrombosis and restenosis [2].

IVUS permits a more accurate evaluation of stent expansion than QCA and identifies stent mal-apposition [1,3]. Multiple IVUS investigations have demonstrated that inadequate stent expansion and mal-apposition continue to be important predictors of stent thrombosis. This method is not used routinely in daily practice. IVUS is expensive, time-consuming, and practically requires a learning curve of operators and laboratory staff [4].

SBS is a recently discovered imaging technology that improves the stent's fluoroscopic visibility. By using motion-corrected acquisition frames, a clearer image of the stent and its relationship to the vessel wall may be acquired [13,14].

In our study, Stent boost vs QCA measurements post stenting revealed max SD with mean±SD of (3.52±0.524 vs 3.51±0.625), MSD with mean±SD of (2.50 ± 0.504 vs 2.38 ± 0.583), Symmetry index with mean±SD of (0.28±0.096 vs 0.33±0.091), SD at proximal edge with mean±SD of (3.08±0.730 vs 3.09±0.878) and SD at distal edge with mean±SD of (2.68 ± 0.584 vs 2.64 ± 0.611).

We measured the MSD by SBS in the appropriate projection view for the coronary segment that showed the clearest stent borders. We used the following SBS criteria to detect adequate stent expansion: stent minimum diameter ≥70% of reference diameter [4,15]. Seven individuals were identified as having insufficient stent expansion based on these criteria.

In Laimoud et al., [16] study, SBS parameters were; Max SD 3.55 ± 0.47 mm, Min SD 2.58 ±

0.56 mm, stent diameter 3.09 ± 0.58 mm and the stent symmetry index was 0.34 ± 0.09. As regard QCA assessment, Max SD 2.93 ± 0.61 mm, Min SD 1.83 ± 0.57 mm, stent diameter 2.5 ± 0.48 mm, acute gain 0.94 ± 0.43 and the stent symmetry index 0.14 ± 0.27.

Sanidas et al., [17] reported that following stent deployment Seven of the 42 stents were determined to be postdilated by the operator (16.7%) according to angiographic criteria only. After evaluating the ESI photos of these 7 stents, this conclusion did not alter. Of the remaining 35 stents, ESI made The physician changes his mind and postdilates ten of thirty-five stents (28.6%). Statistically, stents that required postdilatation based on ESI interpretation had a lower ESI minimum stent diameter (MSD) than those that did not (2.2 ± 0.3 mm vs. 2.6 ± 0.4mm, P = 0.0068).

In Tanaka et al., [18] stent boost MSD was 2.6 ± 0.5 mm. MSA was calculated by minimum stent diameters of two orthogonal directions and was 5.8 ± 2.1 mm². Seven cases were classified as having inadequate stent expansion by the pre-defined criteria [4,19].

4.1 Comparison between QCA to Stent Boost or IVUS

According to our results, QCA showed no statistically significant differences when compared to SB or IVUS regarding maximal, minimal, proximal edge or distal edge stent diameters and stent symmetry indices. Also, QCA showed no statistically significant differences when compared to SB regarding mean stent diameter. But generally QCA tended to underestimate stent measures compared to stent boost or IVUS measurements except for measurements at proximal or distal edges that we think it might be related to and affected by measurement reconstruction techniques.

In Laimoud et al., [16] study, Max SD was significantly more by IVUS vs QCA (p .009) and by SB vs QCA (p .001), MSD was significantly more by IVUS vs QCA (p .001) and SB vs QCA (p .001). The stent symmetry index was significantly higher by IVUS vs QCA (p .001) and between SB vs QCA (p .001). QCA had positive correlation with IVUS measures of Max SD (p < .0001 & r 0.69) and Min SD (p < .0001 & r 0.63). QCA had positive correlated with SB measures of Max SD (p < .0001 & r 0.61) and MSD (p .003 & r 0.49).

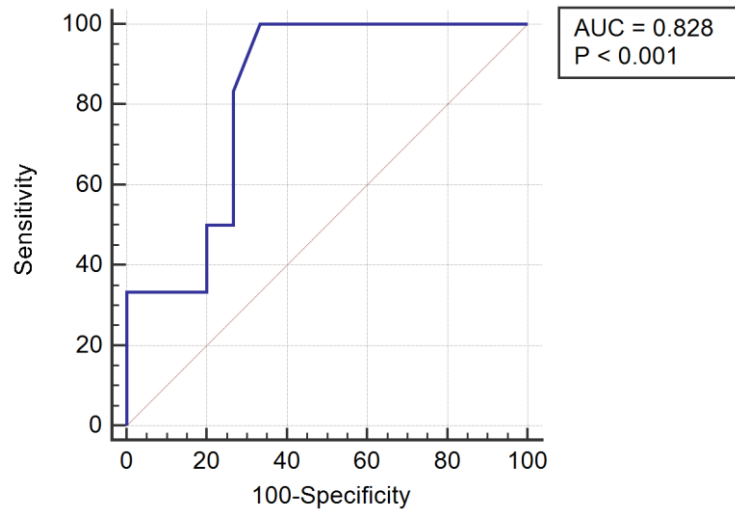


Fig. 3. ROC curve analysis between IVUS and stent boost
Case Presentation (I)

QCA, SB and IVUS measures of case (1)

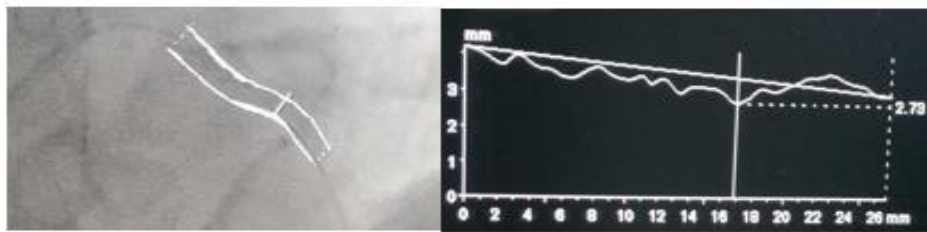


Figure (22): QCA measures (case1): MSD=2.73mm.

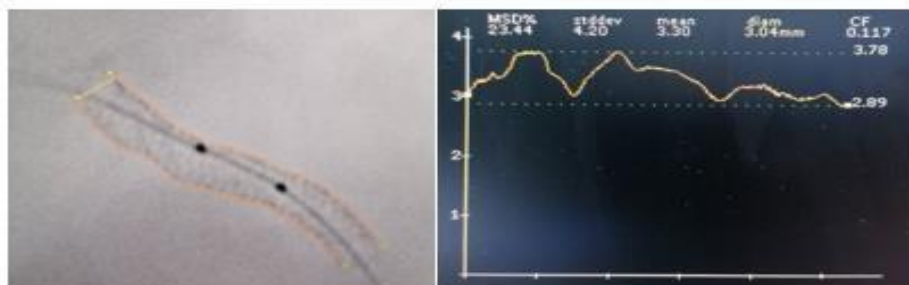


Figure (23): QCA measures (case1): Max SD=3.78mm, MSD=2.89mm.

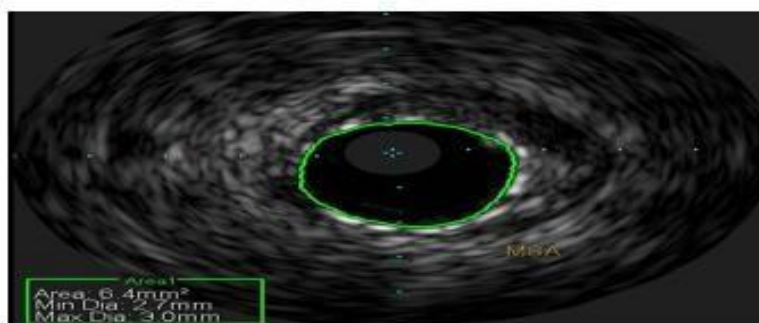


Figure (24): IVUS measures (case1): MSA=6.4mm², MSD=2.7mm.

CASE PRESENTATION (II)

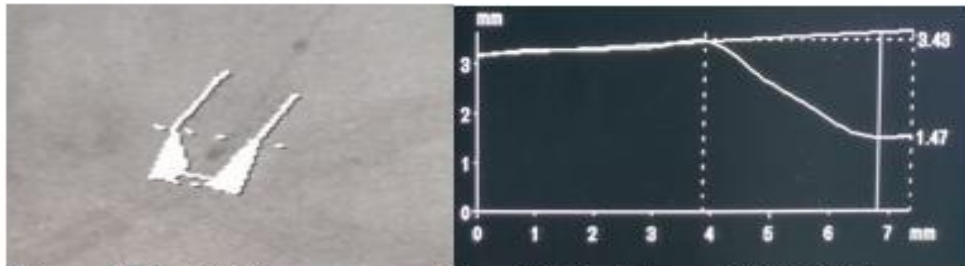


Figure (25): QCA measures: Max SD=3.43mm, MSD=1.47mm.

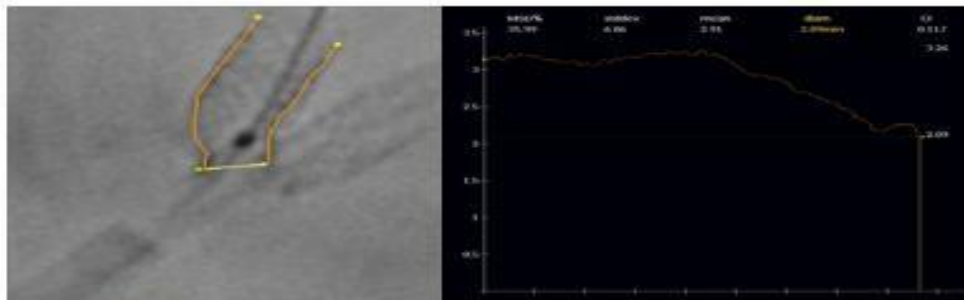


Figure (26): SB measures: Max SD=3.26mm, MSD=2.09mm.

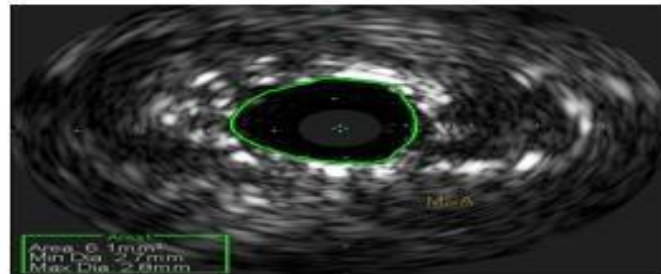


Figure (27): IVUS measures: MSA=6.1mm², MSD=2.7mm.

QCA, SB and IVUS measures of patient number (13):- ostial LAD stenting for 55 years old male, DM, HTN, DLP and smoker, complaining of exertional chest pain.

In Sanidas et al.,[17] study, QCA tended to underestimate the measures of MSD when compared to SB or IVUS (2.2 ± 0.5 vs 2.6 ± 0.4 vs 2.5 ± 0.5) but gives comparable measures of edge diameters (2.8 ± 0.5 vs 2.8 ± 0.4 vs 2.7 ± 0.5).

Our results were similar to data reported by Sanidas et al., [17] and can be interpreted as; 1) proximal and distal edges are fitted to reference luminal segments which almost have no plaque burden, 2) condensation of plaque burden and its probable protrusion through stent struts may

affect amount of residual lumen filled with dye, 3) technical issues related to edge deviations.

4.2 Correlation of Stent Boost and QCA to IVUS

In our study, there were insignificant differences between IVUS & SB regarding max SD, MSD, SI and stent diameters at proximal or distal stent edges. There were no detectable complications by IVUS post PCI.

Bland–Altman analysis: revealed good agreement between IVUS & SB regarding MSD but less agreement between QCA and IVUS. Also, when we compared Bland–Altman analysis in patients with Xience xpedition stent type (as the commonly used stent in our study), it demonstrated optimal agreement in MSD between SB and IVUS (might be resulting from the physical properties of Xience stent as regard metal type or strut thickness) and suboptimal agreement between QCA and IVUS.

ROC curve analysis: for comparison between SB and IVUS regarding detection of optimal stent expansion according to the predefined criteria [(MSA/distal RLA \geq 90% by IVUS) vs (MSD/distal RLD \geq 70% as a cutoff point by SB)] revealed that SB was able to detect optimal expansion with 100% sensitivity and 33.33% specificity (p-value=0.005, AUC=0.808). According to our results, the best stent boost cut off value criteria of MSD/distal RLD was 76% with 100% sensitivity and 66.67% specificity (p =0.005, AUC=0.808).

Tanaka et al., [18] and our study, showed that SB predicted insufficient IVUS findings with a 100% specificity, 33% sensitivity, and 81% agreement. Tanaka et al., [18] stated that Although the sensitivity of SB imaging for appropriate stent placement was low, its specificity was good enough for it to be the first line of monitoring in locations where IVUS is not commonly employed.

The findings of the present study are comparable to Cura et al., [20] study which analyzed 54 stents using IVUS, Stent Boost and QCA and there was good correlation between SBS and IVUS stent diameters and optimum compatibility between IVUS and SB although there was only little agreement between IVUS and QCA.

Sanidas et al., study [17], the ESI-based measures correlated better with IVUS (r = 0.721, P < 0.0001) compared to QCA with IVUS (r = 0.563, P < 0.0001). Analysis by Bland-Altman revealed a tendency toward greater concordance between ESI and IVUS than between QCA and IVUS (mean differences = 0.038 vs. 0.121; P = 0.19, respectively).

Yang et al., [21] study concluded that SB demonstrated higher correlations for IVUS-measured stent diameters compared to QCA. The strongest MLD correlations were between IVUS and SB (r= 0.979, P<0.0001) when

compared with QCA and SB (r=0.973, P <0.0001), and QCA and IVUS (r=0.964, P <0.0001).

Mishell et al., [22] study analyzed QCA, IVUS, and SBS measures of 48 coronary stents placed in 30 cases. They concluded that SBS exhibited greater correlations for IVUS-measured stent diameters compared to QCA, as minimum stent diameter correlations were best between IVUS and SBS (r = 0.75; P < 0.0001) when compared with QCA and IVUS (r= 0.65; P < 0.0001), and QCA and SBS (r = 0.49; P = 0.0004). IVUS and SBS revealed a negligible difference in minimal stent diameter, 0.043 mm (95% CI: 0.146–0.061 mm).

Zhang et al., [23] studied SBS imaging and IVUS following stenting of 58 ostial lesions in 55 individuals. All patients underwent SBS and IVUS to identify stent placement. A substantial positive correlation was established between MSA by SBS and MSA by IVUS, predicting poor stent placement revealed by IVUS 0.95 is the regression coefficient.

Alghamdi et al., [24] study analyzed ten patients had 13 coronary stents placed utilising QCA, IVUS, and SBS. Both SBS and QCA assessments of minimal stent diameter were shown to correlate with IVUS, however SB revealed an almost perfect direct association with IVUS. SBS measurements of minimal stent diameter demonstrated a higher association with IVUS measurements (r=0.93; P 0.0001) when compared with QCA and IVUS (r= 0.78; P 0.003).

Our results were similar to those of Laimoud et al., [16] study, in which there were insignificant differences between IVUS & SB regarding max SD (p 0.53) or MSA (p 0.07) and a significant positive correlations were observed between both techniques and maximum SD (p < .0001 & r 0.74) and MSD (p < .0001 & r 0.68). In addition, there was insignificant difference in stent symmetry index between IVUS and SB in the absence of a significant connection.

5. CONCLUSIONS

Stent boost showed good agreement to IVUS regarding MSD which became optimal agreement when done for Xience Xpedition stent (as the commonly used stent in our study). SB was able to detect optimal expansion compared to IVUS with 100% sensitivity and 66.67% specificity (p =0.005, AUC=0.808) at MSD / distal

RLD of 76% as a cut-off value criteria. There was less agreement between QCA and IVUS measures and hence less reliability in detecting stent under expansion. SB can be termed IVUS of the poor being readily available, easily interpretable, inexpensive and can reliably detects stent under expansion with less contrast and lower complications.

LIMITATIONS

Small number of cases due to high coast of IVUS catheters that precludes its use as a routine. Lack of follow up of cases after the procedure which prevented the assessment of MACE outcomes.

CONSENT AND ETHICAL APPROVAL

All patients provided written consent based on their knowledge. The study was done after approval from the Ethical Committee Tanta University Hospitals.

COMPETING INTERESTS

Authors have declared that no competing interests exist.

REFERENCES

1. Fujii K, Carlier SG, Mintz GS, Yang YM, Moussa I, Weisz G, et al. Stent underexpansion and residual reference segment stenosis are related to stent thrombosis after sirolimus-eluting stent implantation: an intravascular ultrasound study. *J Am Coll Cardiol.* 2005;45:995-8.
2. Serruys PW, Kay IP, Disco C, Deshpande NV, de Feyter PJ. Periprocedural quantitative coronary angiography after Palmaz-Schatz stent implantation predicts the restenosis rate at six months: results of a meta-analysis of the BELgian NETHERlands Stent study (BENESTENT) I, BENESTENT II Pilot, BENESTENT II and MUSIC trials. *Multicenter Ultrasound Stent In Coronaries. J Am Coll Cardiol.* 1999;34:1067-74.
3. Okabe T, Mintz GS, Buch AN, Roy P, Hong YJ, Smith KA, et al. Intravascular ultrasound parameters associated with stent thrombosis after drug-eluting stent deployment. *Am J Cardiol.* 2007;100:615-20.
4. Orford JL, Lerman A, Holmes DR. Routine intravascular ultrasound guidance of percutaneous coronary intervention: a critical reappraisal. *J Am Coll Cardiol.* 2004;43:1335-42.
5. Nguyen P, Seto A. Contemporary practices using intravascular imaging guidance with IVUS or OCT to optimize percutaneous coronary intervention. *Expert Rev Cardiovasc Ther.* 2020;18:103-15.
6. Nissen SE, Yock P. Intravascular ultrasound: novel pathophysiological insights and current clinical applications. *Circulation.* 2001;103:604-16.
7. Räber L, Mintz GS, Koskinas KC, Johnson TW, Holm NR, Onuma Y, et al. Clinical use of intracoronary imaging. Part 1: guidance and optimization of coronary interventions. An expert consensus document of the European Association of Percutaneous Cardiovascular Interventions. *Eur Heart J.* 2018;39:3281-300.
8. Subban V, Raffel O, Vasu N, Victor S, Sankardas MA. Editorial Review Intravascular Ultrasound and Optical Coherence Tomography for the Assessment of Coronary Artery Disease and Percutaneous Coronary Intervention Optimization: Specific Lesion Subsets. *Indian Heart J.* 2019;1:95-123.
9. Zhang J, Gao X, Kan J, Ge Z, Han L, Lu S, et al. Intravascular Ultrasound Versus Angiography-Guided Drug-Eluting Stent Implantation: The ULTIMATE Trial. *J Am Coll Cardiol.* 2018;72:3126-37.
10. Subban V, Raffel O, Vasu N, Victor S, Sankardas MA. Editorial Review Intravascular Ultrasound and Optical Coherence Tomography for the Assessment of Coronary Artery Disease and Percutaneous Coronary Intervention Optimization: The Basics. *Indian Heart J.* 2019;1:71-94.
11. Close RA, Abbey CK, Whiting JS, editors. Improved image guidance of coronary stent deployment. *Medical Imaging 2000: Image Display and Visualization; 2000: International Society for Optics and Photonics.*
12. Tomasello SD, Costanzo, L., Galassi, A. R. Advances in the Diagnosis of Coronary Atherosclerosis. *QCA.* 2011;31:255-72.
13. De Scheerder I, De Man F, Herregods MC, Wilczek K, Barrios L, Raymenants E, et al. Intravascular ultrasound versus angiography for measurement of luminal diameters in normal and diseased coronary arteries. *Am Heart J.* 1994; 127:243-51.

14. Williams B, Mancia G, Spiering W, Agabiti Rosei E, Azizi M, Burnier M, et al. 2018 ESC/ESH Guidelines for the management of arterial hypertension: The Task Force for the management of arterial hypertension of the European Society of Cardiology and the European Society of Hypertension: The Task Force for the management of arterial hypertension of the European Society of Cardiology and the European Society of Hypertension. *J Hypertens*. 2018;36:1953-2041.
15. Koolen J, Veer M, Hanekamp C. StentBoost image enhancement: first clinical experience. *Kontraste (Hamburg)*. 2005;49:4-8.
16. Laimoud M, Nassar Y, Omar W, Abdelbarry A, Elghawaby H. Stent boost enhancement compared to intravascular ultrasound in the evaluation of stent expansion in elective percutaneous coronary interventions. *Egypt Heart J*. 2018;70:21-6.
17. Sanidas EA, Maehara A, Barkama R, Mintz GS, Singh V, Hidalgo A, et al. Enhanced stent imaging improves the diagnosis of stent underexpansion and optimizes stent deployment. *Catheter Cardiovasc Interv*. 2013;81:438-45.
18. Tanaka N, Pijls NH, Koolen JJ, Botman KJ, Michels HR, Brueren BR, et al. Assessment of optimum stent deployment by stent boost imaging: comparison with intravascular ultrasound. *Heart Vessels*. 2013;28:1-6.
19. Jin Z, Yang S, Jing L, Liu H. Impact of StentBoost subtract imaging on patient radiation exposure during percutaneous coronary intervention. *Int J Cardiovasc Imaging*. 2013;29:1207-13.
20. Cura F, Albertal M, Candiello A, Nau G, Bonvini V, Tricherri H, et al. StentBoost Visualization for the Evaluation of Coronary Stent Expansion During Percutaneous Coronary Interventions. *Cardiol Ther*. 2013;2:171-80.
21. Yang FF, Zhang LW, Huang DS, Shen D, Sun HY, Zhang CH, et al. A novel angiographic technique, StentBoost, in comparison with intravascular ultrasound to assess stent expansion. *Chin Med J (Engl)*. 2011;124:939-42.
22. Mishell JM, Vakharia KT, Ports TA, Yeghiazarians Y, Michaels AD. Determination of adequate coronary stent expansion using StentBoost, a novel fluoroscopic image processing technique. *Catheter Cardiovasc Interv*. 2007;69:84-93.
23. Zhang J, Duan Y, Jin Z, Wei Y, Yang S, Luo J, et al. Stent boost subtract imaging for the assessment of optimal stent deployment in coronary ostial lesion intervention: comparison with intravascular ultrasound. *Int Heart J*. 2015;56:37-42.
24. Alghamdi A, Al-khaldi A, Balgaith M, Ayoub K. Stent boost versus intravascular ultrasound to determine stent expansion. *J Saudi Heart Assoc*. 2012;24:283.

© 2022 Omran et al.; This is an Open Access article distributed under the terms of the Creative Commons Attribution License (<http://creativecommons.org/licenses/by/4.0>), which permits unrestricted use, distribution, and reproduction in any medium, provided the original work is properly cited.

Peer-review history:

The peer review history for this paper can be accessed here:
<https://www.sdiarticle5.com/review-history/88425>