



Hepatopulmonary Syndrome in a Nigerian Man with Decompensated Alcoholic Liver Cirrhosis

**Chinwe Philomena Onyia^a, Olive Obienu^a, Promise Asogwa^a, Winifred Adiri^a,
Ugochukwu Nwoko^a, Uchenna Nkemdilim Ijoma^{a,b*}
and Sylvester Chuks Nwokediuko^{a,b}**

^a *Gastroenterology Unit, Department of Medicine, University of Nigeria Teaching Hospital, Ituku-Ozalla, Enugu, Nigeria.*

^b *Department of Medicine, Faculty of Medical Sciences, College of Medicine, University of Nigeria, Ituku-Ozalla Campus, Enugu, Nigeria.*

Authors' contributions

This work was carried out in collaboration among all authors. The patient presented in this case report was managed by all the authors. A unanimous decision was made to report the case. Authors CPO and UNI drafted the manuscript. Author UNI was responsible for language and technical editing. All authors reviewed and approved the manuscript.

Article Information

DOI: 10.9734/JAMMR/2022/v34i234842

Open Peer Review History:

This journal follows the Advanced Open Peer Review policy. Identity of the Reviewers, Editor(s) and additional Reviewers, peer review comments, different versions of the manuscript, comments of the editors, etc are available here: <https://www.sdiarticle5.com/review-history/92816>

Case Report

**Received 17 August 2022
Accepted 23 October 2022
Published 27 October 2022**

ABSTRACT

Hepatopulmonary syndrome is a rare complication of liver disease and portal hypertension. It has not been previously described in medical literature in Nigeria. We report this case of a 64-year-old man who presented with a 3 months' history of recurrent breathlessness, platypnoea and leg swelling. He had been diagnosed with liver cirrhosis and had variceal band ligation in 2018, and had been managed for 2 episodes of hepatic encephalopathy prior to referral. Physical examination showed he was in respiratory distress, centrally cyanosed, had grade 4 digital clubbing, tachypnoea, platypnoea, orthodeoxia and bibasal coarse crepitations. He also had a non-tender hepatomegaly, splenomegaly and ascites with no leg edema. Investigations showed negative screening for hepatitis B and C, elevated AST and GGT, conjugated hyperbilirubinemia, hypoalbuminemia, negative COVID-19 test, polycythemia, thrombocytopenia, prolonged INR and coarse enlarged liver with irregular margins on ultrasound. Gastroscopy revealed Grade 3 oesophageal varices, Forrest 3 pre-pyloric ulcer and portal hypertensive gastropathy. Spirometry

*Corresponding author: E-mail: uchenna.ijoma@unn.edu.ng;

demonstrated a restrictive pattern of airflow limitation. Contrast echocardiography demonstrated intrapulmonary shunt. Alpha-1- anti-trypsin was not deficient. The peripheral cyanosis resolved with oxygen therapy. He was initially commenced on pentoxifylline but terminated therapy due to side effects.

The relevant literature was reviewed. Liver transplantation is the only effective therapy for HPS and prompt recognition and referral for transplant is key.

We therefore present the first documented and published case of hepatopulmonary syndrome in Nigeria and the West African sub-region.

Keywords: Hepatopulmonary syndrome; Nigeria; alcoholic liver cirrhosis.

1. INTRODUCTION

Hepatopulmonary Syndrome (HPS) is an important cause of dyspnoea and hypoxia in the setting of liver disease. HPS is defined as the triad of an arterial oxygenation defect, intrapulmonary vasodilation and the presence of liver disease [1]. It is due to vasodilation and angiogenesis in the pulmonary vascular bed, which leads to ventilation-perfusion mismatching, diffusion limitation to oxygen exchange, and arterio-venous shunting. HPS is characterized by the appearance of persistent hypoxemia in a patient with hepatic disease and vascular lung dilation. The vascular component includes diffuse or local dilation of the pulmonary capillaries, and less commonly includes pulmonary arteriovenous shunts.

It is usually diagnosed in patients with cirrhosis, but neither cirrhosis nor portal hypertension is a pre-requisite for the diagnosis as it has been reported in non-cirrhotic hepatitis [2] and non-cirrhotic portal hypertension [3].

Limited data suggest that a slightly lower prevalence of 4-33% exists in the overall cirrhotic population [4-6]. Anand and coworkers reported a prevalence of 17.5% in confirmed cirrhotics, 13.3% in patients with non-cirrhotic portal fibrosis and 10% in patients with extrahepatic portal vein obstruction in a study of 138 patients [7]. HPS has also been documented in adolescents and young adults. Slowik et al published a case report of HPS in an adolescent with aberrant intrahepatic portal venous circulation in the absence of preexisting liver disease [8].

Liver transplantation (LT) is the most effective treatment. Early recognition and prompt referral for liver transplantation is key to ensuring better outcome. This case report is important because to the best of our knowledge, it is the first documented case in Nigeria and West African sub- region.

2. CASE PRESENTATION

A 64-years old Nigerian male farmer of Igbo tribe was seen at the Medical Outpatient Department of the University of Nigeria Teaching Hospital (UNTH), Enugu, Nigeria, in August 2020. He was referred on account of recurrent breathlessness and bilateral leg swelling of 3 months' duration. The breathlessness was worse on standing and better on lying down, mild exertion and present even at rest. There was no orthopnoea, paroxysmal nocturnal dyspnoea, wheeze, cough, palpitations nor chest pain. He did not have fever and had not lost weight. He also developed bilateral leg swelling but no abdominal, facial swelling, reduction in urine volume nor excessive frothiness of urine. There was no jaundice, pruritus nor right upper quadrant pain.

He took about 21 units of alcohol weekly for 30 years and stopped about 2 years ago on medical advice.

He had haematemesis about 2 years previously, following an armed robbery incident when he was kicked on the chest. After stabilization, he decided to go to India for further treatment. At India, a diagnosis of decompensated liver cirrhosis was made and gastroscopy showed grade 3 oesophageal varices and portal hypertensive gastropathy. Endoscopic variceal band ligation was done. He also had haemorrhoidectomy which was complicated by massive anal bleeding post-surgery. He was unconscious for about 6 days and received about 27 units of blood. After recovery, he was advised to see a hepatologist in Nigeria for further management.

He had been managed twice for hepatic encephalopathy. On account of the persistent breathlessness, he was initially diagnosed with obstructive airway disease and used bronchodilator/steroid inhalers. However, his symptoms did not improve necessitating

presentation to a hepatologist at a private hospital where he was noted to be centrally cyanosed with SpO₂ of 82%. He was then referred to UNTH for further management. He is not known to have hypertension nor diabetes mellitus. He had no significant family history and did not take tobacco in any form.

Physical examination showed he was chronically ill looking, in respiratory distress with intercostal recessions, centrally cyanosed, with grade 4 digital clubbing, had leuconychia, dusky fingers and toes and no leg oedema. Pulse rate was 76 beats/min, bounding and regular. Blood pressure was 100/50 mmHg right arm, sitting. Jugular venous pulsation was not raised. Apex beat was displaced and heaving. 1st and 2nd heart sounds were heard, with a grade 3 apical pansystolic murmur radiating to the axilla. There was no parasternal heave. Respiratory rate was 36 breaths/minute with platypnoea and orthodeoxia-SpO₂ 82% sitting, 90% supine. There were coarse crepitations at the lung bases. Abdominal examination revealed a non-tender hepatomegaly (8cm below the costal margin), mostly the left lobe of the liver which had a smooth surface and firm in consistency. Liver span was 18cm. There was also splenomegaly (6cm) and ascites demonstrable by shifting dullness. He was conscious, well oriented and had no flapping tremor.

A diagnosis of hepatopulmonary syndrome to rule out portopulmonary syndrome in a patient with Decompensated Alcoholic Liver Cirrhosis (Child-Tucotte-Pugh Class B, MELD Na - Score 16) was made. A second diagnosis of valvular heart disease was entertained.

Relevant investigations were requested for and their results were obtained as shown in Tables 1 and 2.

Other results: COVID-19 screening was negative.

Abdominal ultrasound scan showed coarse heterogenous liver with irregular margins and echogenic fibrotic bands measuring 16.8cm. The splenic span was 12.8cm, portal vein measured 9mm with no ascites nor retroperitoneal lymphadenopathy.

Gastroscopy revealed grade 2 oesophageal varices with no high risk signs, Forrest 3 pre-pyloric ulcer and portal hypertensive gastropathy.

Chest X-ray findings were cardiomegaly, prominent aortic knuckle with patchy line and cystic shadows at the perihilar, mid and lower lung zones while echocardiography showed degenerative valvular heart disease with regurgitation and contrast echocardiography with agitated saline demonstrated pulmonary arteriovenous shunt. (See Fig. 1).

Chest CT scan showed congestion/prominence of the pulmonary vessels especially in the lower lung zones posteriorly (See Fig. 2).

Alpha -1 antitrypsin was not deficient.

The patient was admitted and treated with antibiotics, laxatives, diuretics, Intranasal oxygen (100%) at 5L/min via nasal prongs and β blocker to reduce portal pressure. There was further review by the respiratory unit of the hospital who additionally noted an SpO₂ of 88% in room air sitting with variations in fingers, 94% in the right middle fingers, while the left fingers are between 87-88% sitting but no much variation with supine position.

His breathlessness reduced markedly, peripheral cyanosis resolved though he was still centrally cyanosed. His SpO₂ improved to 90% on O₂. He was discharged home after 1 week of admission on the above medications to continue intranasal oxygen at least 10 hours at night. On follow up visit 2 weeks later, he complained of increased breathlessness and SpO₂ measured at home was initially 82% but had recently been fluctuating between 76-79%. He was commenced on tabs pentoxifylline 400mg daily for 2 weeks in addition to his previous medications. On further follow up visit, patient had stopped tabs pentoxifylline on account of generalized body weakness, dizziness and chest heaviness. The Spo₂ was 82% while supine and 79% on standing. He also received intravenous 20% salt poor albumin on account of hypoalbuminemia.

2.1 Spirometry

FEV ₁ (forced expiratory volume in 1 second)	81.8%
FVC (forced vital capacity)	2.36L (74% predicted)

Impression- restrictive pattern (acceptability pattern not met)

COVID-19 Screening	Negative
HbsAg (Hepatitis B surface antigen)	Negative
HCV (Hepatitis C virus) antibody	Negative
HIV (Human immunodeficiency virus) antibody	Negative

2.2 Urinalysis

PH 7.0, Specific gravity 1.010, Leucocyte +, Nil Nitrites, protein, glucose, blood.

3. DISCUSSION

Hepatopulmonary syndrome is a triad of an arterial oxygenation defect, intrapulmonary vasodilation and the presence of liver disease [1]. It is an important cause of dyspnoea and hypoxia in a setting of liver disease, occurring in about 10-30% of patients with cirrhosis [9]. Most studies have been conducted in patients with advanced liver disease undergoing assessment

Table 1. Results of laboratory investigations

Test	Result	Range	Unit
Liver function test			
ALP	105.6	40-129	U/L
ALT	31	Up to 40	U/L
AST	55.2	Up to 40	U/L
GGT	73.2	6-61	U/L
T.Bil	64.1	<21	umol/L
D.Bil	36	<5	umol/L
Total protein	70.8	64-83	g/L
Serum Albumin	25.6	35-50	g/L
Serum Globulin	45.2	18-36	g/L
Electrolytes, urea, creatinine			
Na ⁺	136	135-145	mmol/L
K ⁺	3.8	3.5-5.0	mmol/L
Cl ⁻	107		mmol/L
HCO ₃ ⁻	14.99	22-29	mEq/L
Urea	3	2.5-6.5	mmol/L
Creatinine	40.24	<97	umol/L
Full blood count			
Haemoglobin	16.6	14-16	g/dL
Platelets	81,000	150,000-450,000	10 ⁹ /l
WBC	4,400	4,000-9,000	10 ⁹ /l
Prothrombin Time	16.5	10-15	seconds
INR	1.424		
FBG	99	60-110	mg/dL

ALP; alkaline phosphatase, ALT; alanine transaminase, AST; aspartate transaminase, GGT; gamma glutamyl transpeptidase, T.Bil; total bilirubin, D.Bil; direct bilirubin, Na⁺;sodium, K⁺; pottasium, Cl⁻; chloride, HCO₃⁻; bicarbonate, WBC; white blood cells, INR; international normalized ratio, FBG; fasting blood glucose, U/L; unit per litre, unmol/l; micromole per litre, mEq/L; miliequivalent per litre. g/L; gram per litre, mmol/l; milimole per litre, g/dl; gram per deciliter, mg/dl; milligram per deciliter

Table 2. Results of laboratory investigations

Arterial blood gases	24/09/20	04/02/21	Reference range	Units
PH	7.498	7.492	7.310-7.410	
PCO ₂	22.9	27.7	41-51	mmHg
PO ₂	99	37	80--105	mmHg
HCO ₃	17.7	21.2	23-28	mmol/L
TCO ₂	18	22	24-29	mmol/L
SO ₂	98%	76%	95-100	
Lactic acid	1.27	2.32	0.36-1.25	mmol/L

pH; acidity/alkalinity, PCO₂; partial pressure of carbondioxide, PO₂; partial pressure of oxygen, TCO₂; total carbondioxide, SO₂; oxygen saturation

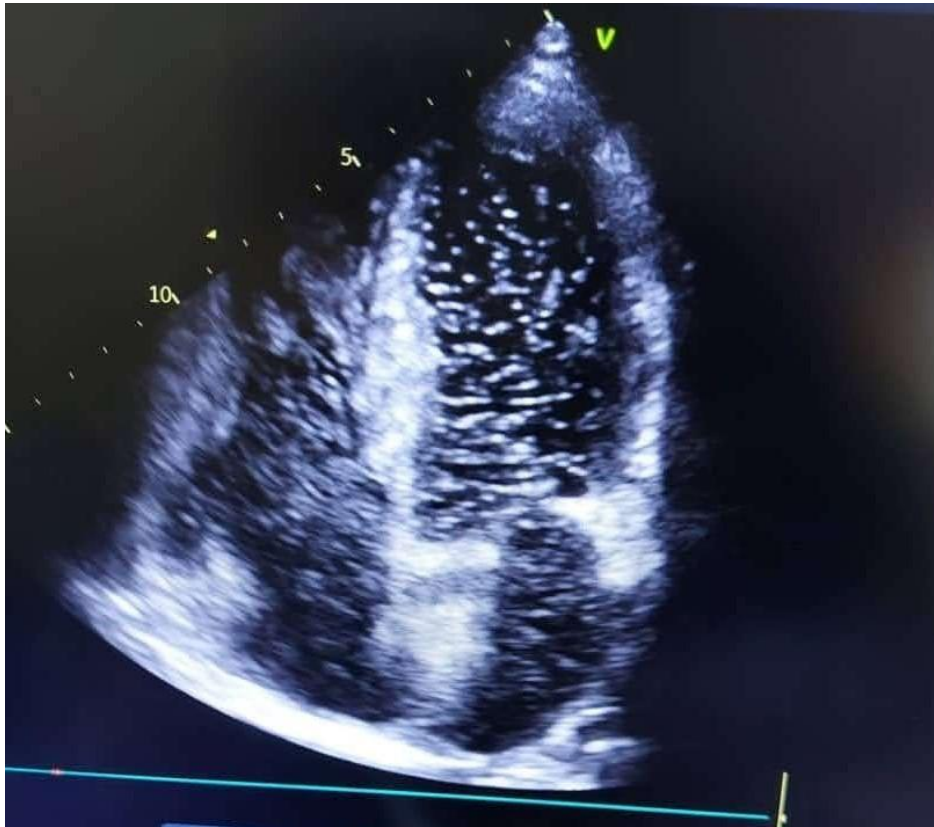


Fig. 1. Contrast Echocardiography with agitated saline showed bubble appearance in left atrium and left ventricle after 3rd cardiac cycle suggestive of right to left intrapulmonary shunting

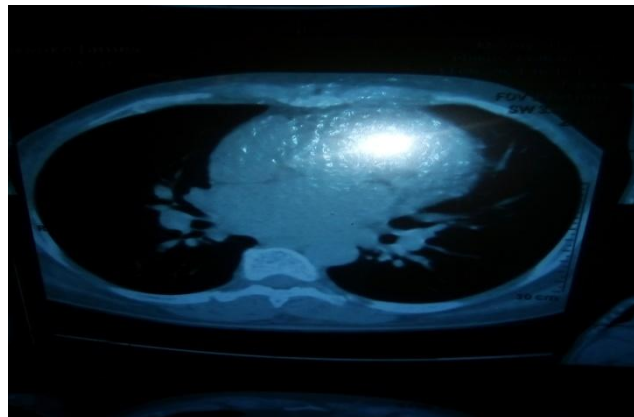


Fig. 2. Chest CT Scan of the index patient showing prominent/engorged pulmonary vein

for liver transplantation, in whom the prevalence ranges from 16-33% [4,5].

It is usually diagnosed in patients with cirrhosis, as in our index patient who also had features of portal hypertension but neither cirrhosis nor portal hypertension is a pre-requisite for the diagnosis. Manifestations include dyspnoea which is present in 50% of patients with HPS,

[10] a more specific symptom is platypnoea (dyspnoea that increases from supine to the erect posture) and orthodeoxia (hypoxia that is worse when erect). The index patient presented with all these features and was erroneously diagnosed with obstructive airway disease and used inhalers for a while, but discontinued with no improvement of symptoms. Digital clubbing is very common and may be found in up to 50% of

HPS [11]. The rare combination of clubbing and cyanosis in a cirrhotic patient as was seen in the index patient is highly suggestive of severe HPS [12].

The diagnosis of HPS is made by determination of arterial hypoxemia and demonstration of intrapulmonary vasodilatation. The index patient met all the diagnostic criteria. Screening for arterial hypoxemia in HPS can be done using a pulse oximeter. This is an accurate, reliable and non-invasive tool useful for monitoring in the outpatient setting. Cut-off value $\leq 97\%$ provides a high sensitivity and moderate specificity for an arterial oxygen tension (PaO_2) ≤ 70 mmHg [13]. It can also demonstrate orthodeoxia as was demonstrated in the index patient.

Arterial blood gas (ABG) estimation is used for diagnosis of HPS and should be undertaken with the patient in a sitting position and breathing room air. Recommended cut-off values for the diagnosis of HPS are $\text{PaO}_2 \leq 80$ mmHg or PA-aO_2 (alveolar-arterial oxygen gradient) ≥ 15 mmHg or ≥ 20 mmHg in the elderly [1]. Based on ABG values, HPS can be classified as mild (≥ 80 mmHg), moderate (60-79 mmHg), severe (< 60 - ≥ 50 mmHg), very severe (< 50 mmHg) [1]. The initial arterial blood gas estimation of the index patient was > 80 mmHg which placed the patient in the mild category. This was probably due to the fact that the test was done when the patient was on supplemental oxygen while on admission. A follow up visit repeat arterial blood gas estimation done 4 months later showed PO_2 of 37 mmHg (severe hypoxemia). The presence of cyanosis and digital clubbing suggested severe HPS.

The gold standard for diagnosis of HPS is the demonstration intrapulmonary vasodilation using bubble contrast echocardiography using agitated saline and is more sensitive but less specific than macroaggregated albumin perfusion lung scan [11]. Contrast echocardiography is performed by injecting a contrast material, usually agitated saline. Normally, the contrast opacifies only the right heart chambers because it is filtered by the pulmonary capillary bed. However, contrast may opacify the left heart chamber if a right to left intracardiac or intrapulmonary shunting is present. With an intracardiac shunt, contrast appears in the left heart within three heart beats after injection of contrast but for an intrapulmonary shunt, contrast appears in the left heart three to six heart beats after its appearance in the right heart [14] as it occurred in our index patient. see Fig. 1.

Medical therapy for HPS has not shown much benefit. Oxygen therapy is given for symptomatic relief and prevention of end-organ damage. Specific treatment for HPS have been targeted at various pathophysiologic mechanisms such as the role of inducible Nitric oxide, endothelin-1, endotoxemia and TNF- α without much success. Use of pharmacologic agents such as somatostatin analogues, Norfloxacin, methylene blue, pentoxifylline, N-acetylcysteine, iloprost, Quercetin and MMF have been disappointing [15-17]. Given the role of TNF in HPS pathogenesis, Pentoxifylline has been trialed in a small number of patients with HPS but failed to improve arterial oxygenation. In addition, the treatment was poorly tolerated and often discontinued, making interpretation difficult [17]. The index patient was also commenced on pentoxifylline but therapy was terminated after 8 days on account of severe side effects.

Use of sorafenib, a protein kinase inhibitor, for prevention of HPS, alteration of the alveolar-arterial oxygen gradient, reduction in intrapulmonary angiogenesis, reduction in plasma VEGF levels and eventual shunting in the pulmonary vasculature have been successfully demonstrated on rat models with liver cirrhosis [18]. Theysohn et al have also confirmed that sorafenib is beneficial in the reduction of intrapulmonary shunt in HPS secondary to advanced hepatocellular carcinoma [19].

Liver transplantation remains the only effective treatment for HPS. Prognosis is worst in those with severe hypoxia, with most patients with $\text{PaO}_2 < 60$ mmHg dying within 6 months [20]. This finding has led to the concept of the "transplant window" for patients with HPS, in which patients with PO_2 less than 60 mmHg are prioritized for LT while those with more severe prognosis are excluded because of their post-transplant prognosis. Complete regression of HPS is observed only in about 80% of patients within 1 year [20]. The presence of severe degenerative valvular disease is an absolute contraindication for liver transplant in the index patient.

4. CONCLUSION

HPS is complication of liver disease with increased risk of mortality. We present the first reported case of suspected HPS in a Nigerian man presenting with platypnoea and orthodeoxia on a background of decompensated alcoholic liver cirrhosis and valvular heart disease. All cirrhotic patients with or without portal

hypertension should be routinely screened for HPS with a pulse oximeter to detect arterial hypoxemia. Early detection of HPS and prompt referral for liver transplant offers the best chance of survival.

CONSENT

The authors certify that they have obtained written informed consent from the patient and permission has given for his clinical information to be reported in a scientific journal. The patient understands that his initials will not be published and due effort will be made to conceal his identity, but anonymity cannot be guaranteed.

ETHICAL APPROVAL

It is not applicable.

COMPETING INTERESTS

Authors have declared that no competing interests exist.

REFERENCES

1. Rodriguez-Roisin R, Krowa MJ, Herve P, Fallon MB. Pulmonary-hepatic vascular disorders (PHD). *Eur. Respir. J.* 2004; 24:861-80.
2. Wolfe JD, Tashkin DP, Holly FE, Brachman MB, Genovesi MG. Hypoxia of cirrhosis, detection of abnormal channels by a quantitative radionuclide method. *American J of Medicine* 1977;63:746-754.
3. Babbs C, Warnes TW, Haboubi NY. Non-cirrhotic portal hypertension with hypoxemia. *Gut.* 1998;29:129-131.
4. Stoller JK, Lange PA, Westveer MK, Carey WD, Vogt D, Henderson JM. Prevalence and reversibility of the hepatopulmonary syndrome after liver transplantation—The Cleveland Clinic experience. *Western J Med.* 1995;163(2):133–138.
5. Martínez GP, Barberà JA, Visa J, Rimola A, Pare JC, Roca J et al. Hepatopulmonary syndrome in candidates for liver transplantation. *J Hepatol.* 2001;34(5): 651–657. DOI: 10.1016/s0168-8278(00)00108-2.
6. Pascasio JM, Grilo I, Lopez-Pardo FJ, Ortega-Ruiz F, Tirado JL, Sousa JM et al. Prevalence and severity of hepatopulmonary syndrome and its influences on survival in cirrhotic patients evaluated for liver transplantation. *American J Transplantation.* 2014;14(6): 1391-1399. DOI:https://doi.org/10.1111/ajt.12713
7. Anand AC, Mukherjee D, Rao KS, Seth AK. Hepatopulmonary syndrome: prevalence and clinical profile. *Indian J Gastroenterol.* 2001 Jan-Feb;20(1):24-7. PMID: 11206870.
8. Slovik K, Hildreth A, Pacheco CM, Fim LS, King, Shiravam G, Files M, Hsc EK, Horslen S. Hepatopulmonary syndrome in an adolescent with insidious hypoxia and small intrahepatic portal venous shunt. *Pediatric and Developmental Pathology.* 2020;(23)6. DOI:https://doi.org/10.1177//1093526620945951.
9. Grace JA, Angus PW. Hepatopulmonary syndrome: Update on recent advances in pathophysiology, investigation and treatment. *J of Gastroenterol Hepatol.* 2013;28:213-19.
10. Moller S, Krag A, Madsen JL, Henriksen JH, Bendtsen F. Pulmonary dysfunction and hepatopulmonary syndrome in cirrhosis and portal hypertension. *Liver Int.* 2009;29:1528-37.
11. Fallon MB, Abrams GA. Pulmonary dysfunction in chronic liver disease. *Hepatology.* 2000;32: 859-65.
12. Fallon MB, Krowka MJ, Brown RS, Trotter JF, Zacks S, Roberts KE, et al. Impact of hepatopulmonary syndrome on quality of life and survival in liver transplant candidates. *Gastroenterology.* 2008; 135(4):1168-75. DOI:10.1053/j.gastro.2008.06.03.
13. Abrams GA, Sanders MK, Fallon MB. Utility of pulse oximeter in the detection of arterial hypoxemia in liver transplant candidates. *Liver Transpl.* 2002;8:391-6.
14. Khabbaza JE, Krasuski RA, Tonelli AR. Intrapulmonary shunt confirmed by intracardiac echocardiography in the diagnosis of hepatopulmonary syndrome. *Hepatology.* 2013;58:1514-15.
15. Eshraghian A, Kamyab A, Yoon SK. Pharmacological treatment for hepatopulmonary syndrome. *BioMed Research International.* 2013;670139. DOI:http://dx.doi.org/10.1155/2013/670139
16. Schenk P, Madl C, Rezaie-majid S, Lehr S, Muller C. Methylene blue improves the

- hepatopulmonary syndrome. Ann Intern Med. 2000;133:701.
17. Krug S, Seyfarth HJ, Hagendorff A, et al. inhaled iloprost for hepatopulmonary syndrome: improvement of hypoxemia. Eur J Gastroenterol Hepatol. 2007;19: 1140
 18. Chang CC, Chuang CL, Lee FY, Wang SS, Lin HC, Huang HU et al. Sorafenib treatment improves hepatopulmonary syndrome in rats with biliary cirrhosis. Clinical Sciences. 2013;14(7): 457-466.
 19. Theysohn JM, Schlaak JF, Muller S, Ertle J, Schlosser TW, Bockisch A, et al. Selective internal radiation therapy of hepatocellular carcinoma: potential hepatopulmonary shunt reduction after sorafenib administration. Journal of Vascular and Interventional Radiology. 2012;23(7):949-52.
 20. Swanson KL, Wiesner RH, Krowka MJ. Natural history of hepatopulmonary syndrome: Impact of liver transplantation. Hepatology. 2005;41 (5):1122-1129. DOI:10.1002/hep.20658.

© 2022 Onyia et al.; This is an Open Access article distributed under the terms of the Creative Commons Attribution License (<http://creativecommons.org/licenses/by/4.0>), which permits unrestricted use, distribution, and reproduction in any medium, provided the original work is properly cited.

Peer-review history:

The peer review history for this paper can be accessed here:

<https://www.sdiarticle5.com/review-history/92816>