



Comparative Study between Open Surgical Drainage and Closed Technique of Percutaneous Aspiration under Image Guidance for Management of Breast Abscess

Chetna Dilip Rathi^{1*} and Meenakshi Yeola (Pate)¹

¹Department of General Surgery, Jawaharlal Nehru Medical College, Datta Meghe Institute of Medical Sciences, Wardha, India.

Authors' contributions

This work was carried out in collaboration between both authors. Author CR designed the study, performed the statistical analysis, wrote the protocol and wrote the first draft of the manuscript. Author MY managed the analyses of the study, taught and supervised the procedure, managed the literature search. All authors read and approved the final manuscript.

Article Information

DOI: 10.9734/JPRI/2021/v33i33A31765

Editor(s):

(1) Dr. Mohamed Salem Nasr Allah, Weill Cornell Medical College, Qatar.

Reviewers:

(1) Dominic Augustine, Ramaiah University of Applied Sciences, India.

(2) Syed Suhail Hamdani, University of Kashmir, India.

Complete Peer review History: <http://www.sdiarticle4.com/review-history/68570>

Study Protocol

Received 25 March 2021

Accepted 31 May 2021

Published 22 June 2021

ABSTRACT

Background: The conventional surgical management of breast abscesses consists of an incision taken over the point at which there is maximum fluctuation (or pain) and breaking of the abscess septa by digits. Now antibiotics and repeated abscess aspiration under USG guidance is new minimally invasive method which is on rise

Objectives:

1. To study the outcome of open technique of breast abscess management.
2. To study the outcome of closed technique of breast abscess management.
3. To compare the outcome of open v/s closed technique of surgical management of breast abscess.

Methodology: Sample will be divided into two groups and type of treatment i.e open incision and drainage or percutaneous aspiration under guidance will be decided randomly by chit system.

Expected Results: Feasibility and outcome of Percutaneous drainage is better than incision and drainage

Conclusion: First line management of Breast abscess will soon be percutaneous drainage under USG guidance.

Keywords: Breast abscess; percutaneous aspiration; open surgical drainage.

1. BACKGROUND

The conventional surgical treatment of breast abscesses consists of an incision taken over the point at which there is maximum fluctuation (or pain) and breaking of the abscess septa by digits [1]. The abscess cavity is left open or gauze-packed for a few days, with dressing changes in between during wound granulation [2]. This strategy is often done under general anesthesia. The incision is often cosmetically disappointing, owing to scar formation and interference with lactation [3].

Operative incision and drainage have historically treated almost all breast abscesses, but now antibiotics and repeated abscess aspiration, typically ultrasound driven aspiration, are the initial method. If the abscess does not react to repeated aspiration and antibiotic therapy, or if there is some other indication for incision and drainage (e.g., skin thinning or necrosis), operative drainage is now reserved.

Comparing the two procedures will help us determine the outcome of both methods in different size of breast abscess caused by different etiology.

Battle and Bialy, quoted by Uriburu in 1923, first suggested that Irrigation of the cavity after percutaneous aspiration of pus with Dakins solution could successfully treat breast abscess [4,5].

In 1946, Flory was the first to consider the feasibility of daily aspiration of minor abscesses and direct penicillin injection shortly following the medication became available at the end of World War II [6].

Ultrasonography (US) has proven to be useful in showing abscesses in patients with mastitis [7,8]. Later on, it was used to guide and achieve absolute drainage of breast abscesses, compared with sightless aspiration, as it assists in the visualisation of several abscess loculations [9]. Subsequently, the imaging-guided

percutaneous aspiration of purulent breast abscess collection was increasingly popular in the 1980s, [10] as Karstrup et al., in 1990, reported the successful percutaneous US-guided aspiration of breast abscesses [11-13]. In this era of minimally invasive methods of treatment, the aim of this study is to compare the viability and efficacy of percutaneous needle aspiration of breast abscesses under US and local anaesthesia to conventional incision and drainage.

2. OBJECTIVES

1. To study the outcome of open technique of breast abscess management.
2. To study the outcome of closed technique of breast abscess management.
3. To compare the outcome of open v/s closed technique of surgical management of breast abscess.

3. METHODOLOGY

This study will be conducted at AVBRH, Sawangi, Wardha, which is a tertiary care teaching hospital. The duration of the study will be 2 years from September 2020 to August 2022. In this study, 30 patients of Breast Abscess admitted to surgery ward AVBR Hospital will be studied and managed.

The data gathered will include age, lactation and breast symptoms (discharge, red skin, fever, tender lumps). The site of the abscesses, in relation to the breast, will be recorded. A radiologist will perform preliminary breast ultrasonography with 7–13 MHZ linear array probe, the long axis diameter of the abscesses will be checked. The aspiration procedure will be performed on the patient using a 19 G sterile needle under local anesthesia, using 2 ml of 2% plain lignocaine anaesthetic solution at the puncture side. Aspirate will be sent for culture and sensitivity. Aspiration will be followed by irrigation of the cavity thoroughly, with about 50 ml of sterile 0.9% isotonic saline solution until aspirate returned is clear. Post-procedural Ultrasonographic images will be obtained to

evaluate any residual fluid collections. A parenteral Augmentin 1.2gm will be prescribed in the clinic. Further aspiration will be done when necessary in the next 2-3 days, following ultrasonographic evaluation. Patients will be followed up one week later and as and when required by USG for any residual pus collection. Lactating patients will be encouraged to continue breast feeding.

In open method, under general anaesthesia, a radial cut will be made over the affected part for incision and drainage. But, if a circum-areolar incision allows more access to the affected region, a circum-areolar incision can be preferred since it offers a better cosmetic outcome. The incision goes into the skin and superficial fascia. After that, the abscess cavity will be entered with the long artery forceps. The jaws of the artery forceps will be opened and the tip is palpated against every aspect of the abscess. All visible loculi will be entered.

Finally, the artery forceps will be removed, and a digit will be used to disrupt any remaining septa. After that, the cavity will be lightly packed with ribbon gauze or a drain can be placed to help with dependent drainage. Basically all breast abscess cases taken in sample will be divided into two groups Group A and Group B. which patient will fall in which group will be decided randomly by chit system.

Patients in Group A will be managed by traditional Open method of Incision and Drainage for treatment of breast abscess followed by antibiotic coverage. In this method under general anesthesia incision is taken in radial directions over point of maximum fluctuation. Long artery forceps are introduced into the cavity of breast abscess and the abscess is drained by searching for loci and draining them. Then finger is introduced into the abscess to break the residual septa and drain the abscess completely. Then through wash is given to the cavity with normal saline and betadine if it seems necessary. Drain could be introduced based on the size of the cavity.

Group B on the other hand will be managed by a different minimally invasive method of Percutaneous aspiration done under Ultrasonography guidance, followed by re-aspiration if required with antibiotic coverage. In this group under local anesthesia using 2% lignocaine and under USG guidance using 19 G needle the abscess will be aspirated following which through wash will be given using normal saline till the returning fluid is clear.

Follow up of group B will be by review USG in 7 days for residual aspirate. In case there is any collection Group B will be further managed by re aspiration (upto 3 aspirations), if it is still not treated it needs to be considered as failure and we will go ahead with incision and drainage.

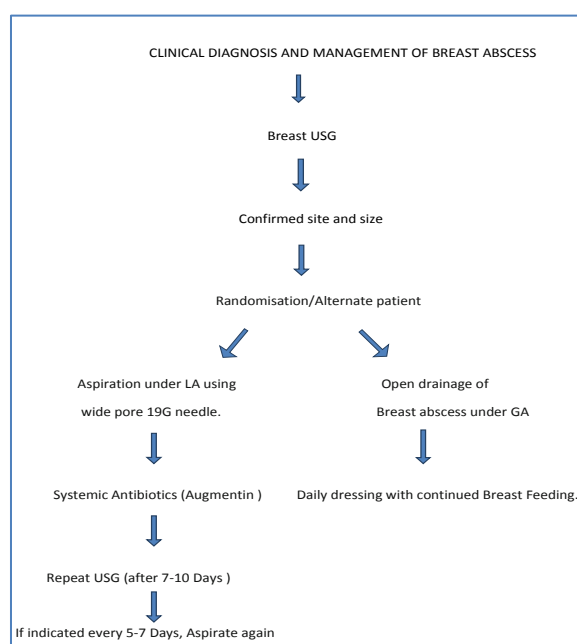


Fig.1. Study design

Study design: Prospective Observational Study

Setting: A.V.B.R.H. Sawangi (Meghe) Wardha.

Duration of study: 2 years (September 2020-August 2022)

Sample Size: 40 (20 Patients in each arm)

Inclusion Criteria –

All cases of breast abscess in female who are willing for surgical management.

Exclusion Criteria–

- Male patient
- Female with comorbidity like diabetes mellitus, chronic renal failure, chronic liver failure.
- Previously operated case.
- Diagnosed case of carcinoma of breast.
- Patient already treated with conservative cyst and antiangioma formation.

3. RESULT

We expect Percutaneous drainage to be more feasible and has better results compared to traditional method of Incision and drainage for management of breast abscess. And can become the new first line management especially for smaller breast abscess.

4. DISCUSSION

Through this study we are trying to determine that In this era of Minimally Invasive Surgery, for conditions like breast abscess in which incision and drainage is first line of management, can minimally invasive procedures like percutaneous drainage give better results. Through this study we are expecting to aid in proving that percutaneous drainage could in fact replace incision and drainage as first line management for breast abscess. We are expecting in to be more cosmetically and economically feasible. It will be helpful to determine the method to be used to treat the abscess based on the size, symptoms and etiology of breast abscess.

Lactational infections and chronic subareolar infections associated with duct ectasia are the two most common types of breast infections. Lactational infections are characterised by hyperthermia, leucocytosis, redness, and pain

and are caused by bacteria entering the duct system via the nipple. Bacteria such as Staphylococcus aureus are the most common cause of breast infections, which can manifest as cellulitis with breast parenchymal redness and edema, known as mastitis, or as abscesses. Normal breast emptying and antibacterial coverage are part of the treatment [14-16].

Drainage is needed for true abscesses. Attempt needle aspiration first; surgical incision and drainage should be reserved for abscesses that do not heal after aspiration and antibiotic care. In such instances, abscesses are typically multiloculated. Ultrasound imaging can help to characterise a breast abscess and direct treatment. Recurrent relapsing infections in the subareolar ducts of the breast, known as periductal mastitis or duct ectasia, can occur in women who are not lactating. This disorder is also related to smoking and diabetes.

This infection can be caused by both aerobic and anaerobic bacteria (including skin flora). Retraction or inversion of the nipple, lumps in the region just below the areola, and a persistent fistular tract from the subareolar ducts to the skin around the areola are all symptoms of multiple infections with associated changes that indicate inflammation and scarring [17-19].

Infection and scarring can cause palpable lumps and changes in mammography. Subareolar infections cause subareolar pain and mild erythema at first. At this stage, warm soaks and oral antibiotics may be successful treatments. Antibiotics are usually chosen to treat both aerobic and anaerobic bacteria. In addition to antibiotics, needle aspiration is needed if an abscess has formed. Abscesses that do not heal with these more conservative steps are treated with surgical incision and drainage. After the acute infection has completely healed, the entire subareolar duct complex is removed, along with injectable antibiotic coverage, to prevent recurrence.

Patients with the nipple-areola complex can require excision in rare cases. A known breast infection normally clears up quickly and completely with antibiotic therapy [20-21]. If the redness or edema persists, an inflammatory carcinoma diagnosis should be considered.

4.1 Ultrasound Breast

USG has evolved in diagnostic imaging, so much so that now with high resolution scans benign

and malignant breast disorders can also be differentiated. For breast ultrasonography, a good spatial and contrast resolution with linear-array transducer of minimum 7 MHz frequency is needed. The patient is imaged in multiple positions like supine position, oblique position on the opposite side (for the axillary and upper outer quadrants) , three-dimensional coronal imaging and elastography help to prevent biopsies in benign-appearing lesions. Ultrasonographic appearance of a breast anatomy has alternate hyper-echoic and hypo-echoic layers as follows:

- Skin appears hyperechoic
- Subcutaneous fat appears hypoechoic
- Fibroglandular parenchyma appears hyperechoic
- Retromammary fat appears hypoechoic
- Muscle- the pectoralis major appears hyperechoic

4.2 Three-dimensional Volume USG

The 3D volume USG helps in visualizing breast in coronal plane as it is not seen in routine 2D USG. Compression pattern is observed in case of benign lesions and retraction pattern in case of malignant lesions.

4.2.1 Sonomammography features of breast cysts

Breast cysts are entirely anechoic, with a thin capsule that is echogenic , posteriorly enhancing ,and showing thin edge shadowing. Intracystic echoes and septae are found in complex cysts,or thick walls, and may be seen in aggregation, complex cysts solid intracystic mass, may be malignant.

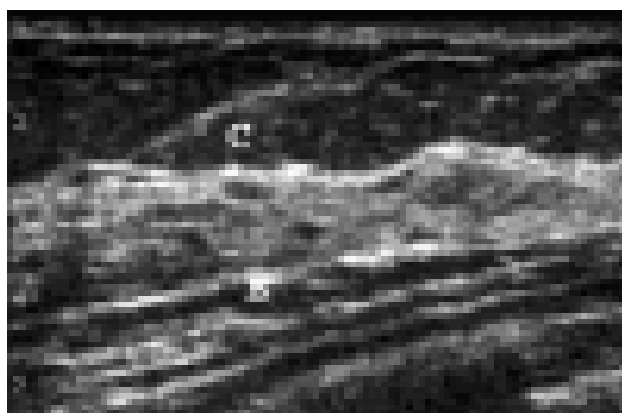


Fig. 2. Sonomammography normal breast anatomy on USG– Cooper's ligaments

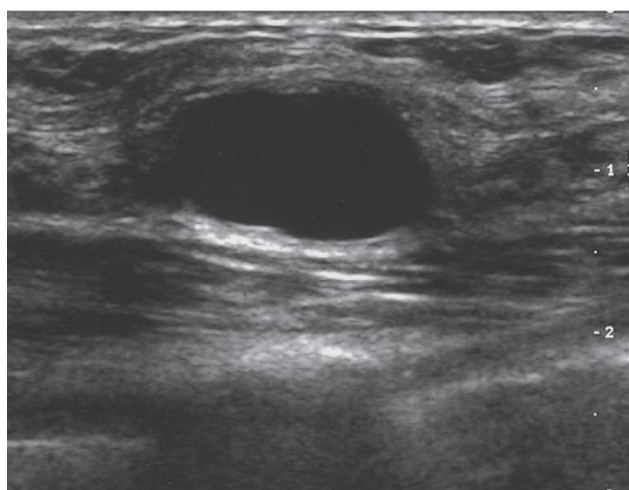


Fig. 3. Simple cyst USG image: the cyst is circular ,smooth appearing margins, Internal sound echoes are scarce, and through-transmission of sound is increased, with enhanced posterior echoes

5. CONCLUSION

In this era where minimally invasive management is being preferred and is being proven better we are hoping that the first line management of Breast Abscess will soon be percutaneous drainage under USG guidance replacing the traditional incision and drainage. This will reduce the cost of treatment, it will also reduce the hospital stay with less or no complications and will be cosmetically better.

CONSENT

As per international standard or university standard, patients' written consent will be collected and preserved by the author(s).

ETHICAL APPROVAL

The study will have the approval of the ethical committee of DMIMS, SAWANGI, WARDHA.

COMPETING INTERESTS

Authors have declared that no competing interests exist.

REFERENCE

1. Preece PE. The breast. In: Cushieri A, Giles GR, Moosa AR (eds). *Essential Surgical Practice*, Wright, Bristol, England. 1982;811–831.
2. Dixon JM. Outpatient treatment of non-lactational breast abscesses. *Br J Surg*. 1992;79:56-57.
3. Watt-Boolsen S, Rasmussen NR, Blichert-Toft M. Primary periareolar abscess in the nonlactating breast: risk of recurrence. *Am J Surg*. 1987;153:571- 573.
4. Battle RJ, Bailey GN. The treatment of acute intra- mammary abscess by incision and aspiration. *Br J Sur*. 1923;10:436–441.
5. Uriburu JV, Uriburu JL, Mosto D. Infecciones de la mama: mastitis. In: Uriburu JV (ed). *La mama, Li- breros Lopez*, Buenos Aires. 1966;581–582.
6. Florey ME, MacVine JS, Bigby MA. Treatment of breast abscesses with penicillin. *Br Med J*. 1946;2:845-848.
7. Hayes R, Michell M, Nunnerley HB. Acute inflammation of the breast--the role of breast ultra- sound in diagnosis and management. *ClinRadiol*. 1991;44:253-256.
8. Crowe DJ, Helvie MA, Wilson TE. Breast infection. Mammographic and sonographic findings with clinical correlation. *Invest Radiol*. 1995;30:582-587.
9. Hook GW, Ikeda DM. Treatment of breast abscesses with US-guided percutaneous needle drainage without indwelling catheter placement. *Radiology*. 1999;213:579-582.
10. Schwarz RJ, Shrestha R. Needle aspiration of breast abscesses. *Am J Surg*. 2001;182:117-119.
11. Karstrup S, Solvig J, Nolsoe CP, et al. Acute puerperal breast abscesses: US-guided drainage. *Radiology*. 1993;188:807–9.
12. Rajesh Domkunti, Yashwant R. Lamture, Avinash Rinait, Dilip Gode Breast carcinoma in axillary tail of spence: a rare case report, *Int J Cur Res Rev*. 2020;12(14) (Special Issue):92-95. DOI:<http://dx.doi.org/10.31782/IJCRR.2020.9295>
13. Lamture, Yashwant R, Balaji Salunke, Shahabuddin Md. "Carcinoma of Breast- A Study Profile." *Journal of Evolution of Medical and Dental Sciences-JEMDS*. 2018;7(45):4857–61. Available: <https://doi.org/10.14260/jemds/2018/1082>.
14. Yeola Pate, Meenakshi, Kushagra Singh, Darshana Tote, Azeem Javed Aalam, and Pankaj Gharde. "Metastatic Carcinoma Breast Presenting as Appendicular Abscess." *Journal of Clinical and Diagnostic Research*. 2021;15(1). Available: <https://doi.org/10.7860/JCDR/2021/44398.14412>.
15. Anand, Anupam Surya, and Raju Kamlakarrao Shinde. "To Compare the Effects of Adjuvant and Neoadjuvant Chemotherapy on Outcome of Stage III Carcinoma Breast." *Journal Of Evolution of Medical and Dental Sciences-Jemds*. 2020;9(8):496–501. Available:<https://doi.org/10.14260/jemds/2020/112>.
16. Mudey AS. Nayak M. Khapre R, Goyal. "Reaching out to Rural Women to Screen for Breast Cancer: A Step to Reduce the Burden of Breast Cancer in a Rural Area of Central India." *European Journal of Cancer*. 2016;57(2):S25.
17. Bhattacharjee, Anurag Anupkumar, Bhavaniprasad Kalagani, Harshal Ramteke, Anil Agrawal, Ravi Ponnugoti,

- Deepak gupta, Sagar Rathod, and Niveditha suresh. "A Rare Presentation of a Giant Sebaceous Cyst in the Breast-Case Report." *Medical Science*. 2020;24(105):3759–65.
18. Gaikward, Ishwari, and Pradnya Deepak Dandekar. "Knowledge, Awareness and Attitude about Breast Lump among Females An Observational Study." *International Journal of Ayurvedic Medicine*. 2020;11(3):554–58.
19. Laddha, Ankita Gajanan, Samarth Shukla, Ravindra P. Kadu, Arvind S. Bhake, Sunita Vagha, and Miheer Jagtap. "Histopathological Types of Benign Proliferative Lesions in Peritumoural Vicinity of Carcinoma Breast." *Journal of Clinical and Diagnostic Research*. 2020;14(5):EC21–26.
Available:<https://doi.org/10.7860/JCDR/2020/43291.13701>.
20. Puri, Seema, Sylvia Fernandez, Amrita Puranik, Deepika Anand, Abhay Gaidhane, Zahiruddin Quazi Syed, Archana Patel, Shahadat Uddin, and Anne Marie Thow. "Policy Content and Stakeholder Network Analysis for Infant and Young Child Feeding in India." *BMC Public Health*. 2017; 17(2).
Available: <https://doi.org/10.1186/s12889-017-4339-z>.
21. Quazi Syed, Zahiruddin, Abhay Gaidhane, Priti Kogade, Umesh Kawalkar, Nazli Khatib, and Shilpa Gaidhane. "Challenges and Patterns of Complementary Feeding for Women in Employment: A Qualitative Study from Rural India." *Current Research in Nutrition and Food Science*. 2016;4(1):48–53.
Available:<https://doi.org/10.12944/CRNFSJ.4.1.06>.

© 2021 Rathi and Yeola; This is an Open Access article distributed under the terms of the Creative Commons Attribution License (<http://creativecommons.org/licenses/by/4.0>), which permits unrestricted use, distribution, and reproduction in any medium, provided the original work is properly cited.

Peer-review history:

The peer review history for this paper can be accessed here:
<http://www.sdiarticle4.com/review-history/68570>